

A case of entecavir-associated bullous fixed drug eruption and a review of literature

Selami Aykut Temiz¹ , İlkyay Özer¹ , Arzu Ataseven¹ , Siddika Findik² 

¹Department of Dermatology, Necmettin Erbakan University School of Medicine, Konya, Turkey

²Department of Pathology, Necmettin Erbakan University School of Medicine, Konya, Turkey

Cite this article as: Temiz SA, Özer İ, Ataseven A, Findik S. A case of entecavir-associated bullous fixed drug eruption and a review of literature. *Turk J Gastroenterol* 2019; 30(3): 299-302.

ABSTRACT

Fixed drug eruption (FDE) is a type of drug reaction characterized by localized erythema, hyperpigmentation, and bullous at the same site(s), generally observed following every intake of a causative drug. Delayed-type cellular hypersensitivity (Type IVC) is considered to play a role in FDE etiology. Several antibiotics, barbiturates, oral contraceptives, nonsteroidal anti-inflammatory drugs, laxative-containing phenolphthalein, metronidazole, and quinine are known to be the primary drugs responsible for FDE. Bullous FDE, on the other hand, is a relatively rare form of FDE. Hepatitis B is a significant worldwide health problem, and entecavir is a common nucleoside (deoxyguanosine) analog used for treating hepatitis B; however, it has various side effects, such as lactic acidosis, myalgia, azotemia, hypophosphatemia, headache, diarrhea, pancreatitis, and neuropathy, and, in rare cases, cutaneous drug eruption. Our aim is to present a case of entecavir-associated bullous drug reaction, which has not been reported in the literature. Furthermore, we performed a review of literature to compile previously reported entecavir-associated drug reactions.

Keywords: Bullous fixed drug eruption, entecavir, hepatitis b, fixed drug eruption

INTRODUCTION

Fixed drug eruption (FDE) is a type of drug reaction characterized by localized erythema, hyperpigmentation, and bullous at the same site(s), generally observed following every intake of a causative drug (1). Delayed-type cellular hypersensitivity (Type IVC) is considered to play a role in FDE etiology (2). Several antibiotics, barbiturates, oral contraceptives, nonsteroidal anti-inflammatory drugs, laxatives containing phenolphthalein, metronidazole, and quinine are known to be the primary drugs responsible for FDE (1,2). Bullous FDE, on the other hand, is a relatively rare form of FDE (1,2).

Hepatitis B is a significant worldwide health problem, which is treated with entecavir, a common nucleoside (deoxyguanosine) analog with various side effects, such as lactic acidosis, myalgia, azotemia, hypophosphatemia, headache, diarrhea, pancreatitis, and neuropathy, and, in rare cases, cutaneous drug eruption (3,4,5).

Here, we presented for the first time, a case of entecavir-associated bullous drug reaction. Furthermore, we performed a review of literature to compile previously reported drug reactions related to entecavir.

CASE PRESENTATION

A 50-year-old woman was admitted because of an acute bullous lesion on the erythematous lateral surface of her right leg. Her medical background indicated no additional drug use for hepatitis B other than entecavir (0.5 mg), which she had been using for a week. In her dermatological examination, a 3 cm×2 cm bullous lesion was found on the erythematous lateral surface of her right leg (Figure 1). Her oral and genital mucosal examinations revealed no pathologies, whereas her complete blood count analysis, routine biochemical examinations, and electrolyte value results were all normal.

Skin biopsy was performed for evaluating the bullous fixed drug reaction and for the provisional diagnosis of bullous pemphigoid and differential diagnosis. Histopathological examination revealed significant papillary dermal edema and perivascular lymphocyte-rich inflammatory infiltrate accompanied by eosinophils as well as focal vacuolar degeneration of the basal layer and dissociation in the keratin layer (Figure 2). Direct immunofluorescence (DIF) test showed no immunoreactivity. The bullous lesion was aspirated, and the resulting fluid specimen was cultured. No cell growth was detected in the culture. The patient was diagnosed with bullous FDE on the basis of dermatological and

Corresponding Author: **Selami Aykut Temiz**; aykutmd42@gmail.com

Received: **January 10, 2018** Accepted: **June 4, 2018** Available online date: **November 19, 2018**

© Copyright 2019 by The Turkish Society of Gastroenterology · Available online at www.turkjgastroenterol.org

DOI: **10.5152/tjg.2018.17887**

histopathological findings, and her medical condition was associated with entecavir because she did not use any other medication. Then entecavir treatment was terminated.

Patient was administered an oral antihistaminic drug and a topical steroid ointment. The lesions gradually regressed in a few weeks during the follow-up. In the follow-up period, the lesions were resolved and remained as a post-inflammatory hyperpigmentation, with no new lesions observed. Hepatitis B treatment was continued with a combined adefovir-lamivudine regime, and the patient was advised not to use entecavir again.

DISCUSSION

Fixed drug eruption was first defined by Bourns in 1889, whereas the term "FDE" was first coined by Brocq (6). Typically the affected areas include the lips, oral mucosa, genitalia, and sacrum (6). Interestingly, our case was affected in the lateral right leg. FDE is characterized by recurrent similar lesions at the same locations, with each

recurrence exhibiting increased severity and lasting for months and even years every time the patient is exposed to a drug with specific properties (7). In cases using multiple drugs, methods, such as the oral stimulation test, skin patch test, drug lymphocyte stimulation test (DLST), intradermal tests, and skin prick test, are used to identify the responsible drug (8). The oral stimulation test is a gold standard test for FDE diagnosis; however, its use is uncommon due to its association with severe reactions (8). The skin patch test is preferred in the diagnosis of FDE, and there is a strong correlation between oral stimulation and skin patch tests (9,10). However, none of these tests was required in our case since the patient was diagnosed with entecavir-associated bullous FDE by histopathologic examination and had no history of multidrug use.

The etiopathogenesis of the responsible drug has not been fully elucidated although it is believed to be associated with basal keratinocytes acting as a hapten and causing antibody-dependent cellular cytotoxicity. Moreover, high HLA-B22 expression is known to produce genetic liability (11).

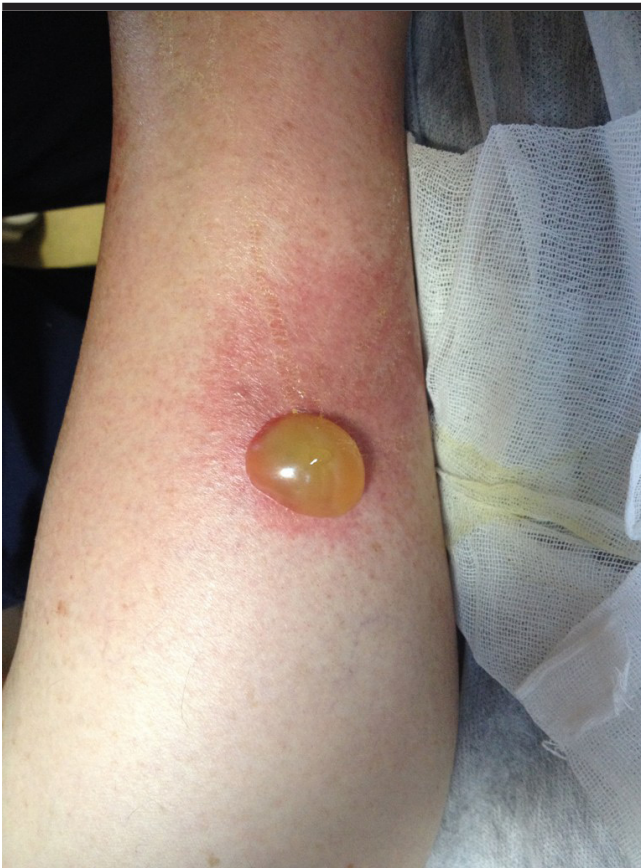

Figure 1. Bullous lesion (3 cm × 2 cm) was present on the erythematous lateral surface of the right leg

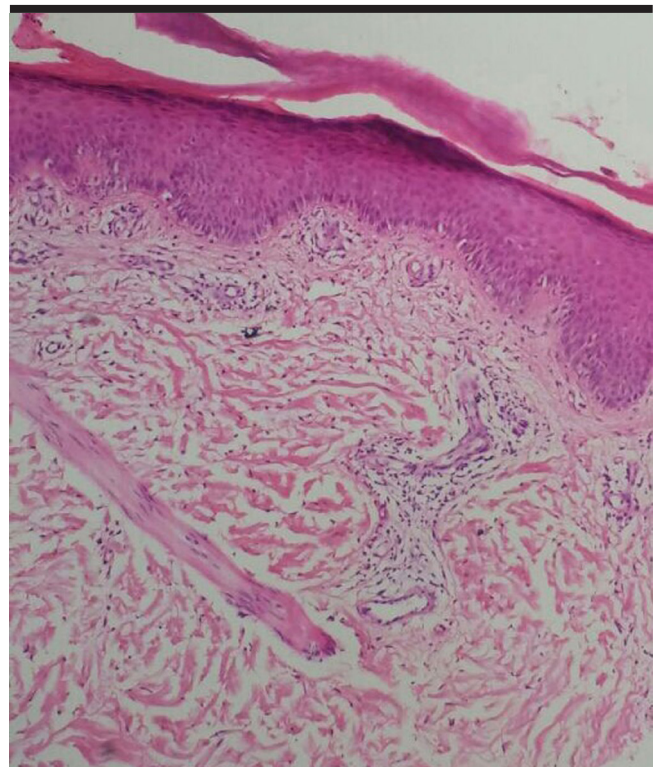


Figure 2. Histopathological examination revealed significant papillary dermal edema and perivascular lymphocyte-rich inflammatory infiltrate accompanying eosinophils, focal vacuolar degeneration of the basal layer, and dissociation in the keratin layer

Table 1. The types of cutaneous drug eruptions associated with entecavir

Author/year	Clinical sign	Age / gender	Oral Provocation DLST (drug test, lymphocyte stimulation test), Patch test, Prick test	Histopathology
1.Sugiura K et al. (12) 2009	anaphylaxis	30 / man	Prick test positive	absent
2.Yamada S et al. (5) 2011	maculopapular eruption	62 / man	DLST positive	available
3.Jimi Yoon et al. (13) 2011	granulomatous	65 / woman	DLST positive	available
4.Maiko Taura et al. (14) 2014	Erythematous plaque	65 / man	DLST positive	available
5.Jeong Tae Kim et al. (15) 2014	maculopapular eruption	45 /man	absent	available
6.Our case 2018	Bullous eruption	50 / woman	absent	available

Entecavir is a strong and highly selective DNA polymerase inhibitor, frequently used in hepatitis B treatment, with strong antiviral properties and genetic barrier (3). Its safety profile is well known, and it is the one of the most commonly used drugs in chronic hepatitis B treatment (3). There are only a limited number of studies reporting cutaneous drug reactions associated with entecavir. The types of cutaneous drug eruptions associated with entecavir, including anaphylaxis (12), granulomatous (13), erythematous plaque (14), maculopapular (5,15), and bullous (our case), are summarized in Table 1. Our case presented with bullous drug eruptions, unlike other drug eruption cases, and surprisingly, it is the first case reported until now. Although the mechanism of action of entecavir is not completely known, studies have shown that regulatory T cells and intracellular cytokines increase after treatment (16), which may be responsible for this drug reaction. Interestingly, although entecavir has been used universally, all the five cases were from East Asia. Lately, the association between the HLA alleles and drug eruptions has attracted important attention (17). The genetic origin of our case is Turkish people. According to these findings, we could speculate that genetic variation might contribute to the varying hypersensitivity rate of entecavir.

Treatment recommendations for severe cases include discontinuing the responsible drug; using highly potent topical or intralesional corticosteroids for noneroded lesions; applying topical steroid with antibiotics, bacitracin, and silver sulfadiazine; wound dressings for eroded lesions; and systemic corticosteroids (18). In our case, the lesions regressed with the application of local therapy alone, and systemic treatment was not required due to the limited localization of the lesions.

The review of the literature revealed no findings of any bullous drug reaction associated with entecavir. Our

study was thus considered the first case report on this subject in the literature. In conclusion, our case highlights the possibility of rare cutaneous drug eruptions associated with entecavir—a drug commonly used in hepatitis B treatment.

Informed Consent: Written informed consent was obtained from the patient who participated in this study.

Peer-review: Externally peer-reviewed.

Author Contributions: Concept - İ.Ö., A.A., S.A.T.; Design - A.A., İ.Ö.; Supervision - A.A., İ.Ö., S.A.T.; Resources - S.A.T., İ.Ö., S.F.; Materials - S.A.T., İ.Ö.; Data Collection and/or Processing - S.A.T., İ.Ö.; Analysis and/or Interpretation - S.A.T., İ.Ö., A.A.; Literature Search - İ.Ö.; Writing Manuscript - İ.Ö., S.A.T., A.A.; Critical Review - İ.Ö., A.A.

Conflict of Interest: The authors have no conflict of interest to declare.

Financial Disclosure: The authors declared that this study has received no financial support.

REFERENCES

1. Flowers H, Brodell R, Brents M, et al. Fixed drug eruptions: presentation, diagnosis, and management. *South Med J* 2014; 107: 724-7. [\[CrossRef\]](#)
2. Shiohara T. Fixed drug eruption: pathogenesis and diagnostic tests. *Curr Opin Allergy Clin Immunol* 2009; 9: 316-21. [\[CrossRef\]](#)
3. Ahn J, Lee HM, Lim JK, et al. Entecavir safety and effectiveness in a national cohort of treatment-naïve chronic hepatitis B patients in the US - the ENUMERATE study. *Aliment Pharmacol Ther* 2016; 43: 134-44. [\[CrossRef\]](#)
4. Marzano A, Marengo A, Marietti M, et al. Lactic acidosis during Entecavir treatment in decompensated hepatitis B virus-related cirrhosis. *Dig Liver Dis* 2011; 43: 1027-8. [\[CrossRef\]](#)
5. Yamada S, Sawada Y, Nakamura M. Maculopapular-type drug eruption caused by entecavir. *Eur J Dermatol* 2011; 21: 635-6.
6. Genest G, Thomson DM. Fixed drug eruption to quinine: a case report and review of the literature. *J Allergy Clin Immunol* 2014; 2: 469. [\[CrossRef\]](#)

7. Jain SP, Jain PA. Bullous Fixed Drug Eruption to Ciprofloxacin: A Case Report. *J Clin Diagn Res* 2013; 7: 744-45. [\[CrossRef\]](#)
8. Barbaud A, Reichert-Penetrat S, Trechot P, et al. The use of testing in the investigation of cutaneous adverse drug reactions. *Br J Dermatol* 1998; 139: 49-58. [\[CrossRef\]](#)
9. Ozkaya-Bayazit E. Topical provocation in fixed drug eruption due to metamizol and naproxen. *Clin Exp Dermatol* 2004; 29: 419-22. [\[CrossRef\]](#)
10. Ozkaya E. Fixed drug eruption: state of the art. *J Dtsch Dermatol Ges* 2008; 6: 181-8. [\[CrossRef\]](#)
11. Crowson AN, Brown TJ, Magro CM. Progress in the understanding of the pathology and pathogenesis of cutaneous drug eruptions: implications for management. *Am J Clin Dermatol* 2003; 4: 407-28. [\[CrossRef\]](#)
12. Sugiura K, Sugiura M, Takashi T, Naoki H, Itoh A. Immediate allergy, drug-induced eruption, by entecavir. *J Eur Acad Dermatol Venerol* 2009; 23: 487-9. [\[CrossRef\]](#)
13. Yoon J, Park D, Kim C. A granulomatous drug eruption induced by entecavir. *Ann Dermatol* 2013; 25: 493-5. [\[CrossRef\]](#)
14. Taura M, Asai J, Cho Z, Wada M, Katoh N. Drug eruption due to entecavir: A case report and mini-review. *Allergol Int* 2016; 65: 334-5. [\[CrossRef\]](#)
15. Kim JT, Jeong HW, Choi KH, et al. Delayed hypersensitivity reaction resulting in maculopapular-type eruption due to entecavir in the treatment of chronic hepatitis B. *World J Gastroenterol* 2014; 20: 15931. [\[CrossRef\]](#)
16. Rivkin A. Entecavir: a new nucleoside analogue for the treatment of chronic hepatitis B. *Drugs Today* 2007; 43: 201-20. [\[CrossRef\]](#)
17. Hung SI, Chung WH, Liou LB, et al. HLA-B*5801 allele as a genetic marker for severe cutaneous adverse reactions caused by allopurinol. *Proc Natl Acad Sci U S A* 2005; 102: 4134-9. [\[CrossRef\]](#)
18. Warnock JK, Morris DW. Adverse cutaneous reactions to mood stabilizers. *Am J Clin Dermatol* 2003; 4: 21-30. [\[CrossRef\]](#)