

# A Peutz-Jeghers syndrome case with iron deficiency anemia and jejuno-jejunal invagination

Demir eksikliği anemisi ve jejuno-jejunal invajinasyonla başvuran bir Peutz-Jegher vakası

Hacı Mehmet SÖKMEN<sup>1</sup>, Ali Tuzun İNCE<sup>1</sup>, Cengiz BÖLÜKBAŞ<sup>1</sup>, Güray KILIÇ<sup>2</sup>, Remzi DALAY<sup>1</sup>, Oya Övünç KURDAŞ<sup>1</sup>

Haydarpaşa Numune Education and Training Hospital, Gastroenterology Clinic<sup>1</sup>, Department of Pathology<sup>2</sup>, İstanbul

*Peutz-Jeghers syndrome is an autosomal dominantly inherited rare syndrome characterized by mucocutaneous pigmentations, with intestinal and extraintestinal polyps. It is accepted to be a precancerous syndrome. The polyps can cause anemia and intestinal obstruction and intussusception. We present a young patient admitted to our clinic with a history of recent gastrointestinal bleeding. Upper and lower gastrointestinal endoscopic examinations revealed multiple polyps located in the stomach, jejunum, rectum and terminal ileum. In addition, there were many mucocutaneous pigmentations on the lips, buccal mucosa and finger and toe nails. Jejunal polyps were found to be the cause of jejuno-jejunal invagination and iron deficiency anemia. Histopathological evaluation of the polyps revealed hamartomatous polyps of Peutz-Jeghers syndrome and this diagnosis was supported by a dermatology specialist. It is suggested that any patient presenting with ileus attacks and findings of anemia should be investigated for polyps and mucocutaneous pigmentations of the precancerous Peutz-Jeghers syndrome.*

**Key words:** Hamartomatous polyps, Jejunal invagination, mucocutaneous pigmentations, Peutz-Jeghers syndrome.

*Peutz-Jegher sendromu mukokutanöz pigmentasyonlar, intestinal ve extraintestinal poliplerle karakterize otozomal dominant kahtimli nadir bir sendromdur. Prekanseroz bir sendrom olduğu kabul edilmektedir. Polipler intestinal tıkanma, intussuspeyiyon ve anemiye de sebep olabilirler. Vaka takdimi. Genç bir hasta yakın zamanda geçirilmiş gastrointestinal kanama şikayeti ile kliniğimize müracaat etti. Üst ve alt gastrointestinal endoskopik incelemelerde mide, jejunum, rektum ve terminal ileumda multipl polipler bulundu. Aynı zamanda dudak, yanak mukozası el ve ayak tırnaklarında bir çok mukokutanöz pigmentasyonlar vardı. Hastanede yatışı sırasında ileus atakları başladı. Jejuno-jejunal invajinasyon ve demir eksikliği anemisinin sebebi olarak Jejunal polipler saptandı. Poliplerin histopatolojik olarak incelenmesinde Peutz-Jegher sendromunun hamartomatöz polipleri bulundu, dermatoloji konsültasyonunda da aynı tanı desteklendi. İleus atakları ve anemi bulgularıyla müracaat eden her hastada prekanseröz olan Peutz-Jegher sendromunun polipleri ve mukokutanöz pigmentasyonları aranmalıdır.*

**Anahtar kelimeler:** Hamartomatöz polipler, Jejunal invajinasyon, mukokutanöz pigmentasyonlar, Peutz-Jegher sendromu.

## INTRODUCTION

Peutz Jegher's syndrome (PJS) is rare syndrome that was first described in 1921. It is characterized by mucocutaneous pigmentation and hamartomatous polyps and is accepted to be a precancerous syndrome. Afro-Caribbean people are rarely affected (1,2). Inheritance is autosomal dominantly with a pleotrophic gene (3-7). Inactivation of this gene by germline mutations or loss of normal allele can result in hamartomatous polyps. The incidence of cancer in first degree relatives of these patients has been found to be higher than the normal population. The skin (mucocu-

taneous pigmentations), intestinal system (stomach, small and large intestine) and extraintestinal system (gallbladder and biliary, pancreas, respiratory, urogenital and neurologic systems) may all be affected in this syndrome. In particular, intestinal polyps can cause iron deficiency anemia due to gastrointestinal (GI) bleeding and can result in intestinal intussusception and obstruction because of their huge size. This may result in the need for repeated surgical interventions, although the diagnosis and therapy of intestinal polyps with endoscopy now possible.

## CASE REPORT

A 17-year old female was admitted to our clinic with a three month-history of fatigue, abdominal pain, distention and nausea. She described a blunt pain in the periumbilical area and abdominal distention after meals, causing her to avoid food intake. She had lost eight kg in weight during the previous three months and had been admitted to hospital five days previously with upper GI bleeding, requiring the transfusion of four units of blood. The patient was then transferred to our clinic for detailed evaluation of abdominal distension and difficulty in passing gas and faeces.

Her past history was uneventful apart from menstrual irregularity for the previous four years. In physical examination, blood pressure: 110/80 mmHg, pulse: 88/min, temperature: 36.5 C<sup>s</sup>, her general condition was good and she was conscious. There were multiple brown-violet colored, small flat pigmentations on her upper and lower lips, buccal mucosa and brown spotty pigmentations on the lip mucosa. The same pigmentations were seen on the finger and toe nails. The conjunctivae were pale. There was epigastric and umbilical sensitivity on palpation. During rectal examination, a polyp was palpated at the anal canal. Respiratory, cardiovascular, genitourinary and neurologic system examinations were within normal limits.

In laboratory findings, the hematocrit level was 33%, serum iron level was 17 mcg/dl, iron binding capacity level was 358 mcg/dl. Hypochromic microerythrocytes were seen in blood smear. The serum ferritin level was within normal levels (200 ng/ml). Stool guaiac test was positive. Routine biochemistry tests, urinalysis, thyroid and sex hormone levels and tumor markers were within normal limits.

Pelvic ultrasonography and abdominal tomography was normal. In esophagogastroduodenoscopy, there were three polyps in the corpus of the stomach (polypectomy had been performed on one of them), antral gastritis and duodenitis. Colonoscopy, showed three-piece pedunculated polyps (1-2 cm in size) at the fifth cm. of the rectum (polypectomy had been performed in all). The coarse granular appearance in the terminal ileum was evaluated as a nodular hyperplasia.

Enteroclysis was performed and during the procedure, a temporary jejunal invagination was noticed and it resolved spontaneously. Jejunal

polyps were found to be the cause of invagination. There were no other polyps in the small intestine. In dermatologic evaluation, there were brown-black macular pigmented lesions on the upper and lower lips, vermilion border and internal surfaces, buccal mucosa, peribuccal region, around the eyelids and on the of the ventral sides of the hands and feet.

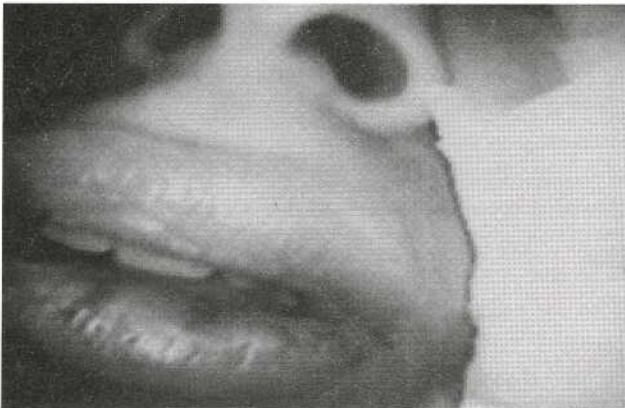**Clinical progress:** The patient had been admitted for evaluation of abdominal pain, distention and gastrointestinal hemorrhage. Although, there was an iron deficiency anemia in this patient, her hematocrit level was found to be higher (33%) than might be expected because she had received four units of blood prior to admission to our clinic. Gastroscopic examination revealed three polyps at the corpus region of stomach and polypectomy on one of them. Three polyps were also seen in the rectum and all of them were removed during colonoscopy. The presence of brown pigmentations on the cheek and nails and multiple gastrointestinal polyps in a young patient alerted us to a possible diagnosis of Peutz-Jeghers syndrome. On the fifth day of admission, blunt abdominal pain and vomiting began and there was difficulty in passing gas and stool. A plain abdominal film revealed air-fluid levels in the mid-abdomen. A filling defect was noticed during enteroclysis procedure, which was caused by jejunal polyps and a temporary jejunal invagination was also noticed, which resolved spontaneously. Polypectomy was planned by enteroscopic procedure but this failed due to the huge size of these jejunal polyps and to technical difficulties. Surgery was therefore performed, with a ten-centimeter jejunum segment being resected. There were no postoperative complications and no ileus attacks during a three-month follow-up period. Histopathologic examination of the polyps revealed hamartomatous polyps. A dermatology consultation confirmed the diagnosis of Peutz-Jeghers syndrome. The cause of ileus attacks was jejunal invagination caused by jejunal polyps, with iron deficiency anemia having been caused by occult or overt blood loss from the polyps into the gastrointestinal lumen.

## DISCUSSION

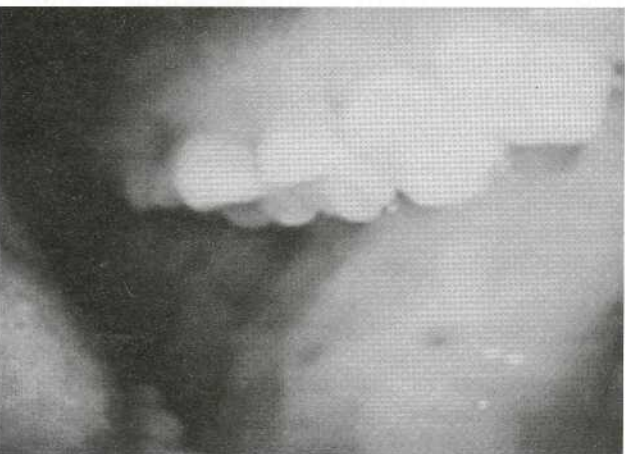Peutz Jeghers syndrome is a rare familial disease first described by Peutz in 1921 and Jeghers 1949. To date, it has not been possible to determine the gene, although germline mutations have been detected on the LKB1 (STK11) gene on chromo-

some 19p13.3 (3,5,6,8-12). These are nonsense, frameshift and missense mutations and all inactivate LKB1 gene which encodes a threonine kinase and behaves like a tumor suppressor gene (13). Inactivation of this gene by germline mutations or loss of normal allele can result in hamartomatous polyps. Apart from the role of beta-catenin, adenomatous polyposis coli, K-ras and p-53 gene mutations have also been investigated (8).

The mucocutaneous pigmentations (4,7,14-16) caused by melanin aggregation can be seen in 93% of patients even in infancy (4). They are generally located around the mouth (figure 1), nose, cheek mucosa (figure 2), hand, foot and sometimes perianal and genital areas.



**Figure 1.** The characteristic mucocutaneous pigmentations of PJS located around the mouth.

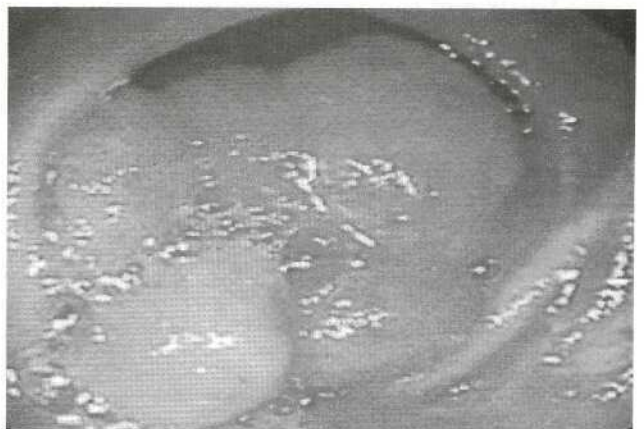


**Figure 2.** The characteristic mucocutaneous pigmentations of PJS located around buccal mucosa.

The polyps of PJS are generally not real neoplasms but sometimes their huge size can cause small intestinal obstruction and intussusception and ultrasonography is therefore useful for follow-up of these patients (14,17-19). Jejunal polyps can reach up to 100 in number and result in multiple operations which can cause short gut syndrome (6). The mean age for surgery is generally about 21.4 years (4) and our patient was 17 years old. It has been recommended that pre- and intraoperative endoscopic examination be performed to prevent multiple operations and cancer development (19-21).

Intestinal polyps also can cause iron deficiency anemia by producing overt or occult bleeding into the gastrointestinal lumen, as seen in our patient (16,22). Hamartomatous polyp in the rectum and jejunum (Figure 3), hyperplastic polyp in the corpus of the stomach and nodular hyperplasia in the terminal ileum were detected by histopathologic evaluation in our patient. Extraintestinal polyps are rarely found (15). They may be located in the respiratory system, urogenital system and gallbladder. There is controversy regarding the benefit of prophylactic polypectomy. Malignant transformation of small polyps is very rare but regular follow-up should occur. In our patient, no extraintestinal polyps were found and an ear nose and throat consultation with sinus graphy revealed no respiratory polyps and there were no gallbladder or urogenital polyps on ultrasonographic examination.

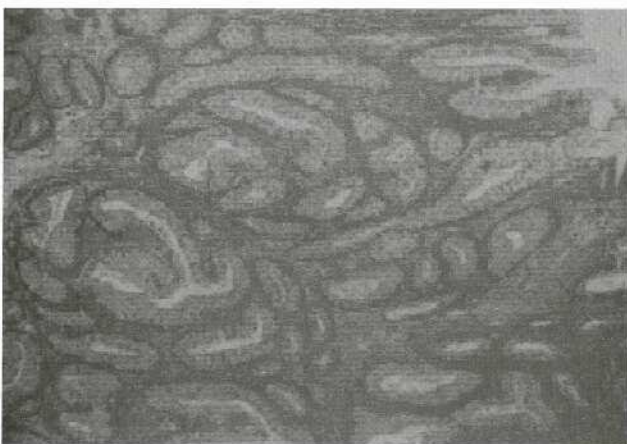
Polyps in PJS are hamartomatous polyps with smooth muscle branching through to the tip of the polyp. Villous projection's and tubular structures



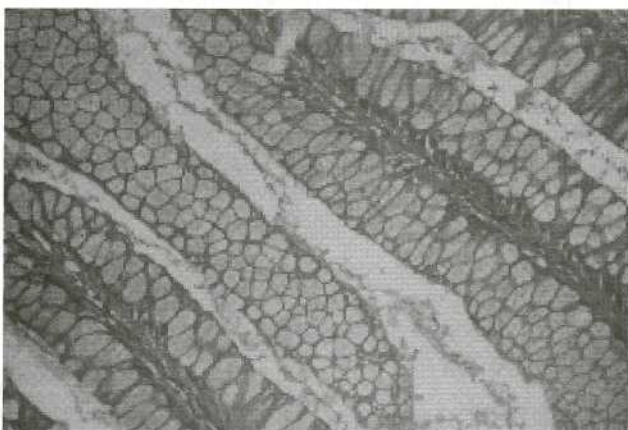
**Figure 3.** The giant jejunal hamartomatous polyp, which caused intussusception.

of our patients polyp are shown in Figure 4. Branching smooth muscle bands were also seen, surrounded by glandular intestinal epithelium. In Figure 5, high columnar cells with wide and clear stoplasm and muscular fibers appear among the columnar cells; their small nuclei are located basally.

Peutz Jeghers Syndrome has been accepted as a precancerous syndrome, with cancers being seen in 50% of patients (23,24) and the median age of cancer diagnosis being about fifty years. Small intestine, stomach, colon and cervical cancers have been detected at an increasing rate in the first degree relatives of patients, with small intestinal cancer sometimes seen in younger patients (4). Intestinal polyposis is reported to have been found in four asymptomatic family



**Figure 4.** Villous projections, tubular structures and branching smooth muscle bands surrounded by glandular intestinal epithelium of the polyp are seen.



**Figure 5.** (H-EX200) The area with high columnar cells which have wide, clear stoplasm and small nucleus located at basale, among which muscle fibers are also seen.

members of a seven-year old girl (29). Is thus recommended that every first degree relative of the PJS patient should be screened for polyps. During histopathologic evaluation, cancer can be mistakenly diagnosed if dysplastic epithelium is located in the submucosa and muscularis mucosa (25). It is thought that intestinal cancers seen in PJS patients may originate in the polyp's epithelium, and it is therefore essential that every polyp is excised and examined. Difficulty in reaching small intestinal polyps with an endoscope is a problem in PJS polyp surveillance programs. Although it has been found that there is a high cancer risk in PJS patients according to John Hopkin's hospital polyposis registry (7), no cancer was found in our patient's polyps.

Breast cancer may be seen in younger patients and may be located in both breasts, but breast examination was normal in our patient. Cancer may also be seen in the pancreas (adenocarcinoma and cystadenocarcinoma), gallbladder and biliary tree (27,28) and there is an increased association with carcinoid syndrome and malignant melanoma (26). Abdominal tomography, ultrasonographic evaluation and alphafetoprotein and carcinoembriogenic antigen levels were normal in our patient. Ovarian cysts and tumors are found in 5-12% of patients, with cervical adenocarcinomas and ovarian tumors being the two most common and sertoli cell tumor being the most rare (7). Ovarian tumors are generally sporadic and benign, although one malignant case has been reported (30). Testicular sex cord tumors can cause earlier bone maturation and prepubertal gynecomastia in 10% of patients (31). All patients with gynecomastia should therefore be screened for testicular tumor. Testicular ultrasonography and biopsy are necessary for diagnosis. A sertoli cell tumor has been reported in a four and a half year old girl who was admitted with isosexual precocious puberty. Bilateral mucinous ovarian tumors are also common (32). In our patient, hormone levels were found to be within normal limits and there was no evidence of a sex cord tumor. The patient was advised to attend follow-up every two years.

Tuberos sclerosis is a frequent neurologic problem in PJS patients and it is characterized by hamartomatous polyp, mental retardation, epilepsy and adenoma cebaceum. This was not present in our patient and her neurological examination was normal.

## CONCLUSION

In conclusion, it is recommended that any patient presenting with ileus attacks and anemia should be investigated for polyps and the mucocutaneous

pigmentation of Peutz-Jeghers syndrome. In addition, patients in whom this syndrome is diagnosed should be evaluated for cancer and family screening should be considered.

## REFERENCES

- 1- Anyanwu SN. Sporadic Peutz-Jeghers syndrome in a Nigerian. *Cent Afr J Med* 1999; 45: 182-4.
- 2- Igun GO, Ameh YY, Awani KU. Peutz-Jeghers syndrome: case report. *East Afr Med J* 1999; 76: 284-6.
- 3- Miyaki M. Peutz-Jeghers syndrome. *Nippon Rinsho* 2000; 58: 1400-4.
- 4- Choi HS, Park YJ, Youk EG, et al. Clinical characteristics of Peutz-Jeghers syndrome in Korean polyposis patients. *Int J Colorectal Dis* 2000; 15:35-8.
- 5- Westerman AM, Entius MM, de Baar E, et al. Peutz-Jeghers syndrome: 78-year follow-up of the original family. *Lancet* 1999; 353: 1211-5.
- 6- Choi HS, Park YJ, Park JG. Peutz-Jeghers syndrome: a new understanding. *J Korean Med Sci*, 1999; 14: 2-7.
- 7- Itzkowitz SH, Kim YS. Colonic polyps and polyposis syndromes. Feldman M, Scharschmidt BF, Sleisenger MH Sleisenger & Fordtran's *Gastrointestinal and Liver Disease*. 6th Edition. Philadelphia, WB Saunders, 1998: 113.
- 8- Miyaki M, Iijima T, Hosono K, et al. Somatic mutations of LKB1 and beta-catenin genes in gastro-intestinal polyps from patients with Peutz-Jeghers syndrome. *Cancer Res* 2000; 60: 6311-3.
- 9- Van der Werf G, Menko FH, Gille JJ, et al. Patient with Peutz-Jeghers syndrome and liver metastases from an unknown primary tumor. *Ned Tijdschr Geneesk* 2000; 144: 667-70.
- 10- Dong SM, Kim KM, Kim SY, et al. Frequent somatic mutations in serine/threonine kinase 11/Peutz-Jeghers syndrome gene in left-sided colon cancer. *Cancer Res* 1998; 58: 3787-90.
- 11- Nakagawa H, Koyama K, Miyoshi Y, et al. Nine novel germline mutations of STK11 in ten families with Peutz-Jeghers syndrome. *Hum Genet* 1998; 103: 168-72.
- 12- Nakagawa H, Koyama K, Tanaka T, et al. Localization of the gene responsible for Peutz-Jeghers syndrome within a 6-cM region of chromosome 19p13.3. *Hum Genet* 1998; 102: 203-6.
- 13- Boardman L A, Couch FJ, Burgart LJ, et al. Genetic heterogeneity in Peutz-Jeghers syndrome. *Hum Mutat* 2000; 16: 23-30.
- 14- Taira K, Matsubara H, Isa T, et al. Combined endoscopic and surgical treatment for multiple polyps of the small intestine in Peutz-Jeghers syndrome: a case report. *Surg Laparosc Endosc Percutan Tech* 2000; 10: 409-11.
- 15- Vogel T, Schumacher V, Saleh A, et al. Extraintestinal polyps in Peutz-Jeghers syndrome: presentation of four cases and review of the literature. *Deutsche Peutz-Jeghers-Studiengruppe*. *Int J Colorectal Dis* 2000; 15: 118-23.
- 16- Mc Garrity TJ, Kulin HE, Zaino RJ. Peutz-Jeghers syndrome. *Am J Gastroenterol* 2000; 95: 596-604.
- 17- Kilgus M, Rothlin MA, Largiader F. Intussusception of the small bowel due to Peutz-Jeghers syndrome: a case report. *Hepatogastroenterol* 1998; 45: 454-5.
- 18- Naganuma H, Ishida H, Konno K, et al. Intussusception in Peutz-Jeghers syndrome: sonographic findings. *Abdom. Imaging* 1999; 24: 333-5.
- 19- Pennazio M, Rossini FP. Small bowel polyps in Peutz-Jeghers syndrome: management by combined push enteroscopy and intraoperative enteroscopy. *Gastrointest Endosc* 2000; 51: 304-8.
- 20- Ishida H, Murata N, Tada M, et al. A new simple technique for performing intraoperative endoscopic resection of small-bowel polyps in patients with Peutz-Jeghers syndrome. *Surg Today* 1999; 29: 581-3.
- 21- Yağmurdu MC, Daphan C, Ozdemir A, et al. The usefulness of intra-operative endoscopy in Peutz-Jeghers syndrome: a case report. *Hepatogastroenterol* 1998; 45: 2175-8.
- 22- Hirao S, Sho M, Kanehiro H, et al. Pancreatic adenocarcinoma in a patient with Peutz-Jeghers syndrome: report of a case and literature review. *Hepatogastroenterol* 2000; 47: 1159-61.
- 23- Giardiello FM, Brensinger JD, Tersmette AC, et al. Very high risk of cancer in familial Peutz-Jeghers syndrome. *Gastroenterology* 2000; 119: 1447-53.
- 24- Boardman LA, Thibodeau SN, Schaid DJ, et al. Increased risk for cancer in patients with the Peutz-Jeghers syndrome. *Ann Intern Med* 1998; 128: 896-9.
- 25- Petersen VC, Sheehan AL, Bryan RL, et al. Misplacement of dysplastic epithelium in Peutz-Jeghers Polyps: the ultimate diagnostic pitfall? *Am J Surg Pathol* 2000; 24: 34-9.
- 26- Wada K, Asoh T, Imamura T, et al. Rectal carcinoid tumor associated with the Peutz-Jeghers syndrome. *J Gastroenterol* 1998; 33: 743-6.
- 27- Yoshikawa A, Kuramoto S, Mimura T, et al. Peutz-Jeghers syndrome manifesting complete intussusception of the appendix and associated with a focal cancer of the duodenum and a cystadenocarcinoma of the pancreas: report of a case. *Dis Colon Rectum* 1998; 41:517-21.
- 28- Baumgartner G, Neuweiler J, Herzog D, et al. Peutz-Jeghers syndrome: is family screening needed? *Pediatr Surg Int* 2000; 16: 437-9.
- 29- Lele SM, Sawh RN, Zaharopoulos P, et al. Malignant ovarian sex cord tumor with annular tubules in a patient with Peutz-Jeghers syndrome: a case report. *Mod Pathol* 2000; 13: 466-70.
- 30- Hertl MC, Wiebel J, Schafer H, et al. Feminizing Sertoli cell tumors associated with Peutz-Jeghers syndrome: an increasingly recognized cause of prepubertal gynecomastia *Plast Reconstr Surg* 1998; 102: 1151-7.
- 31- Wacrenier A, Boman F, Farine MO, et al. Ovarian mucinous tumor of gastric and intestinal type associated with Peutz-Jeghers syndrome: in situ hybridization study of apomucin gene transcripts. *Ann Pathol* 1998; 18: 497-501.