



Changes in pressure waves after endoscopic intervention in patients with achalasia: A focus on peristaltic recovery of the esophageal body

ESOPHAGUS

Se Kyung Park, Su Jin Hong, Jae Pil Han, Hyeon Jeong Goong, Hyun Soo Kim, Yu Sik Myung, Shin Hee Kim, Hee Jae Jung, Tae Hee Lee, Joon Seong Lee, Moon Sung Lee

Department of Internal Medicine, Digestive Disease Center and Research Institute, Soonchunhyang University College of Medicine, Bucheon, Korea

ABSTRACT

Background/Aims: We conducted the present study to investigate the recovery of peristalsis of the esophageal body and evaluate the pressure changes observed on manometry before and after endoscopic intervention.

Materials and Methods: Forty-five patients were diagnosed with achalasia, and 36 received endoscopic or surgical treatment. We collected the data of 24 patients who underwent manometry before and after treatment (pneumatic balloon dilatation, n=7; botulinum toxin injection, n=10; peroral endoscopic myotomy, n=7).

Results: The lower esophageal sphincter (LES) resting pressure and nadir LES relaxation pressure decreased regardless of the achalasia subtype or type of endoscopic intervention following treatment ($p<0.05$). Among patients with a nadir LES relaxation pressure of <4 mmHg, 42.9% (6/14) exhibited partial esophageal peristaltic wave recovery. However, no patients with a nadir LES relaxation pressure of >4 mmHg exhibited peristaltic wave recovery ($p=0.024$). Of the six patients with peristaltic wave recovery, two had type I achalasia (15.4%), three had type II (33.3%), and one had type III (100.0%). The Eckardt score, symptom duration, and type of intervention were not associated with the recovery of peristaltic waves.

Conclusion: Our results suggest that normalization of the nadir LES relaxation pressure can be a predictive factor for the recovery of esophageal peristalsis.

Keywords: Achalasia, endoscopic intervention, peristalsis

INTRODUCTION

Achalasia is a motility disorder characterized by impaired lower esophageal sphincter (LES) relaxation and abnormal peristalsis of the esophageal body. It is caused by the loss of ganglion cells in the esophageal myenteric plexus, which regulates relaxation of the LES and esophageal peristalsis (1). Although they vary slightly, the annual incidence rates of achalasia are approximately 1 per 100,000 individuals, depending on the geographical region (2). Although the exact etiology of achalasia is unknown, autoimmune responses and genetic susceptibility to viral infections such as herpes and measles are thought to be individual patient-associated factors (3).

Radiologically, achalasia is characterized by the expansion of the esophagus, a "bird beak" appearance, and stagnation of barium. Food material can be observed

inside the esophagus by endoscopy (4). The main symptoms are difficulty in swallowing, regurgitation, and chest pain. Achalasia is diagnosed by esophageal manometry examination, such as conventional manometry or high-resolution manometry (HRM). Endoscopy is also helpful in differentiating secondary achalasia.

The current goal of palliative treatment is to lower the LES pressure for symptom control. Primary treatment is preferred to pneumatic balloon dilatation (PBD) and Heller myotomy. Botulinum toxin injection (BTI) is temporarily effective. Palliative treatment with peroral endoscopic myotomy (POEM) was recently introduced to treat achalasia. In a study of patients who underwent POEM, post-treatment outcomes, including symptoms and LES relaxation pressure, were improved after a mean of 15 months follow-up. Among 41 patients, 47%

Address for Correspondence: Su Jin Hong E-mail: sjhong@schmc.ac.kr

Received: August 04, 2015

Accepted: November 04, 2015

Available Online Date: December 17, 2015

© Copyright 2016 by The Turkish Society of Gastroenterology • Available online at www.turkjgastroenterol.org • DOI: 10.5152/tjg.2015.150271

of those with completely absent preoperative peristalsis exhibited partial recovery of peristalsis (5).

Partial recovery of peristalsis has been reported in some patients with achalasia after endoscopic intervention, including POEM; however, the exact mechanism of this phenomenon remains unclear (5-9). We conducted the present study to investigate the recovery of peristalsis of the esophageal body and to evaluate the pressure changes on manometry before and after endoscopic intervention in patients with achalasia.

MATERIALS AND METHODS

Patients

Among 45 patients diagnosed with primary achalasia by diagnostic tests, including esophageal manometry, endoscopy, and esophagography, between March 2003 and April 2014 in a single tertiary referral center, 37 patients underwent treatment, namely, endoscopic intervention (n=33), surgical myotomy (n=3), and medication, including calcium channel blockers (n=1). We included 24 patients [11 males; median age (range) 55.5 (13–88) years] without a history of endoscopic or surgical treatment in this study. The symptoms of achalasia were quantified using the Eckardt score (Table 1) (10). The type of achalasia was determined according to the Chicago classification, which is based on the amplitude and pattern of pressure waves in the esophageal body (4). Before the procedure, written informed consent was obtained from each patient. This study was approved by the Ethics Committee and Institutional Review Board of our institution (SCHBC 2014-08-022-002).

Endoscopic intervention

Endoscopic intervention included PBD, BTI, and POEM. Two experienced doctors performed the endoscopic interventions.

Pneumatic balloon dilatation was performed in a fluoroscopy room. A stepwise approach started with a 30-mm balloon (Rigiflex II; Boston Scientific, MA, USA) for the first session. The balloon was inflated gradually using a syringe connected to a manometer. The balloon was kept inflated for 30 s. A second dilatation was performed for another 60 s. If effective dilatation was achieved, the waist of the balloon was no longer evident. Dilatation with balloons of 3.5 and 4.0 cm diameter was used in the final procedure in patients that underwent PBD.

Botulinum toxin (Allergan Inc.; Irvine, CA, USA) in 1 mL aliquots of 25 units (100 units total) was injected in each of four quadrants approximately 1 cm above the z-line or the endoscopically visible LES rosette.

Peroral endoscopic myotomy was performed by Inoue's technique (11). Selective myotomy of circular bundles started 2 cm distal to the mucosal entry site and was continued at least 3 cm past the esophagogastric junction (EGJ) under general anesthesia with endotracheal intubation.

Table 1. Clinical scoring system for achalasia: Eckardt score (10)

Score	Symptom	Weight loss (kg)	Dysphagia	Retrosternal pain	Regurgitation
0	None	None	None	None	None
1	<5	Occasional	Occasional	Occasional	Occasional
2	5–10	Daily	Daily	Daily	Daily
3	>10	Each meal	Each meal	Each meal	Each meal

The final score is the sum of the four component scores (range 0–12).

Esophageal manometry

Patients were analyzed after an overnight fast. Medications that may interfere with esophageal motor function (i.e., metoclopramide, nitrates, and calcium channel-blocking agents) were discontinued at least 48 hours before the study. Esophageal manometry was performed using conventional esophageal manometry or HRM.

Conventional manometry was performed using an eight-lumen manometry catheter (4.5 mm outer diameter) and a water-infusion manometry system with a low-compliance pneumohydraulic capillary infusion pump. The catheter (Medtronic; Minneapolis, MN, USA) was connected to a polygraph, and the data were displayed on a computer monitor (Compaq; Houston, TX, USA) using specific software (Polygram Net; Medtronic). LES pressure was measured from the gastric baseline to the end expiration pressure at the highest resting pressure using the station pull-through technique. Esophageal body functions, including wave amplitude, duration, and velocity, were measured 3, 8, 13, and 18 cm above the upper border of the LES. The HRM unit used in this study was a solid-state manometric assembly (4.2 mm outer diameter) with 36 circumferential pressure sensors spaced at 1-cm intervals. Manometric data were analyzed using ManoView analysis software (Sierra Scientific Instruments Inc.; Los Angeles, CA, USA). The pressure transducers were calibrated at 0 and 300 mmHg using externally applied pressure before recording. Patients underwent transnasal placement of the manometry assembly, and the assembly was positioned to record from the hypopharynx to the stomach.

All studies were performed with the patient in the supine position. The manometric protocol included a 5-min period for measurement of the basal sphincter pressure and 10 water swallows of 5 mL each.

The achalasia subtype was determined according to the Chicago classification based on the isobaric waves of the esophageal body, even when patients underwent conventional manometry. Type I is characterized by the absence of contractile activity and pressurization, type II by panesophageal pressurization, and type III by premature contraction (12).

In conventional manometry, the normal basal LES pressure, expiratory resting pressure, and nadir LES relaxation pressure are 10–45 mmHg (mid-respiratory pressure measured by the station pull-through technique), 15.2 ± 10.7 mmHg, and ≤ 8 mmHg, respectively. Incomplete LES relaxation is defined as uncoordinated swallowing and a difference of >8 mmHg between the gastric baseline and the lowest LES pressure (13,14).

Esophagogastric junction relaxation pressure was measured using the integrated relaxation pressure (IRP) in HRM. The IRP quantifies EGJ relaxation in terms of completeness and persistence and reports the mean EGJ pressure during the 4 s of most complete relaxation within a 10-s window beginning at relaxation of the upper esophageal sphincter (UES). The upper limit of the reference range for the IRP with this instrumentation is <15 mmHg (14). The mean EGJ pressure was calculated via the recorded pressure data in patients who underwent HRM.

On conventional manometry, peristaltic wave recovery was considered to have occurred when distal progression of at least two distal tips was observed from peak to peak of the contractions (6). On HRM, peristaltic wave recovery was defined as the presence of ≥ 3 cm integrity of the 20 mmHg isobaric contour distal to the proximal pressure trough (12).

Statistical analysis

Statistical analysis was performed using the Statistical Package for the Social Sciences (SPSS) version 14.0 (SPSS Inc.; Chicago, IL, USA). Student's t-test was used to evaluate changes in the characteristics associated with the partial recovery of peristalsis. Pre- and post-endoscopic intervention data were compared using Fisher's exact test, the Wilcoxon signed-rank test, and the Mann-Whitney test, as indicated. A p-value of <0.05 was considered statistically significant.

RESULTS

A total of 24 patients underwent conventional manometry studies before and after endoscopic intervention. These patients comprised 11 men (46%) and 13 women (54%). Their median age was 55.5 years, and their median duration of disease was 12 months (range 1–360 months). Their median Eckardt score was 5 (range 2–10). According to the Chicago classification, 14 patients had type I achalasia, nine had type II, and one had type III. Seven patients underwent PBD, ten underwent BTI, and seven underwent POEM (Table 2).

There were no significant differences in sex, age, Eckardt score, duration of disease, or type of endoscopic intervention between the partial peristaltic recovery group and peristaltic non-recovery group ($p>0.05$). Peristaltic wave recovery was observed in 2 (14.3%) of the 14 patients with type I achalasia, in 3 (33.3%) of the 9 patients with type II, and in the 1 (100.0%) patient with type III (Table 3). After treatment, the Eckardt score decreased from 5 (range 2–10) to 2 (range 0–6).

Table 2. Baseline characteristics of enrolled patients

Sex (male/female), n	11/13
Median age, years (range)	55.5 (13–88)
Median disease duration, months (range)	12 (1–360)
Median Eckardt score (range)	5 (2–10)
Achalasia subtype (n, %)	
Type I	14 (58)
Type II	9 (38)
Type III	1 (4)
Endoscopic intervention (n, %)	
PBD	7 (29)
BTI	10 (42)
POEM	7 (29)

BTI: botulinum toxin injection; PBD: pneumatic balloon dilatation; POEM: peroral endoscopic myotomy

Table 3. Comparison between patients with peristaltic recovery and those without recovery after endoscopic intervention

	Recovery group (n=6)	Non-recovery group (n=18)	p
Sex (M/F), n	2/4	10/8	0.649 ^a
Age (years) ^c	60.5	55	0.973 ^b
Eckardt score ^c	4	5	0.812 ^b
Disease duration (months) ^c	24	12	0.431 ^b
Endoscopic intervention (n, %)			0.350 ^a
PBD	3 (42.9)	4 (57.1)	
BTI	1 (10)	9 (90)	
POEM	2 (28.6)	5 (61.3)	
Achalasia subtype (n, %)			0.122 ^a
Type I	2 (14.3)	12 (85.7)	
Type II	3 (33.3)	6 (66.7)	
Type III	1 (100)	0 (0)	

The p-value was calculated using ^aFisher's exact test and ^bthe Mann-Whitney test. Quantitative values are presented as 'medians.

BTI: botulinum toxin injection; PBD: pneumatic balloon dilatation; POEM: peroral endoscopic myotomy

A second esophageal manometry examination was performed at a median of 9.5 months after endoscopic treatment (range 1–43 months). Manometry showed that the expiratory resting pressure decreased from 21.5 to 14.9 mmHg after endoscopic intervention. The LES resting pressure decreased from 31.9 to 25.3 mmHg, and the nadir LES relaxation pressure decreased from 13.6 to 4.5 mmHg. These manometric changes were statistically significant, regardless of the achalasia subtype or type of endoscopic intervention ($p<0.05$) (Table 4). After endoscopic intervention, the expiratory resting pressure decreased to <15 mmHg in 16 patients, the mean resting pressure decreased to

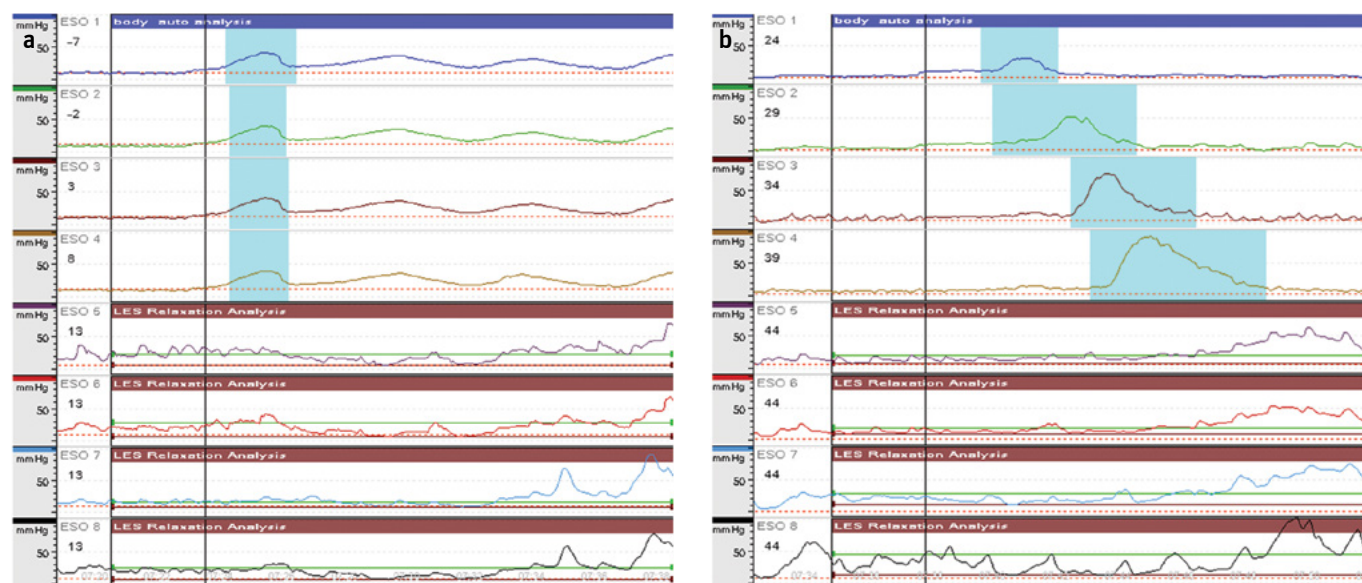


Figure 1. a, b. Manometric data before (a) and after (b) BTI in a 62-year-old male patient. The expiratory resting pressure, mean resting pressure, and nadir LES relaxation pressure were 10.4, 22.8, and 4.1 mmHg, respectively. Premature contraction of the esophageal body was observed (a), and the expiratory resting pressure, mean resting pressure, and nadir LES relaxation pressure were 5.2, 21.4, and -1.5 mmHg, respectively (b). Recovery of peristalsis was observed. BTI: botulinum toxin injection; LES: lower esophageal sphincter

Table 4. Lower esophageal sphincter pressure pre- and post-treatment

Mean pressure (mmHg)	Pre-treatment	Post-treatment	Reduction ratio (%)	p ^a
Expiratory resting	21.5	14.9	30.1	0.003
Mean resting	31.9	25.3	20.7	0.016
Nadir relaxation	13.6	4.5	66.9	0.003

The p-value was calculated using the ^aWilcoxon signed-rank test.

Table 5. Comparison of LES pressure indices between the peristaltic recovery group and the non-recovery group after endoscopic intervention

	Recovery group (n=6)	Non-recovery group (n=18)	p ^b
Expiratory resting pressure (mmHg) (n, %)			0.066
≤15	6 (37.5)	10 (62.5)	
>15	0 (0.0)	8 (100.0)	
Mean resting pressure (mmHg) (n, %)			0.150
≤20	4 (44.4)	5 (55.6)	
>20	2 (13.3)	13 (86.7)	
Nadir relaxation pressure (mmHg) (n, %)			0.024
≤4	6 (42.9)	8 (57.1)	
>4	0 (0)	10 (100)	

LES: lower esophageal sphincter

^aLES pressure indices included expiratory resting, mean resting, and nadir relaxation pressures. ^bThe p-value was calculated using Fisher's exact test.

≤20 mmHg in 9 patients, and the nadir LES relaxation pressure decreased to <4 mmHg in 14 patients. Recovery of peristalsis was observed in 42.9% of these patients, and a significant dif-

ference in the nadir LES relaxation pressure was present between the two groups (Table 5). Figures 1 and 2 show the manometry results of peristaltic recovery among these patients. However, there were no statistically significant differences in baseline characteristics.

DISCUSSION

Treatment of achalasia aims to improve the symptoms by reducing the LES resting pressure. PBD and laparoscopic Heller myotomy are recommended as primary treatments, and the treatment outcomes are similar between them (2).

Post-treatment peristaltic recovery has been reported in some patients. This is thought to occur because of individual differences in the extent of neuronal dysfunction. During the early stage of the disease, myenteric inflammation is observed in the distal esophagus; as the disease progresses, loss of ganglion cells and neural fibrosis occur (15). Parrilla et al. (16) reported that peristalsis returned after myotomy in patients who were diagnosed with achalasia. This outcome could be associated with a short clinical evolution, minimal esophageal dilation, and conserved contractile capacity. Therefore, early treatment and a short disease evolution may be associated with the recovery of peristalsis (17).

Neither the recovery of peristalsis nor disease evolution was relevant in the present study. This may have been because the number of patients was too small and the loss of peristalsis induced an artifact on esophageal manometry. The manometry findings may have appeared to be consistent with aperistalsis because an increase in pressure in the esophageal body is transmitted simultaneously to all pressure transducers in the dilated esophagus (18).

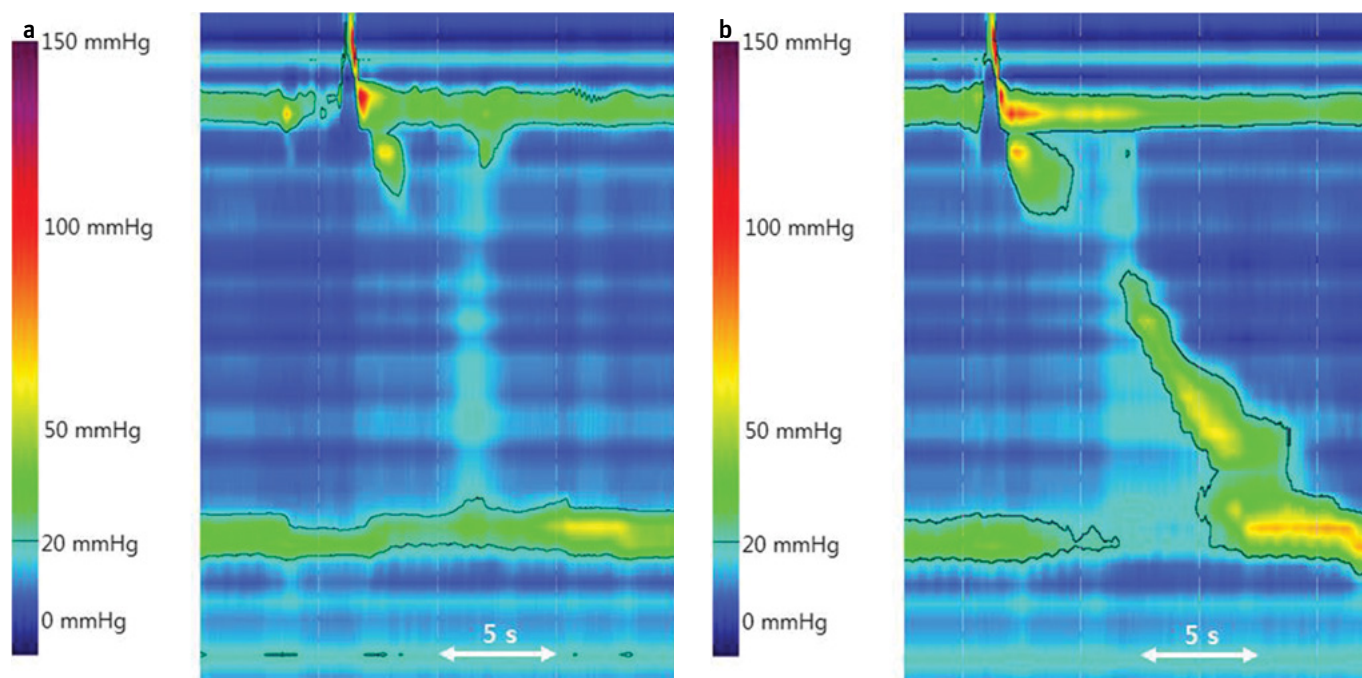


Figure 2. a, b. HRM before (a) and after (b) PBD in a 63-year-old female patient. Panesophageal pressurization is revealed in this HRM. After treatment, reduced LES pressure and recovery of peristalsis were observed (distal latency >4.5 s).

HRM: high-resolution manometry; LES: lower esophageal sphincter; PBD: pneumatic balloon dilatation

Partial peristaltic recovery was more highly prevalent in patients with type III achalasia in our study. One patient with type III achalasia exhibited partial peristaltic recovery after endoscopic intervention. It is thought that peristalsis may be preserved after treatment because esophageal inflammation is localized in the LES and dysfunction of the inhibitory ganglionic neuron is specific. This may be indicative of the unique pathogenic features of type III achalasia (19).

In addition, the partial recovery of peristalsis was associated with normalization of the nadir LES relaxation pressure in our study. More severe inflammation or fibrosis of the nerves in the LES may be associated with a higher LES pressure, which may then be reduced to a lesser extent after treatment. The LES pressure indices, including the expiratory resting, mean resting, and nadir relaxation pressure, were decreased. However, only the nadir relaxation pressure was associated with the recovery of peristalsis. The association between peristaltic recovery and symptom improvement or duration of disease remains unclear. In addition, the specific factors that are associated with recovery of peristalsis remain unknown.

Our study had some important limitations. Firstly, the patients underwent conventional manometry and HRM before and after endoscopic intervention. Although the patients were examined by conventional manometry, the results applied to the Chicago classification. Secondly, we did not address the differences associated with the various treatment modalities (PBD, BTI, and POEM). Thirdly, because of the retrospective design of this study, the follow-up periods after post-treatment manometry were not consistent and the number of cases was small.

In conclusion, endoscopic intervention for achalasia can improve patients' symptoms and decrease the LES relaxation, resting, and expiratory resting pressures. Normalization of the nadir LES relaxation pressure after endoscopic intervention may be a predictive factor for the recovery of esophageal peristalsis. However, prospective, large-scale studies are necessary to identify the association between the recovery of peristalsis and the type of achalasia or endoscopic intervention.

Ethics Committee Approval: Ethics committee approval was received for this study from the ethics committee of Soonchunhyang University (SCHBC 2014-08-022-002).

Informed Consent: Written informed consent was obtained from patients who participated in this study.

Peer-review: Externally peer-reviewed.

Author Contributions: Concept - S.J.H.; Design - S.K.P., S.J.H.; Supervision - S.J.H.; Resource - S.K.P., S.J.H., J.P.H.; Materials - S.K.P., S.J.H.; Data Collection and/or Processing - H.J.G., H.S.K., Y.S.M.; Analysis and/or Interpretation - S.J.H.; Literature Search - S.H.K., H.J.J., T.H.L.; Writing - S.K.P.; Critical Reviews - J.P.H., J.S.L., M.S.L.

Acknowledgements: We thank the nursing staff for their support and assistance with the procedures.

Conflict of Interest: No potential conflict of interest relevant to this article was reported.

Financial Disclosure: This work was supported by the Soonchunhyang University Research Fund.

REFERENCES

1. Champion JK, Delise N, Hunt T. Myenteric plexus in spastic motility disorders. *J Gastrointest Surg* 2001; 5: 514-6. [CrossRef]

2. O'Neill OM, Johnston BT, Coleman HG. Achalasia: a review of clinical diagnosis, epidemiology, treatment and outcomes. *World J Gastroenterol* 2013; 19: 5806-12. [\[CrossRef\]](#)
3. Boeckxstaens GE. Achalasia: virus-induced euthanasia of neurons? *Am J Gastroenterol* 2008; 103: 1610-2. [\[CrossRef\]](#)
4. Vaezi MF, Pandolfino JE, Vela MF. ACG clinical guideline: diagnosis and management of achalasia. *Am J Gastroenterol* 2013; 108: 1238-49. [\[CrossRef\]](#)
5. Teitelbaum EN, Soper NJ, Santos BF, et al. Symptomatic and physiologic outcomes one year after peroral esophageal myotomy (POEM) for treatment of achalasia. *Surg Endosc* 2014; 28: 3359-65. [\[CrossRef\]](#)
6. Lamet M, Fleshler B, Achkar E. Return of peristalsis in achalasia after pneumatic dilatation. *Am J Gastroenterol* 1985; 80: 602-4.
7. Hep A, Dolina J, Dite P, et al. Restoration of propulsive peristalsis of the esophagus in achalasia. *Hepatogastroenterology* 2000; 47: 1203-4.
8. Papo M, Mearin F, Castro A, Armengol JR, Malagelada JR. Chest pain and reappearance of esophageal peristalsis in treated achalasia. *Scand J Gastroenterol* 1997; 32: 1190-4. [\[CrossRef\]](#)
9. Mellow MH. Return of esophageal peristalsis in idiopathic achalasia. *Gastroenterology* 1976; 70: 1148-51.
10. Eckardt VF. Clinical presentations and complications of achalasia. *Gastrointest Endosc Clin N Am* 2001; 11: 281-92, vi.
11. Inoue H, Minami H, Kobayashi Y, et al. Peroral endoscopic myotomy (POEM) for esophageal achalasia. *Endoscopy* 2010; 42: 265-71. [\[CrossRef\]](#)
12. Bredenoord AJ, Fox M, Kahrilas PJ, et al. Chicago classification criteria of esophageal motility disorders defined in high resolution esophageal pressure topography. *Neurogastroenterol Motil* 2012; 24(Suppl 1): 57-65. [\[CrossRef\]](#)
13. Richter JE, Wu WC, Johns DN, et al. Esophageal manometry in 95 healthy adult volunteers. Variability of pressures with age and frequency of "abnormal" contractions. *Dig Dis Sci* 1987; 32: 583-92. [\[CrossRef\]](#)
14. Ghosh SK, Pandolfino JE, Rice J, Clarke JO, Kwiatek M, Kahrilas PJ. Impaired deglutitive EGJ relaxation in clinical esophageal manometry: a quantitative analysis of 400 patients and 75 controls. *Am J Physiol Gastrointest Liver Physiol* 2007; 293: 878-85. [\[CrossRef\]](#)
15. Goldblum JR, Rice TW, Richter JE. Histopathologic features in esophagomyotomy specimens from patients with achalasia. *Gastroenterology* 1996; 111: 648-54. [\[CrossRef\]](#)
16. Parrilla P, Martinez de Haro LF, Ortiz A, Morales G, Garay V, Aguilar J. Factors involved in the return of peristalsis in patients with achalasia of the cardia after Heller's myotomy. *Am J Gastroenterol* 1995; 90: 713-7.
17. Ciriza de los Rios C, Garcia L, Diez A, et al. Restoration of peristalsis in the esophagus of a patient diagnosed of achalasia. *Rev Esp Enferm Dig* 2002; 94: 697-702.
18. Stuart RC, Walsh TN. Esophageal peristalsis and achalasia. *Am J Gastroenterol* 1995; 90: 691-2.
19. Roman S, Kahrilas PJ, Mion F, et al. Partial recovery of peristalsis after myotomy for achalasia: more the rule than the exception. *JAMA Surg* 2013; 148: 157-64. [\[CrossRef\]](#)