



Protein-losing gastropathy caused by mesalamine in a patient with ulcerative colitis

To the Editor,

Mesalamine has been used as the first-line treatment of ulcerative colitis (UC) because of its efficacy and fewer side effects. Although mesalamine is known as a well-tolerated drug, some side effects, including nephrotoxicity, allergic reaction, and diarrhea, have been reported (1-4). However, protein-losing gastropathy as an adverse event of mesalamine is rare.

A 56-year-old female with a 2-year history of UC was admitted to this hospital for epigastric discomfort and edema in both legs. One month before her evaluation at this hospital, the patient was treated with mesalamine for active UC and pancolitis. She used mesalamine for approximately 2 weeks, and then, the symptoms, including nausea/vomiting and diarrhea, occurred. After discontinuing the mesalamine, the symptoms stopped.

Upon presentation to the clinic, the patient was relatively active and had been eating well. She had no known allergies to any medications. She did not smoke, drink alcohol, or use illicit drugs. Two years ago, she was diagnosed with UC for blood-tinged stool, but the patient had not taken the medications for UC. Her body weight was 73.0 kg and height was 164 cm, with normal vital signs. The patient had mild epigastric tenderness, abdominal distension, and pitting edema of both legs. The level of total proteins and albumin were 2.8 g/dL and 1.3 g/dL, respectively. The white blood cell count was 19,200/ μ L (lymphocyte 17.6%), the erythrocyte sedimentation rate was 2 mm/hr, and C-reactive protein was 1.9 mg/dL. Colonoscopic examination revealed mild to moderately active ulcerative colitis. Upper endoscopic examination revealed multiple round-raised erythematous erosions (size: 1-1.5 cm) with a large amount of yellowish and mucopurulent exudates in the gastric folds of the body (Figure 1a). The exudates resembled jelly and could not be easily untangled by a

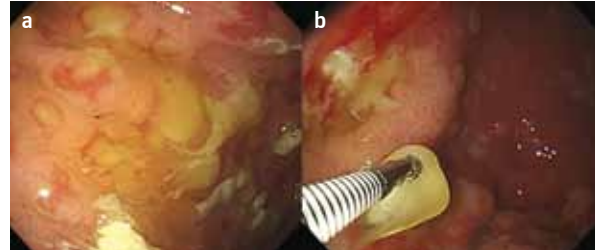


Figure 1. a, b. Upper endoscopic examination revealed multiple round-raised erythematous erosions (size: 1-1.5 cm) with a large amount of yellowish and mucopurulent exudates in the gastric folds of the body (**a**), and the exudates resembled jelly and could not be easily untangled by a forceps (**b**).

forceps (Figure 1b). An abdominal CT showed edema in the subcutaneous tissue of the pelvic cavity and enlargement of the para-aortic, portal hepatic, and mesenteric lymph nodes.

This patient was treated with albumin (2 bottles a day) to make up for the protein loss and omeprazole (intravenous bolus injection, twice a day) to reduce acid secretion for 2 weeks. Six days after treatment, we prescribed mesalamine to manage the UC. After taking the drug, the patient experienced a large number of episodes of diarrhea (≥ 10 per day) and vomiting (5-6 per day); so, we stopped the mesalamine treatment. Hypoproteinemia and edema in both legs resolved after 2 weeks of treatment with albumin and omeprazole. An endoscopic ultrasonography (EUS) and endoscopic mucosal resection (EMR) were performed to obtain more information. EUS revealed marked thickening of the second and third layers, with a heterogeneous echoic pattern at the gastric folds of the body (Figure 2). Histologically, the specimen showed dilation of the lymphatics, foveolar hyperplasia, and focal cryptitis (Figure 3). After 3 months of follow-up, we carefully prescribed mesalamine again in an attempt to treat the patient's UC. Unfortunately, after taking the drug, she had a number of diarrhea and vomiting episodes again. At the 3-year follow-up, the patient was

Address for Correspondence: Won Moon, Department of Internal Medicine, Kosin University College of Medicine, Busan, Republic of Korea
E-mail: moonone70@hanmail.net

Received: 9.8.2013 **Accepted:** 2.12.2013

© Copyright 2014 by The Turkish Society of Gastroenterology • Available online at www.turkjgastroenterol.org • DOI: 10.5152/tjg.2014.5951

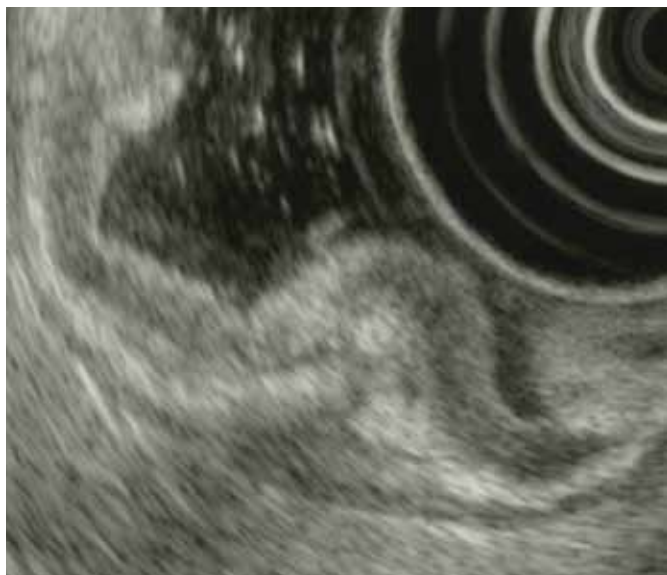

Figure 2. Endoscopic ultrasonography revealed marked thickening of the second and third layer, with a heterogeneous echoic pattern at the gastric folds of the body.

active and felt well, and an upper endoscopic examination revealed a much improved state of the lesion (Figure 4).

In conclusion, this case shows the occurrence of PLG caused by mesalamine in a patient with UC, but clinicians should be aware of PLG as an adverse event of mesalamine.

Ethics Committee Approval: N/A.

Informed Consent: N/A.

Peer-review: Externally peer-reviewed.

Author contributions: Concept - W.M., J.H.K.; Design - W.M., J.H.K.; Supervision - S.J.P., M.I.P., S.E.K.; Resource - W.M., H.K.C.; Materials - W.M., H.K.C., J.H.K.; Data Collection&/or Processing - W.M., J.H.K., H.K.C.; Analysis&/or Interpretation - W.M., J.H.K.; Literature Search - J.H.K., W.M.; Writing - J.H.K., W.M.; Critical Reviews - K.H.K., S.E.S.

Conflict of Interest: No conflict of interest was declared by the authors.

Financial Disclosure: The authors declared that this study has received no financial support.

Jae Hyun Kim¹, Won Moon¹, Seun Ja Park¹, Moo In Park¹, Sung Eun Kim¹, Ki Hwan Ku¹, Sung Eun Song¹, Hee Kyung Chang²

¹Department of Internal medicine, Kosin University College of Medicine, Busan, Republic of Korea

²Department of Pathology, Kosin University College of Medicine, Busan, Republic of Korea

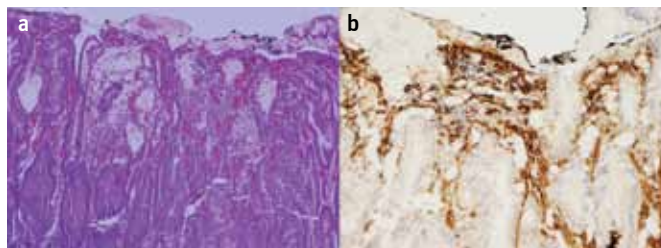


Figure 3. a, b. Histologically, the specimen showed dilation of the lymphatics, foveolar hyperplasia, and focal cryptitis (a) (Panel A: x100, H-E). Immunostaining for D2-40 was positive along the dilated lymph vessels (Panel B: x400, D2-40) (b).

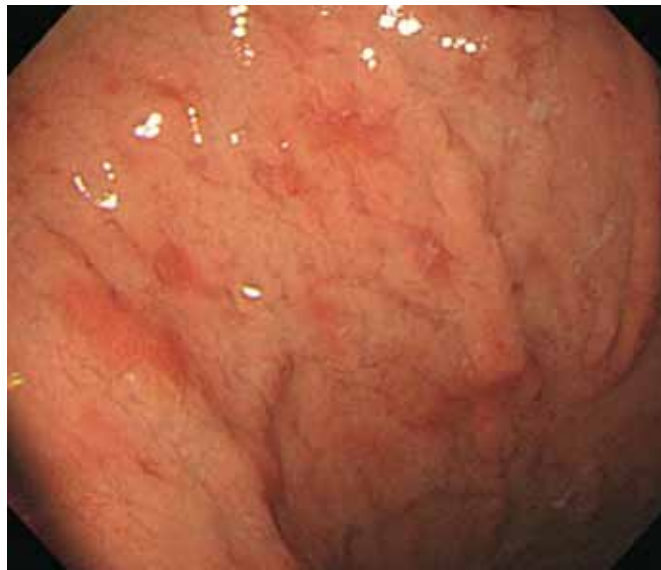

Figure 4. After 3 years of follow-up, an upper endoscopic examination revealed an improved state of the mucosal lesion.

REFERENCES

1. Marteau P, Nelet F, Le Lu M, Devaux C. Adverse events in patients treated with 5-aminosalicylic acid: 1993-1994 pharmacovigilance report for Pentasa in France. *Aliment Pharmacol Ther* 1996; 10: 949-56. [\[CrossRef\]](#)
2. Fiorentini MT, Fracchia M, Galatola G, Barlotta A, de la Pierre M. Acute pancreatitis during oral 5-aminosalicylic acid therapy. *Dig Dis Sci* 1990; 35: 1180-2. [\[CrossRef\]](#)
3. Miner P, Hanauer S, Robinson M, Schwartz J, Arora S. Safety and efficacy of controlled-release mesalamine for maintenance of remission in ulcerative colitis. Pentasa UC Maintenance Study Group. *Dig Dis Sci* 1995; 40: 296-304. [\[CrossRef\]](#)
4. Shimodate Y, Takanashi K, Waga E, Fujita T, Katsuki S, Nomura M. Exacerbation of bloody diarrhea as a side effect of mesalamine treatment of active ulcerative colitis. *Case Rep Gastroenterol* 2011; 5: 159-65. [\[CrossRef\]](#)