

Sclerosing mesenteritis (panniculitis) mimicking peritoneal tuberculosis

To the Editor,

Mesenteric panniculitis is the inflammatory form of sclerosing mesenteritis (SM), which is a rare disorder of the mesentery still underdiagnosed (1) and is characterized in pathology by the coexistence of fat necrosis, chronic inflammation, and fibrosis (2).

In this letter, we present the case of a man with a perioperative aspect mimicking peritoneal tuberculosis and a histological result of mesenteric panniculitis.

The 42-year-old patient was a smoker and had a history of surgery for intestinal obstruction 17 years ago. Current symptomatology consisted of recurrent occlusive episodes; the last episode lasted for 24 hours. Abdominal examination showed diffuse sensitivity without any palpable mass. The tuberculin skin test was slightly positive. Explorative laparotomy showed an inflammatory pseudocapsule involving the colon and the small bowel mesentery and diffuse, whitish 2–3-millimeter granules disseminated on the small bowel wall and the

peritoneum (Figure 1), mimicking the features of peritoneal tuberculosis. The perioperative exploration did not find any sign of ileitis. Multiple surgical biopsies had been performed.

Histological examination of the peritoneal biopsy specimen showed nodules of eosinophilic fat necrosis, containing areas of fibrosis and foci of microcalcifications, surrounded by an inflammatory cellular infiltrate made of histiocytes, giant cells, and lymphocytes (Figure 2). These features were consistent with the diagnosis of mesenteric panniculitis. The histological study did not find any histological sign of tuberculosis.

The abdominal computed tomography (CT, Somatom Emotion, Erlangen, Germany) performed after surgery showed an agglutination of intestinal loops in the left hemiabdomen, associated with subtle increased attenuation in the mesentery fat and a low amount of subparietal ascites (Figure 3). These imaging features suggested a diagnosis of sclerosing mesenteritis (3).

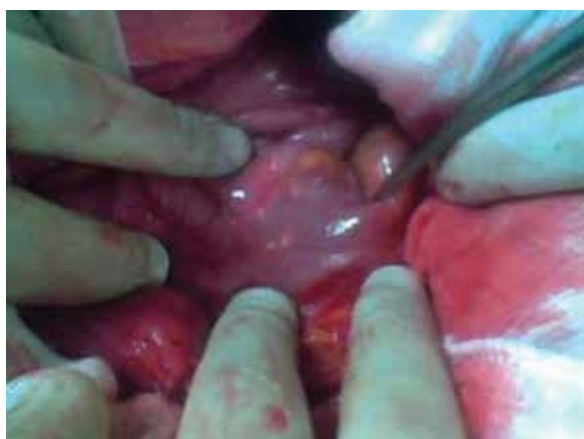

Figure 1. Intraoperative photograph of the surgical fields: diffuse macroscopic inflammatory reaction of mesentery and bowel, with multiples granulatous, whitish lesions disseminated on the small bowel wall and the parietal peritoneum.

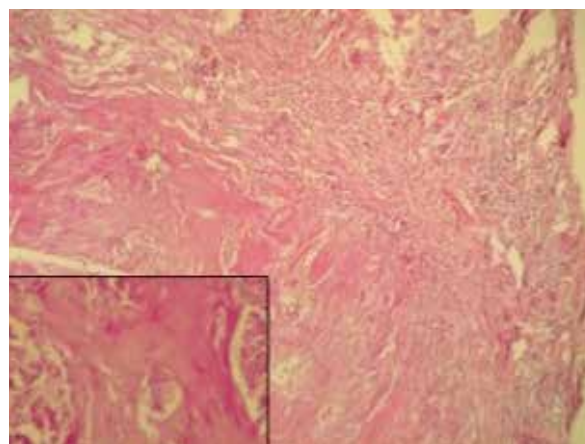


Figure 2. Histological examination of the peritoneal biopsy (HEx200; HE x400): nodular eosinophilic non-caseous necrosis on mesenteric biopsy.

Address for Correspondence: Ben Miled, Department of Radiology, Mongi Slim Hospital, La Marsa, Tunisia
E-mail: aycha.benmiled@gmail.com

Received: May 01, 2013

Accepted: June 17, 2013

© Copyright 2014 by The Turkish Society of Gastroenterology • Available online at www.turkjgastroenterol.org • DOI: 10.5152/tjg.2014.5463

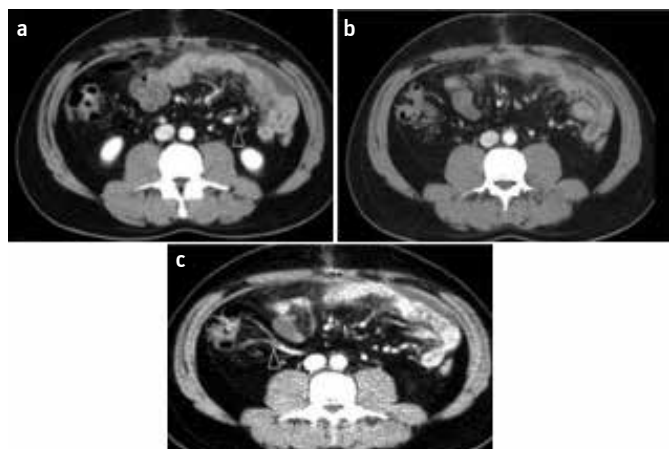


Figure 3. a-c. Axial slices of CT exam revealed an agglutination of intestinal loops in the left hemiabdomen and a low amount of subparietal ascites **(a)**, associated with a misty appearance of the mesenteric fat, taking the appearance of a fatty pseudomass **(b)** due to the dominant pathologic component (fat necrosis). Note the stretched and prominent appearance of mesenteric vessels (arrowheads) **(a, c)**.

Our aim is to emphasize some particularities that made the diagnosis difficult. Our patient was younger than most of the reported cases of SM, and the clinical presentation was dominated by a sub-occlusive syndrome, with the presence of perioperative features of peritoneal tuberculosis. As the patient lived in an endemic area of tuberculosis and had a positive skin

test, mesenteric tuberculosis was the more likely diagnosis. However, the absence of adenopathy and the normal appearance of the small bowel wall did not support this diagnosis. Another interesting characteristic of the present case was the history of laparotomy, as well as the smoking habit-both of which are conditions described as pathogenic factors (3). The diagnosis of mesenteric panniculitis should always be considered in a patient with abdominal obstruction and a fatty peritoneal pseudomass on CT (3).

Conflict of Interest: No conflict of interest was declared by the authors.

Ben Miled¹, Abderraouf Khiari², Emna Ennaifer³, Lotfi Hendaoui¹

¹Department of Radiology, Mongi Slim Hospital, La Marsa, Tunisia

²Department of General Surgery, Maghreb Medical, Tunis, Tunisia

³Department of Pathology, Institut Pasteur, Tunis, Tunisia

REFERENCES

1. Talwar A, Rayner H. The medical mystery of the fatty mesentery. *BMJ Case Rep* 2012. pii: bcr1220115443. doi: 10.1136/bcr.12.2011.5443.
2. Emory TS, Monihan JM, Carr NJ, Sobin LH. Sclerosing mesenteritis, mesenteric panniculitis and mesenteric lipodystrophy: a single entity? *Am J Surg Pathol* 1997; 21: 392-8.
3. Horton KM, Lawler LP, Fishman EK. CT Findings in sclerosing mesenteritis (panniculitis): spectrum of disease. *Radio Graphics* 2003; 23: 1561-7.