

Villous adenoma in gallbladder volvulus: A rare coincidence

To the Editor,

Gallbladder volvulus and gallbladder adenoma, especially villous adenoma are rare clinical conditions. They are more common in elderly female patients. We reported in this case a patient with gallbladder adenoma and volvulus.

An 80-year-old female admitted to our hospital with a sudden onset of right upper quadrant abdominal pain and vomiting that had worsened in hours. She had no abnormality in her medical history. She was conscious with a blood pressure of 110/70 mmHg. Her pulse rate was 96/min and body temperature was 37,2 °C. She had a sensitive palpable abdominal mass on right quadrant with positive Murphy sign on physical examination. She had neither leucocytosis nor other pathologies in laboratory results. Abdominal ultrasonography revealed hydropic gallbladder with a size of 37x99 mm. She had concentrated bile sludge and multiple millimetric calculi in the gallbladder lumen. Sonographic signs with edematous and thickened gallbladder wall besides pelvic free fluid around intestines led to the prediagnosis of acute cholecystitis. The patient refused hospitalization despite our insistence. On the following day, she admitted again with more severe abdominal pain, vomiting and fever. She had leucocytosis 13400 /uL. There was no change in her physical examination. We performed urgent laparotomy. A floating gangrenous gallbladder due to torsion was seen on laparotomy. It was not adhered to the liver or other adjacent tissues. It was covered by omentum and it floated over intestines. It was rotated clockwise 360 degrees along mesentery axis (Figure 1). It was detorsioned, ductus cycticus and arteria syctica were prepared and resected. The gallbladder was 11x5x3.5 cm in size and there was a 2.5x2x1 cm villous adenoma at the cervical region of gallbladder and a hemoragic infarct on the other region without any calculi on histopathological evaluation (Figure 2). She

was discharged on the third day of operation without any complication.

Gallbladder volvulus is a rare cause of acute abdominal pain. It seems to be more common in elderly thin female patients as our patient (1,2). In recent years, the incidence seems to be increasing probably due to longer life.

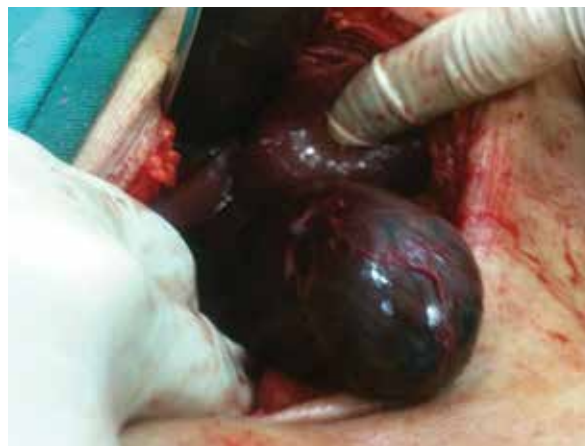

Figure 1. Gallbladder volvulus during laparotomy.

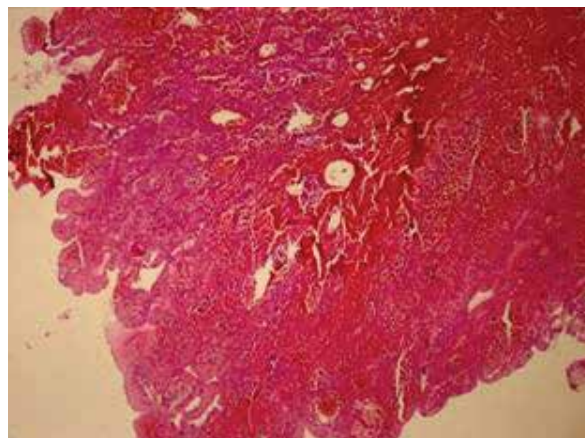


Figure 2. Microscopic image of villous adenoma of gallbladder. That location is between black arrows (Hematoxylin-eosine dye X40).

This study was presented at the Annual Meeting of European Society of Surgery, 22-24 November 2012, İstanbul, Turkey.

Address for Correspondence: Zeynep Özkan, Department of General Surgery, Elazığ Training and Research Hospital, Elazığ, Turkey

E-mail: drzeynepozkan@yahoo.com

Received: September 27, 2012

Accepted: November 19, 2012

© Copyright 2014 by The Turkish Society of Gastroenterology • Available online at www.turkjgastroenterol.org • DOI: 10.5152/tjg.2014.4289

Gallbladder volvulus occurs as acute torsion around its mesentery, consisting of the cystic artery and cystic duct. Long gallbladder mesentery, minimally or absence of adherence of gallbladder to the liver, liver atrophy, visceroptosis, loss of body weight, kyphosis, blunt abdominal trauma or atherosclerotic cystic artery and tortuous cystic duct are among the predisposing factors (3,4,5).

Ultrasonographic findings are nonspecific. Chen et al reported a specific pattern as '9 to O' pattern on abdominal axial computerized tomography (CT) for gallbladder torsion (2,6). The gallbladder is gangrenous and necrotic due to cut off of blood supply, so immediate surgical evaluation and operation is inevitable. In recent years, laparoscopic cholecystectomy is preferred since it is as safe as open surgery (7).

Gallbladder adenoma incidence is 0,5% in cholecystectomy specimens with a predominance of tubular structure. However, tubulovillous adenomas and villous adenomas are rare. Pure villous adenomas are extremely rare with an incidence of 0,08 % in autopsy series (8). Gallbladder adenomas are also more common in elderly female patients, like in gallbladder volvulus.

In conclusion, gallbladder villous adenoma and gallbladder volvulus are rare entities and their coincidence is extremely rare. Both of these pathologies are more common in elderly female patients. The patients especially older female patients with acute abdomen should be also evaluated for acute cholecystitis, even for rare causes such as gallbladder adenomas and/or gallbladder volvulus.

Conflict of Interest: No conflict of interest was declared by the authors.

Authors: Ayşe Nur Gönen¹, Zeynep Özkan¹, Seyfi Emir¹, Bekir Sarıncık¹, Gülçin Cihangiroğlu², Fatih Mehmet Yazar¹, Burhan Hakan Kanat¹

¹Department of General Surgery, Elazığ Training and Research Hospital, Elazığ, Turkey

²Department of Pathology, Elazığ Training and Research Hospital, Elazığ, Turkey

REFERENCES

1. Ortiz-Gonzales J, Reyes-Segura MP, Gutierrez-Carrillo F, Vega-Chavage RG. Volvulus of the gallbladder. Dig Dis Sci. 2003 Jun;48(6):1116-7
2. Chen Y, Rosati C. Necrotizing volvulus of the gallbladder with a distinct pattern on computed tomography scan. The Am Surg. 2001;77:E298-300.
3. Kitagawa H, Nakada K, Enami T. Two cases of torsion of the gallbladder diagnosed preoperatively. J Pediatr Surg. 1997;32:1567-1569. doi: 10.106/S0022-3468(97)90454-1.
4. Caliskan K, Parlakgumus A, Koc Z, Nursal TZ. Acute torsion of the gallbladder: A case report. Cases J. 2009; 2: 6641. doi: 10.1186/1757-1626-2-6641
5. Steiber AC, Bauer IJ. Volvulus of the gallbladder. Am J Gastroenterol. 1983;78:96-98
6. Nicholas JM. Image of the month. Gallbladder volvulus. Arch Surg. 2002 Jun;137(6):741-2.
7. Nagaha M, Muto Y, Yamada M, Shiraishi M, Kusano T, Toda T. Villous adenoma of the gallbladder: a case report. Hepatogastroenterology. 1997;44(15):681-4
8. Petrovic B, Petrovic A, Zivkovic V, Malina M, Petrovic V. Intestinal type of villous adenoma of gallbladder. Acta Medica Medianae 2010, Vol.49(3):50-3