

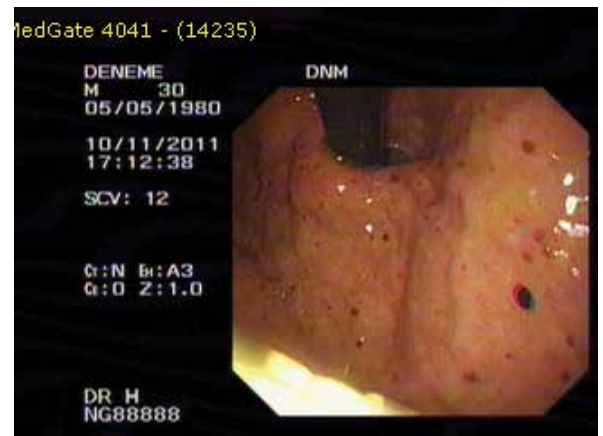## Malignant melanoma of the stomach in an elderly patient

To the Editor,

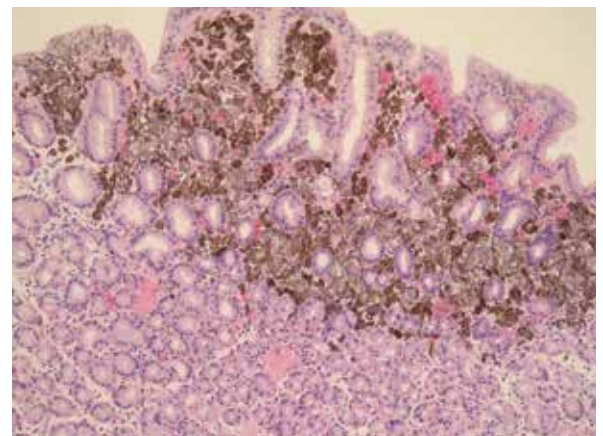
Malignant melanoma (MM) is a highly aggressive disease that originates from typical sites where the melanocytes can be usually found (skin, eyes, meninges, and anal region) (1,2). MM can attack any part of the gastrointestinal (GI) tract, and this event is mainly caused by metastatic spread from primary cutaneous lesions. However, there is a portion of GI melanomas without any documented evidence of a primary lesion in the skin or elsewhere, even after thorough examination. In such cases, involved organ of the digestive system is considered the primary site of MM (2,3).

A 71-year-old male presented with unexplained weight loss, upper abdominal discomfort and diffuse bone pain. His physical examination revealed pallor but no evidence of lymphadenopathy or organomegaly. Initial laboratory studies showed a white blood cell count of 12100/mm<sup>3</sup> with 80% neutrophils. Hemoglobin level was 11 g/dL and platelet count was 384000/mm<sup>3</sup>. Serum alkaline phosphatase level (375 IU/L), lactate dehydrogenase level 483 IU/L and gamma-glutamyl-transferase level (232 IU/L) were significantly elevated. Tumor markers were all within normal values except for cancer antigen (CA) 125 which was 53 U/ml (normal range, 1-35 U/mL). A computed tomography (CT) scan of the abdomen showed multiple hepatic lesions highly suggestive of metastases, as well as an irregular mass at the left inguinal region. A CT scan of the lung revealed large right-sided pleural effusion with no evidence of metastases to the lung parenchyma. Therefore, we started to investigate the presence of a malignant disease in the patient. Upper gastrointestinal endoscopy revealed multiple pigmented and elevated mucosal lesions in the stomach (Figure 1). A biopsy was performed and histological examination showed a solid mass with nests of cells with an epithelioid appearance and pigmented cytoplasm (Figure 2). Immu-

nohistochemical evaluation revealed the neoplastic cells were positive for S-100, HMB-45 and Melan A, and negative for cytokeratin, epithelial membrane antigen and pan-cytokeratin. Ki-67 index was 70%. Cytological examination of pleural fluid also showed metastatic malignant melanoma. Ophthalmologic, dermatologic



**Figure 1.** Endoscopic images of the primary malignant melanoma of stomach.



**Figure 2.** Histopathology of the tumor showing a solid mass with nests of cells with an epithelioid appearance and pigmented cytoplasm (hematoxylin and eosin stain ; X400).

**Address for Correspondence:** Erdem Çubukçu, Department of Medical Oncology, Uludağ University Faculty of Medicine, Bursa, Turkey  
E-mail: erdemcubukcu@uludag.edu.tr

**Received:** June 30, 2012

**Accepted:** September 27, 2012

© Copyright 2014 by The Turkish Society of Gastroenterology • Available online at [www.turkjgastroenterol.org](http://www.turkjgastroenterol.org) • DOI: 10.5152/tjg.2014.3845

and oral examinations were negative for other primary site of melanoma. He then received temozolomide 250 mg/m<sup>2</sup> orally for 5 days, every 4 weeks. However, he died after his second chemotherapy cycle because of progressive disease.

To establish the diagnosis of primary gastric melanoma, certain criteria have been suggested, including no history of concurrent or previous removal of a melanoma or atypical melanotic lesion from the skin or other organs, and lack of other organ involvement. Our patient exhibited these suggestive features, and the clinical picture and metastatic pattern of his disease was quite similar to that of primary gastric cancer. Therefore, we believed that the patient suffered from primary gastric MM.

The clinical course of the previously reported cases suggest that MM arising from the stomach may show a more aggressive behavior pattern and have a worse prognosis than cutaneous MM (3-5). This poor prognosis is possibly related to the late diagnosis of the patients and early dissemination of the disease because of the rich blood and lymphatic supply of the stomach. Early-stage gastric melanomas can be successfully treated with gastrectomy without any adjuvant therapy (6). Adjuvant radiotherapy and/or chemotherapy should be considered for patients with lymph node involvement to prevent early disease recurrence (7). Patients with advanced disease probably will not derive any benefit from systemic chemotherapy, as in our case.

**Conflict of Interest:** No conflict of interest was declared by the authors.

**Erdem Çubukçu<sup>1</sup>, Ömer Fatih Ölmez<sup>1</sup>, Kanat Özkan<sup>1</sup>, Murat Pekgöz<sup>1,2</sup>, Nesrin Uğraş<sup>1,3</sup>, Adem Deligönül<sup>1,4</sup>, Osman Manavoğlu<sup>1</sup>**

<sup>1</sup>Department of Medical Oncology, Uludağ University Faculty of Medicine, Bursa, Turkey

<sup>2</sup>Department of Gastroenterology, Uludağ University Faculty of Medicine, Bursa, Turkey

<sup>3</sup>Department of Pathology, Uludağ University Faculty of Medicine, Bursa, Turkey

<sup>4</sup>Department of Internal Medicine, Uludağ University Faculty of Medicine, Bursa, Turkey

## REFERENCES

1. Reintgen DS, Thompson W, Garbutt J, et al. Radiologic, endoscopic, and surgical considerations of melanoma metastatic to the gastrointestinal tract. *Surgery* 1984; 95: 635-9.
2. Patel JK, Didolkar MS, Pickren JW, et al. Metastatic pattern of malignant melanoma. A study of 216 autopsy cases. *Am J Surg* 1978; 135: 807-10.
3. Rao GM, Satyanarayana Y, Janaki M, et al. Primary melanocarcinoma of stomach. *Indian J Gastroenterol* 1999; 18: 176.
4. Jelincic Z, Jakic-Razumovic J, Petrovic I, et al. Primary malignant melanoma of the stomach. *Tumori* 2005; 91: 201-3.
5. Schuchter LM, Green R, Fraker D. Primary and metastatic diseases in malignant melanoma of the gastrointestinal tract. *Curr Opin Oncol* 2000; 12: 181-5.
6. Lagoudianakis EE, Genetzakis M, Tsekouras DK, et al. Primary gastric melanoma: a case report. *World J Gastroenterol* 2006; 12: 4425-7.
7. Yamamura K, Kondo K, Moritani S. Primary malignant melanoma of the stomach: report of a case. *Surg Today* 2012; 42: 195-9.