

Iliac arteriovenous fistula presenting with ascites

Yunus Keser Yılmaz¹, Mehmet Çelikkilek², Savaş Sarıkaya³, Aylin Okur⁴, Asuman Çelikkilek⁵, Tugay Atalay⁶, Lütfi Akyol⁷, Nagehan Sözen Gencer⁷, Serkan Çelik⁸, Hasan Ekim¹

¹Department of Cardiovascular Surgery, Bozok University Faculty of Medicine, Yozgat, Turkey

²Department of Gastroenterology, Bozok University Faculty of Medicine, Yozgat, Turkey

³Department of Cardiology, Bozok University Faculty of Medicine, Yozgat, Turkey

⁴Department of Radiology, Bozok University Faculty of Medicine, Yozgat, Turkey

⁵Department of Neurology, Bozok University Faculty of Medicine, Yozgat, Turkey

⁶Department of Neurosurgery, Bozok University Faculty of Medicine, Yozgat, Turkey

⁷Department of Internal Medicine, Bozok University Faculty of Medicine, Yozgat, Turkey

⁸Department of Cardiovascular Surgery, Erzincan University Faculty of Medicine, Erzincan, Turkey

ABSTRACT

Arteriovenous fistula presents rarely with ascites. Diagnosis, with an elusive clinical presentation, is often incidental or delayed. A 35-year-old woman presented with ascites and cardiac decompensation. Contrast enhanced computed tomography revealed arteriovenous fistula between the left common iliac artery aneurysm and the left common iliac vein. The patient underwent endovascular treatment with arterial access was performed, with implantation of a stent graft in the iliac artery to cover the fistulous communication. At follow-up 1 month later, she was asymptomatic without ascites. Arteriovenous fistula should be considered in the differential diagnosis of patients with ascites and cardiac decompensation. The endovascular treatment of the arteriovenous fistula should be considered as a first line option.

Keywords: Arteriovenous fistula, ascites, heart failure, endovascular procedures

INTRODUCTION

Abdominal arteriovenous (AV) fistulas are rare clinical abnormalities with a rupture of an aortic or iliac aneurysm into the inferior vena cava, the iliac or renal veins (1). Clinical presentation can vary greatly but commonly includes back pain, high-output congestive cardiac failure and the presence of an abdominal bruit. Diagnosis, with an elusive clinical presentation, is often incidental or delayed (1). Clinical presentation with ascites is rare in iliac AV fistulas (2).

Surgery is the traditional treatment for this condition, consisting of fistula closure and aneurysm repair, usually with an aortic or aortoiliac graft (3). Endovascular repair of such fistulas is a growing trend in vascular surgery (4). This is a case of a percutaneous endovascular exclusion of an ilio-iliac AV fistula in a 35-year-old female presenting with ascites and swelling in the legs.

CASE PRESENTATION

A 35-year-old woman was referred to our out-patients clinic with ascites. She has a five months history of increased abdominal girth and breath shortness. Her complaints started and increased gradually after lumbar discectomy five month prior to admission. Physical examination revealed a blood pressure, 100/70 mm Hg; heart rate, 86 beats/min; respiratory rate, 24 breaths/min; and temperature, 36°C. Skin and sclerae were anicteric. The lungs had bilateral basal crepitations without evidence of pleural effusion. Grade 3/6 holosystolic murmur was best heard at the left mid-sternal border. The abdomen was massive distended with a fluid wave and shifting dullness consistent with ascites. Examination over the left lower quadrant in the abdomen revealed a thrill and bruit. Bilateral asymmetrical lower extremity edema to the ankle was noted.

This study was presented at the 29th National Gastroenterology Congress, 20-25 November 2012, Antalya, Turkey

Address for Correspondence: Mehmet Çelikkilek, Department of Gastroenterology, Bozok University Faculty of Medicine, Yozgat, Turkey
E-mail: drcelikkilek@yahoo.com

Received: February 02, 2013 **Accepted:** November 20, 2013

© Copyright 2014 by The Turkish Society of Gastroenterology • Available online at www.turkjgastroenterol.org • DOI: 10.5152/tjg.2014.4937

Initial laboratory examination showed moderate bilirubin elevation with total bilirubin 1.9 mg/dL and conjugated bilirubin 0.4 mg/dL. Electrocardiogram showed normal sinus rhythm. Chest radiograph showed cardiomegaly. Abdominal ultrasonography showed advanced ascites. By color doppler ultrasonography, portal vein diameter was measured 10 mm at its midpoint. Portal system veins were patent with forward flow. There was no evidence of obstruction of the hepatic veins. Ascitic fluid had a total protein of 3.0 g/dL, albumin of 1.8 g/dL, and unremarkable cytological, differential, and culture findings. The serum ascites albumin gradient was calculated as 1.8 g/dL and further testing was obtained.

Echocardiography showed normal left ventricular function, with an ejection fraction of 54% to 80%, moderate tricuspid regurgitation, moderate right ventricular enlargement with increased pulmonary artery systolic pressure of 55 mm Hg, and no atrial or ventricular septal defects. With a history of lumbar disectomy and bed rest, we performed contrast enhanced multislice computed tomography (CT) to exclude pulmonary embolism. CT did not show pulmonary embolism but inferior vena cava and hepatic veins were dilated. Abdomen CT revealed a 11x14 mm diameter saccular aneurysm of left common iliac vein approximately two centimeters distal of the aortoiliac bifurcation and a 0.7-cm diameter fistula between the left common iliac artery aneurysm and the left common iliac vein at this level (Figure 1a-1b). Intraabdominal fluid was showed by abdominal CT (Figure 2a).

The patient underwent endovascular treatment with arterial access was performed, with implantation of a stent graft in the iliac artery to cover the fistulous communication. Marked improvement was seen with intra-abdominal fluid and vena cava dilatation (Figure 2b). Early enhancement of the left common iliac vein aneurysm due to minimal leakage demonstrated by abdominal CT taken in postoperative 48 hour (Figure 3a). Her postoperative course was uncomplicated. After ten days, postoperative echocardiography showed resolution of right ventricular overload and elevated pulmonary pressure with mild tricuspid regurgitation and pulmonary artery systolic pressure of 20 mm Hg. At follow-up 1 month later, she was asymptomatic without ascites and also her bilateral asymmetric swelling of legs had resolved. At control CT, there was found neither aneurysm nor leakage (Figure 3b).

DISCUSSION

There are limited reported cases of iliac AV fistulas presenting with ascites (2,5). Liver involvement and ascites more commonly presented with aorto-caval AV fistulas. Abdominal, low back, or hip pain are the most common complaints and abdominal bruit, pulsatile abdominal mass, lower extremity edema are the most common physical findings at presentation with AV fistulas (2).

Some hemodynamic changes occur due to the blood flow from high-resistance arterial system to the venous system in

AV fistulas. Blood flow to the venous system increases venous volume, pressure and the venous return. With a decrease in peripheral vascular resistance, the cardiac output increases and the sodium-retaining systems activity increases. Increased stroke volume may cause cardiac failure. Hyperdynamic state with cardiac decompensation leads to dyspne, ascites and swelling in the legs (1).

Arteriovenous fistulas may results from trauma, iatrogenic injuries and spontaneously. Iatrogenic and traumatic conditions occurs less than 20% of cases (1). AV fistulas have been reported as a complication of lumbar disc surgery (4). After spinal surgery the causal effect of AV fistula is the vascular damage of the aorta, vena cava, or iliac vessels due to the penetration of the anterior longitudinal ligament with dissection instruments (6) Anatomy of major abdominal vessels and their close relationship to the lumbar vertebrae is important for surgeons.

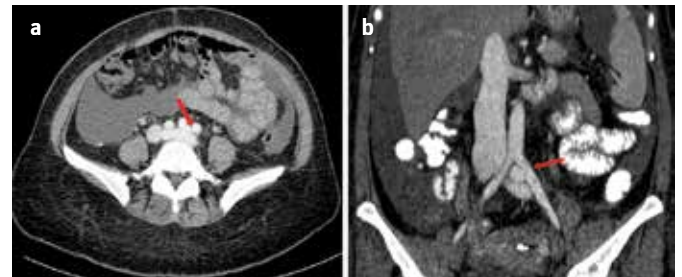


Figure 1. a, b. Axial abdominal CT scan demonstrated early opasification of the left common iliac vein and saccular aneurysm of proximal left iliac vein (Arrow) (a). Coronal reformatted abdominal CT demonstrated fistulization between the left common iliac artery and aneurysm (Arrow) (b).

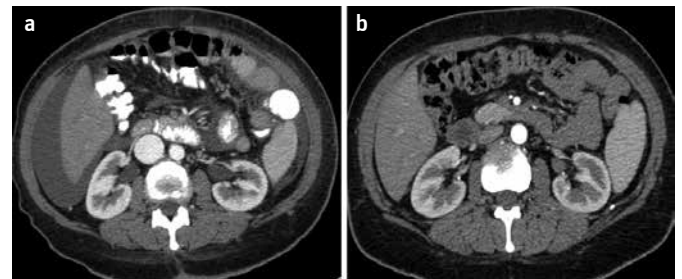


Figure 2. a, b. Peritoneal fluid excess in abdomen and dilated inferior vena cava identified by CT (a). Intra-abdominal fluid and vena cava dilatation was seen marked improvement after left iliac artery stenting (b).

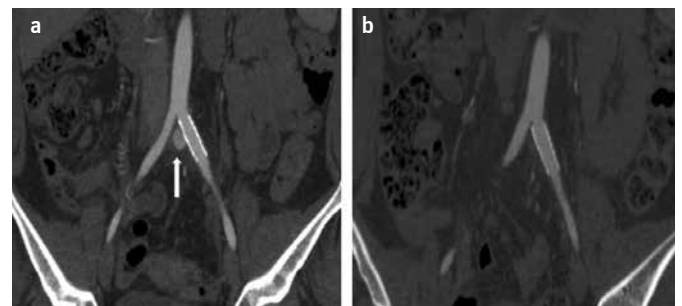


Figure 3. a, b. Coronal abdominal CT showed covered left iliac artery stent and it demonstrated early enhancement of the left common iliac vein aneurysm due to minimal leakage (arrow) (a). Aneurysm and leakage was not revealed at follow-up 1 month later (b).

Awareness of the anatomical location of vascular structures may reduce both the morbidity and mortality rate in lumbar disc surgery.

Traditional treatment of iliac AV fistulas with surgery was thought to be not safe, with reported surgical mortality rates of 9-34%. Intra-operative blood loss was common up to six liters (7). Endovascular approach to AV fistulas has led to reduction in mortality and morbidity with a technical success rate of 96%. Endovascular treatment of AV fistulas is a safe and effective option with good short- and medium-term results (1).

We describe an interesting and unusual presentation of an AV fistula with ascites and swelling in the legs and an excellent outcome after endovascular treatment. Concomitant symptoms and clinical signs of cardiac failure should raise the suspicion of this rare pathological condition. The endovascular treatment of the arteriovenous fistula, without exposing the patient to the high morbidity and mortality associated with open surgery, should be considered as a first line option.

Conflict of Interest: No conflict of interest was declared by the authors.

REFERENCES

1. Antoniou GA, Koutsias S, Karathanos C, Sfyroeras GS, Vretzakis G, Giannoukas AD. Endovascular stent-graft repair of major abdominal arteriovenous fistula: a systematic review. *J Endovasc Ther* 2009; 16: 514-23.
2. Chiorean MV, Morford RG, Bivins MH, Pardi DS. Iliac arteriovenous fistula with renal insufficiency, ascites, hepatomegaly, and abnormal liver test results. *Mayo Clin Proc* 2001; 76: 661-3.
3. Davis PM, Gloviczki P, Cherry KJ Jr, Toomey BJ, Stanson AW, Bower TC, et al. Aorto-caval and ilioliac arteriovenous fistulae. *Am J Surg* 1998; 176: 115-8.
4. Sarmiento JM, Wisniewski PJ, Do NT, et al. Bifurcated endograft repair of ilio-iliac arteriovenous fistula secondary to lumbar diskectomy. *Ann Vasc Surg* 2010;24: 551.e13-7.
5. Du Toit DF, Van der Merwe DM, Groenewald JH, De Roubaix JA. High-output cardiac failure associated with an iliac artery aneurysm and arteriovenous fistula. A case report. *S Afr Med J* 1983; 63: 293-4.
6. Düz B, Kaplan M, Günay C, Ustünsöz B, Uğurel MS. Iliocaval arteriovenous fistula following lumbar disc surgery: endovascular treatment with a Stent-graft. *Turk Neurosurg* 2008;18: 245-8.
7. Brewster DC, Cambria RP, Moncure AC, Darling RC, LaMuraglia GM, Geller SC, et al. Aortocaval and iliac arteriovenous fistulas: recognition and treatment. *J Vasc Surg* 1991; 13: 253-64.