

Mesenteric calcified cystic lymphangioma in an adult patient

Yavuz ALBAYRAK¹, Fatih ALBAYRAK², Serdar ARSLAN¹, İlknur ÇALIK³

Department of ¹General Surgery and ³Pathology, Erzurum Region Education and Research Hospital, Erzurum
 Department of ²Internal Medicine, Atatürk University, School of Medicine, Erzurum

Abdominal cystic lymphangiomas are rare congenital benign malformations of the lymphatic system. To the best of our knowledge, only 6 mesenteric calcified cystic lymphangiomas have ever been reported. We herein describe a woman who presented to our hospital with stomachache that had been continuous for approximately 8 months. An abdominal computed tomography showed a cystic lesion. In the exploration, the cyst was totally excised. Based on the histomorphological data, a case of "calcified cystic lymphangioma" was diagnosed. Although mesenteric lymphangiomas are rare, especially in adults, they should be considered as a possible cause of abdominal pain. Treatment is surgical with resection of the mass, sometimes including resection of adjacent bowel.

Key words: Calcified cystic lymphangioma, CD31, mesentery

Yetişkin hastada mezenterik kalsifiye kistik lenfanjioma

Abdominal kistik lenfanjiomlar, lenfatik sistemin benign kistik malformasyonlarıdır. Bildiğimiz kadarıyla literatürde şu ana kadar altı tane kalsifiye kistik lenfanjiom olgusu bildirilmiştir. Biz yaklaşık sekiz aydır mide ağrısı şikayeti ile başvuran bir bayan hastayı sunacağız. Hastanın abdominal bilgisayarlı tomografisinde kistik lezyon izlenmişti. Eksploasyonda kist total olarak eksiz-e edildi. Spesmenin histopatolojik değerlendirilmesinde kalsifiye kistik lenfanjiom olduğu tespit edildi. Erişkinlerde çok nadir görülmesine rağmen, karın ağrısı şikayeti nedeni olarak mezenterik lenfanjiomalar akılda tutulmalıdır. Tedavide kistin total eksiz-yonu uygulanır. Bazen komşu dokularda birlikte eksiz-e edilebilir.

Anahtar kelimeler: Kalsifiye kistik lenfanjioma, CD31, mezenter

INTRODUCTION

Mesenteric cystic lymphangiomas (MCLs) are rare congenital benign malformations of the lymphatic system that are commonly located on the small bowel mesentery and less typically on the omentum, mesocolon and retroperitoneum (1). Most lymphangiomas are found in the head and neck; intra-abdominal locations are very unusual. Abdominal cystic lymphangiomas are more frequent in boys (5:2), with a mean age at presentation of 2 years (2). The common presentations of intra-abdominal cystic lymphangiomas are abdominal mass and distension, and most have cystic and septal components (3). To the best of our knowledge, only six

mesenteric calcified cystic lymphangiomas in adults have ever been reported (4). We describe an extraordinary case of mesenteric calcified cystic lymphangioma in a 32-year-old woman.

CASE REPORT

A 32-year-old female patient presented to our clinic with stomachache that had been continuous for approximately eight months. Her arterial blood pressure was 120/80 mmHg, pulse rate 85 beats/minute and respiration 19/minute, and her surface temperature was normal. An approximately 10 cm in diameter mass was palpable in her

Address for correspondence: Yavuz ALBAYRAK
 Erzurum Region Education and Research Hospital, Department of
 General Surgery, Erzurum, Turkey
 Phone: + 90 442 242 22 75
 E-mail: yavuzalbayrakdr@gmail.com

Manuscript received: 09.02.2010 **Accepted:** 27.04.2010

Turk J Gastroenterol 2011; 22 (3): 341-343
 doi: 10.4318/tjg.2011.0224

abdomen. The rest of the abdomen and a digital rectal examination were unremarkable. Laboratory results were within normal limits. The chest X-ray was normal. An abdominal computed tomography showed an 8x7x7 cm cystic lesion with sharp boundaries and lobular contours in the middle abdominal region between the jejunal loop, starting at the L2 vertebra level and ending at the L4 vertebra level. This was thought to be a mesenteric hydatid or diverticular cyst, when evaluated together with the abdominal ultrasonography taken in correlation (Figure 1).

Surgery was planned for the patient. In the exploration, a white cystic lesion of approximately 8 cm in diameter, with increased vascularization and lobular contours, was observed in the intestinal mesentery, 200 cm proximal to the ileocecal valve. A decision was made to excise the lesion (Figure 2). The cyst ruptured during excision and a milky white liquid drained out. It was totally excised.

The pathological study of slices taken from the macroscopically 7x5x3 cm, grayish yellow, irregular surfaced tissue sample of the excised cyst showed a cystic structure with 1-2 mm thick walls filled with a milky liquid. The histopathological study was carried out on hematoxylin and eosin (H&E)-dyed slices prepared from tissue samples taken from the cyst wall after the follow-up. Large numbers of lymphatic veins covered with flattened endothelial cells, generally having smooth muscle bundles in their walls and showing cystic expansion in places, were observed. In some areas of the vein walls, lymphoid aggregates and dystrophic calcification were noted. The immunohistochemical CD31 test showed immune reactivity in the endothelial cells. Based on the histomorphological and immunohistochemical data, a case of "calcified cystic lymphangioma" was diagnosed (Figure 3).

DISCUSSION

Mesenteric cystic lymphangiomas (MCLs) occur at all ages, although most (65%) are present at birth. In general, 90% become symptomatic before the second year of life, and nearly 60% are diagnosed before the fifth year of life (5). MCLs are encountered only rarely in surgical practice; the frequency is less than 1 per 100,000 hospital admissions (6).

Losanoff *et al.* (3) defined four different types of MCLs: pedicled, sessile, retroperitoneal extended,

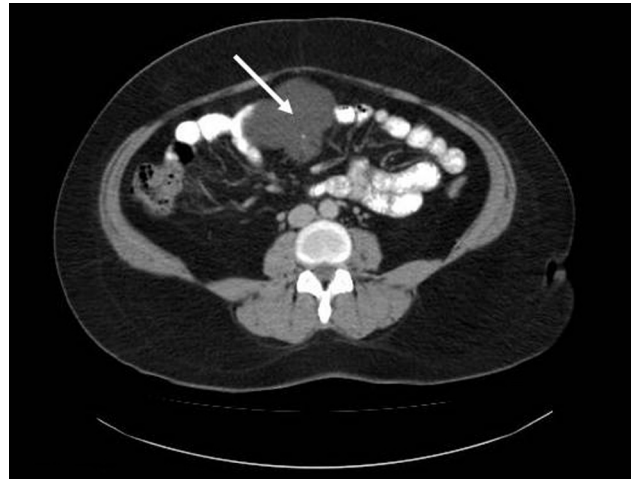


Figure 1. Computed tomography imaging of the abdomen shows a cystic lesion with sharp boundaries and lobular contours in the middle abdominal region between the jejunal loop (arrow).

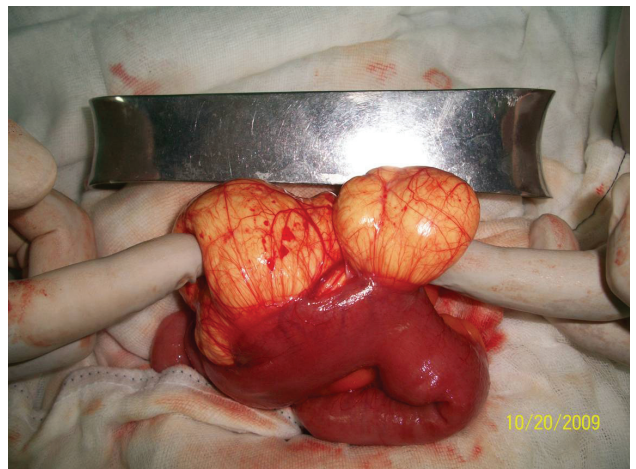


Figure 2. Surgical findings with a lobulated cystic lesion with soft consistency in the intestinal mesentery.

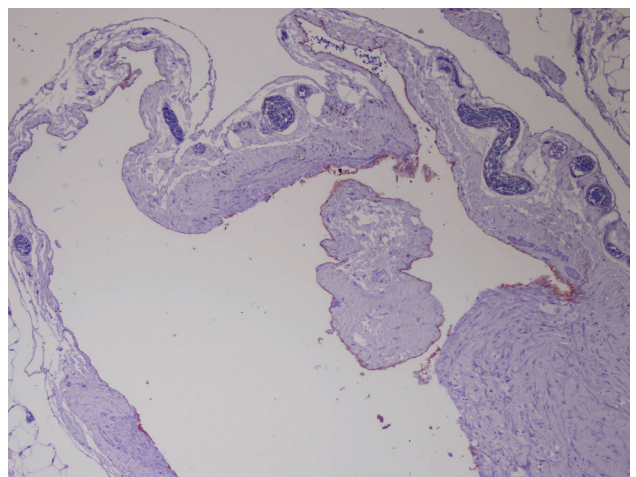


Figure 3. Immunostaining showing immunoreactivity to CD31.

and multicentric. The etiology of lymphangiomas is still a matter of discussion. A well-established theory suggests that lymphangiomas arise from sequestrations of lymphatic tissue during embryonic development (1,7,8). On the other hand, Godar postulated that premature lymphatics appear as mesenchymal slits, which coalesce and normally communicate with the venous system. Failure to establish this communication may lead to a lymphangioma (8). Fifty percent of cases involve the head and neck, with only 10% occurring in internal organs. Intra-abdominal cystic lymphangiomas may arise from the retroperitoneum, the mesentery and the visceral organs (2). There are only a few case reports of mesenteric lymphangioma in adolescence (3,7).

The common presentations of intra-abdominal cystic lymphangiomas are abdominal mass and distension, and most have cystic and septal components (2). Most MCL patients are initially asymptomatic, with vague and obscure abdominal symptoms emerging early or late, depending on the size and location of the cyst. The clinical symptoms are protean and include pain, nausea, vomiting, or alterations in bowel habits (9). Our patient had chronic stomach pains that had been ongoing for eight months. Known complications that may associate with mesenteric cysts include torsion,

rupture, hemorrhage, intestinal obstruction due to volvulus, extraneous pressure on nearby organs, and very rarely, malignant transformation – usually sarcoma, although adenocarcinoma has also been reported (10,11). To our knowledge, only six mesenteric calcified cystic lymphangiomas have been reported previously (4). Ultrasonography and computed tomography are considered the most appropriate radiodiagnostic modalities to evaluate cysts of the mesentery, although usually ultrasonography alone will suffice (2,12).

The differential diagnosis of abdominal cystic lymphangiomas must include other fluid-filled lesions such as pseudocysts, dermoid cysts, enteric duplications, lymphoceles, or neoplasms like mesotheliomas, pancreatic tumors, lipomas, teratomas, leiomyosarcomas, neurofibromas, or liposarcomas (13). The treatment of choice is radical excision, since incomplete resection may lead to recurrence (14). We completely excised the cystic lesion present in the intestinal mesentery of our patient.

Although mesenteric lymphangiomas are rare, especially in adults, they should be considered as a possible cause of abdominal pain. Treatment is surgical with resection of the mass, sometimes including resection of the adjacent bowel. After surgery, recurrence rates are low and are usually the result of incomplete excision.

REFERENCES

- Alqahtani A, Nguyen LT, Flageole H, et al. 25 years experience with lymphangiomas in children. *J Pediatr Surg* 1999; 34: 1164-8.
- Konen O, Rathaus V, Dlugy E, et al. Childhood abdominal cystic lymphangioma. *Pediatr Radiol* 2002; 32: 88-94.
- Losanoff JE, Richman BW, El-Sherif A, et al. Mesenteric cystic lymphangioma. *J Am Coll Surg* 2003; 196: 598-603.
- Buccoliero AM, Castiglione F, Maio V, et al. Calcified cystic lymphangioma of the mesentery: case report. *Fetal Pediatr Pathol* 2009; 28: 209-15.
- Caro PA, Mahboubi S, Faerber EN. Computed tomography in the diagnosis of lymphangiomas in infants and children. *Clin Imag* 1991; 15: 41-46.
- Stopinski J, Stephan S, Staib I. Intra-abdominal cystic lymphangioma and mesenteric cysts as a cause of abdominal discomfort. *Langenbecks Arch Chir* 1994; 379: 182-7.
- Dursun H, Albayrak F, Yildırım R, et al. Giant mesenteric cyst can present as pseudoascites with raised Ca125. *Turk J Gastroenterol* 2009; 20: 305-6.
- Özdoğan M. Acute abdomen caused by a ruptured spontaneously infected mesenteric cyst. *Turk J Gastroenterol* 2004; 15: 120-1.
- Takiff H, Calabria R, Yin L, Stabile BE. Mesenteric cysts and intra-abdominal cystic lymphangiomas. *Arch Surg* 1985; 120: 1266-9.
- Miliaras S, Trygonis S, Papandoniou A, et al. Mesenteric cyst of the descending colon: report of a case. *Acta Chir Belg* 2006; 106: 714-6.
- Liew SC, Glenn DC, Storey DW. Mesenteric cyst. *Aust N Z J Surg* 1994; 64: 741-4.
- Traubici J, Daneman A, Wales P, et al. Mesenteric lymphatic malformation associated with small-bowel volvulus—two cases and a review of the literature. *Pediatr Radiol* 2002; 32: 362-5.
- Steyaert H, Guitard J, Moscovici J, et al. Abdominal cystic lymphangioma in children: benign lesions that can have a proliferative course. *J Pediatr Surg* 1996; 31: 677-80.
- Tsukamoto T, Tanaka S, Yamamoto T, et al. Laparoscopic excision of a retroperitoneal cystic lymphangioma: report of a case. *Surg Today* 2003; 33: 142-4.