

# Hematoma of the falciform ligament: A rare cause of acute abdomen

Serkan SARI<sup>1</sup>, Feyzullah ERSÖZ<sup>1</sup>, Mehmet Emin GÜNEŞ<sup>1</sup>, Esra PAŞAOĞLU<sup>2</sup>, Soykan ARIKAN<sup>1</sup>

Departments of <sup>1</sup>General Surgery and <sup>2</sup>Pathology, Istanbul Research and Training Hospital, Istanbul

*Hematoma or abscess of the liver ligaments is extremely rare, and hematoma of the falciform ligament has been sporadically reported. We report the case of a 70-year-old female who presented with a three-day history of right upper quadrant abdominal pain, fever and nausea. With a preoperative diagnosis of probable perforated acalculous cholecystitis, the patient underwent emergency surgery. Hematoma of the falciform ligament was found. Wide excision of the falciform ligament including the hematoma with abscess was performed. Although pathology of the falciform ligament is rare, it should be included in the differential diagnosis of acute abdomen, especially in the case of antiaggregant drug usage.*

**Key words:** Falciform ligament, acute abdomen, warfarin

## Akut batın sendromunun nadir bir nedeni: Falsiform ligament hematomu

*Karaciğer bağlarının hematomu veya absesi son derece nadir görülmektedir. Falsiform ligament hematomu da literatürde birkaç adet bildirilmiştir. Üç gündür devam eden sağ üst kadran ağrısı, ateş ve kusma şikayeti ile başvuran 70 yaşında bayan hastayı sunduk. Perfore akalküloz kolesistit ön tanısı ile hasta acil olarak ameliyata alındı. Ameliyatta falsiform ligament hematomu saptandı. Abse odakları da içeren falsiform ligamenti hematomu, geniş olarak eksize edildi. Falsiform ligament patolojisi son derece nadir de görülse, antiagregan kullanımı anamnezi olan akut batın sendromlu hastada, etyolojide akla getirilmelidir.*

**Anahtar kelimeler:** Falciform ligament, acute abdomen, warfarin

## INTRODUCTION

Few cases of falciform ligament hematoma have been reported. This implies that the pathology of falciform ligament hematoma and abscess is poorly understood, and many surgeons may be unable to recognize it when encountered. We therefore report a case of falciform ligament hematoma secondary to warfarin medication.

## CASE REPORT

A 70-year-old female was admitted to the hospital with a three-day history of right upper quadrant pain, fever and nausea. There was no history of jaundice. Her medical history revealed that she was

prescribed warfarin and oral anti-diabetic drug for cerebrovascular accident and diabetes mellitus. There was no history of abdominal surgery or abdominal trauma. On physical examination, she was found to have a 4 cm, painful right upper quadrant mass. Her body temperature was 38.2°C. Results of laboratory studies showed: white blood cell count, 12,500/ml; serum aspartate aminotransferase (AST), 85 IU/L; serum alanine aminotransferase (ALT), 85 IU/L; serum glucose, 160 mg/dl; international normalized ratio (INR) 1.99; and prothrombin time, 23.5 seconds. On palpation, there was right upper quadrant abdominal tenderness and guarding with peritoneal irritation.

**Address for correspondence:** Serkan SARI  
Istanbul Research and Training Hospital, Department of General Surgery, Istanbul, Turkey  
E-mail: drserkansari@yahoo.com

**Manuscript received:** 27.10.2009 **Accepted:** 26.02.2010

*Turk J Gastroenterol* 2011; 22 (2): 213-215  
doi: 10.4318/tjg.2011.0196

Abdominal radiography was unremarkable. Ultrasonography showed a hydropic acalculous gallbladder with pericholecystic fluid, thickened gallbladder wall and a small amount of fluid in the right upper quadrant.

These imaging findings suggested acalculous cholecystitis, and the patient was hospitalized for intravenous antibiotic therapy. In the serial ultrasonography, an increase in the pericholecystic fluid was determined, and white blood cell count was increased, at 24,000 mm<sup>3</sup>. Since ultrasonographic and laboratory findings suggested gallbladder perforation, the patient underwent emergency surgery.

Surgical exploration confirmed a large hematoma measuring 10 x 7 cm arising from the thickened falciform ligament (Figure 1). The gallbladder was normal. A hemorrhagic mass was found starting from the umbilicus up to the hepatic hilum. The ligament was resected in total (Figure 2). The postoperative course was satisfactory. Histopathology of the lesion showed necrotic fat consistent with hemorrhagic infarction (Figure 3).

## DISCUSSION

Falciform ligament hematoma is a rare clinical entity, with only a few reports noted in the literature (1,2). The diagnosis is often made surgically after palpation of a mass or complaints of right upper quadrant abdominal pain.

The falciform ligament is the embryologic remnant of the ventral mesentery, and marks the separation of the most caudal part of the left lobe of the liver into medial and lateral segments. The ligament is composed of two mesothelial layers, within which lie the ligamentum teres hepatis (obliterated left umbilical vein), paraumbilical veins, muscular fibers, and a variable amount of adipose tissue (3).

Oral anticoagulants are an established treatment modality in the prophylaxis of thromboembolic events in various clinical scenarios. The use of warfarin for ischemic stroke prevention in patients with atrial fibrillation has increased dramatically following favorable results from randomized

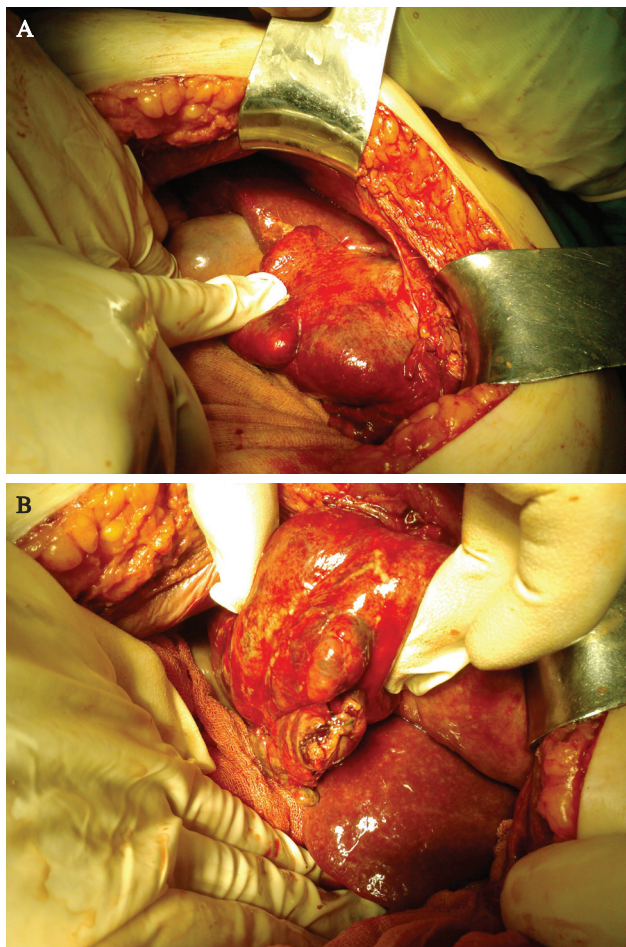


Figure 1 A-B. Hematoma of the falciform ligament.

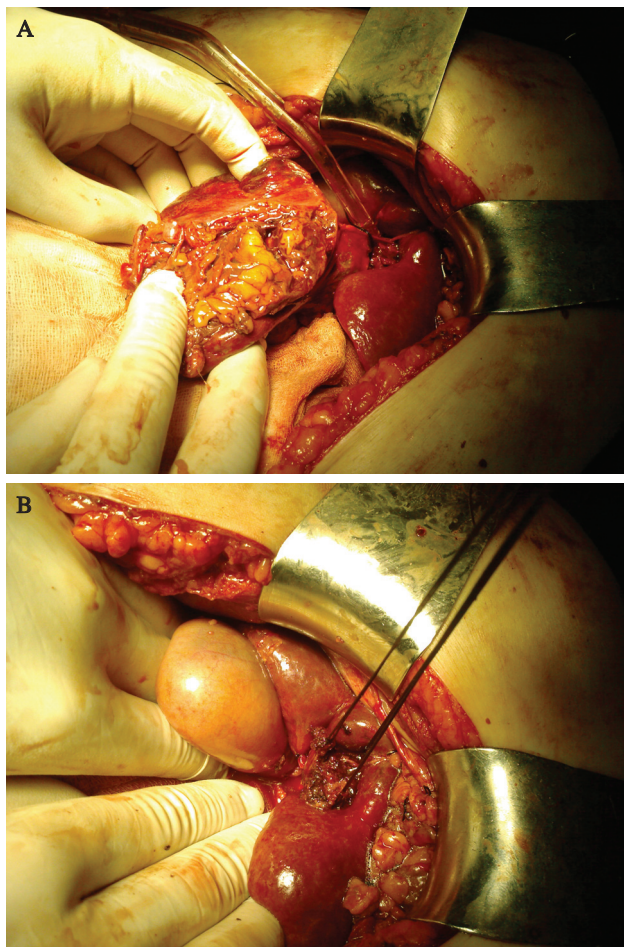
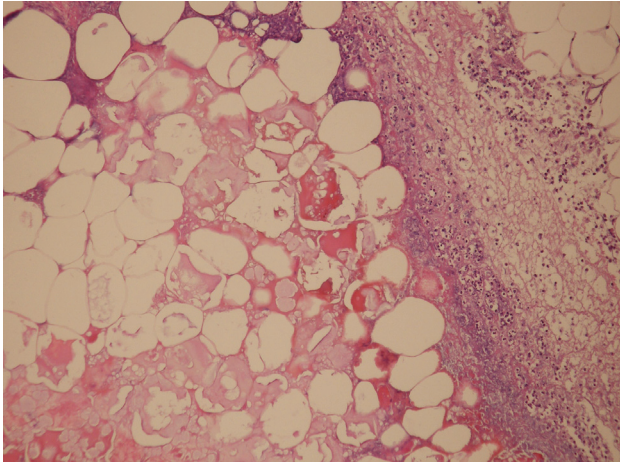


Figure 2 A-B. Total excision of the falciform ligament and normal gallbladder.



**Figure 3.** Fat necrosis in the center of the field surrounded by acute suppurative inflammation composed of neutrophils and necrotic debris (HE X100).

controlled trials in the 1990s. This is likely to increase the frequency of warfarin-associated complications. Bleeding is an adverse effect of warfarin therapy, and such episodes are generally inconse-

quential. Spontaneous hemorrhage in the falciform ligament is extremely rare (4,5).

The exact cause of hematoma or abscess is unclear. Hematoma of the falciform ligament evokes various signs. Nausea, palpable mass and indigestion have been reported as presenting complaints. Pain can be related to hemorrhage into the ligament, or torsion with strangulation causes acute symptoms (6,7). The presence of right upper quadrant abdominal pain, epigastric tenderness, fever, leukocytosis, and a mass in the anterior abdomen should raise suspicion of falciform ligament hematoma. Its treatment consists of excision of the ligament. Complete excision of the lesion is curative. Depending on the surgeon's expertise, the patient's condition and the severity and extent of disease, either open or laparoscopic surgery may be performed.

In conclusion, although pathology of the falciform ligament is rare, it should be included in the differential diagnosis of acute abdomen, especially in the case of antiaggregant drug usage.

## REFERENCES

1. Losanoff JE, Kjossev KT. Isolated gangrene of the round and falciform liver ligaments: a rare cause of peritonitis: case report and review of the world literature. *Am Surg* 2002; 68: 751-5.
2. Lloyd T. Primary torsion of the falciform ligament: computed tomography and ultrasound findings. *Australas Radiol* 2006; 50: 252-4.
3. Li XP, Xu DC, Tan HY, Li CL. Anatomical study on the morphology and blood supply of the falciform ligament and its clinical significance. *Surg Radiol Anat* 2004; 26: 106-9.
4. Aguilar MI, Hart RG, Kase CS, et al. Treatment of warfarin-associated intracerebral hemorrhage: literature review and expert opinion. *Mayo Clin Proc* 2007; 82: 82-92.
5. Fang MC, Go AS, Chang Y, et al. Death and disability from warfarin-associated intracranial and extracranial hemorrhages. *Am J Med* 2007; 120: 700-5.
6. Enterline DS, Rauch RE, Silverman PM, et al. Cyst of the falciform ligament of the liver. *AJR* 1984; 142: 327-8.
7. Lagoudianakis EE, Michalopoulos N, Markogiannakis H, et al. A symptomatic cyst of the ligamentum teres of the liver: a case report. *World J Gastroenterol* 2008; 14: 3266-8.