

McArdle's disease: case report and review of the literature

McArdle hastalığı: olgu sunumu ve literatürün gözden geçirilmesi

Ahmet TÜZÜN¹, Ahmet ERDİL¹, Sait BAĞCI¹, Erol BOLU², Önder ÖNGÜRÜ³, İsmail KURT Pharm⁴, Zeki YEŞİLOVA¹, Kemal DAĞALP¹

Gülhane Military Medical Academy, Departments of Gastroenterology¹, Endocrinology², Pathology³ and Biochemistry⁴, Ankara

McArdle's disease, or myophosphorylase deficiency, is one of the most common muscle glycogenoses and typically presents in childhood or adolescence with exercise intolerance, myalgia, myoglobinuria, and cramps in the exercising muscle.

We report the case of a 21-year-old male patient with liver enzyme elevation who had a history of weakness, exercise intolerance, and muscle cramps since childhood. His sister (a three-year-old) suffered from similar symptoms. Laboratory results showed that serum creatinine phosphokinase levels were elevated serum lactate did not rise on ischemic exercise testing, while muscle biopsy showed subsarcolemmal and intermyofibrillar periodic acid schiff-positive vacuoles filled with glycogen. This case report underlines the importance of taking into account rare metabolic diseases such as muscle glycogenoses in the evaluation of patients with elevated liver enzymes.

Key words: McArdle's disease, myophosphorylase deficiency, glycogen storage disease type V.

McArdle hastalığı veya myofosforilaz eksikliği en yaygın kas glikojenozlarından biridir ve tipik olarak çocukluk veya adolesan dönemde egzersiz intoleransı, myalji, myoglobinüri ve egzersiz yapılan kaslarda kramplar ile kendini gösterir. Bu makalede biz karaciğer enzim yüksekliği olan 21 yaşında erkek bir hasta tanımladık. Hastamızın çocukluğundan beri devam eden güçsüzlük, egzersiz intoleransı ve kas krampları mevcut idi. 3 yaşındaki kız kardeşinin de benzer yakınmaları mevcut idi. Laboratuvar testlerinde serum kreatinin fosfokinaz düzeyleri yüksek idi, iskemik egzersiz testinde serum laktatı yükselmedi ve kas biyopsisinde subsarkolemmal ve intermyofibriller glikojenle dolu periodic acid schiff-pozitif vakuoller saptandı. Sonuç olarak karaciğer enzim yüksekliği olan hastalarda kas glikojenozları gibi nadir metabolik hastalıklar da düşünülmelidir.

Anahtar kelimeler: McArdle hastalığı, myofosforilaz eksikliği, glikojen depo hastalığı tip V.

INTRODUCTION

Prolonged elevations of serum alanine aminotransferase (ALT) and aspartate aminotransferase (AST) are often attributed to hepatic diseases. However, these enzymes are also present in a variety of extrahepatic tissues, including skeletal muscle. McArdle disease (type V glycogen storage disease) is an uncommon hereditary metabolic disease characterized by muscle phosphorylase deficiency (1). Myophosphorylase, an important enzyme of carbohydrate metabolism, converts glycogen to glucose-1-phosphate (2). Deficiency of this enzyme in muscle limits ATP generation by glycogenolysis and results in glycogen accumulation (3).

Myophosphorylase deficiency is transmitted as a

recessive autosomal trait (4). However, a few families with an autosomal dominant mode of inheritance have also been documented (5). The gene for myophosphorylase has been cloned, sequenced, and localized to chromosome 11q13 (2,6). Although symptoms usually start in childhood or adolescence (4), there are occasional reports of individuals diagnosed in late adulthood, who were relatively asymptomatic in their youth (7-9). Patients experience exercise intolerance with premature fatigue, myalgia, and cramps (contractures) in response to exercise (1,10). Electromograms are often normal between attacks of myoglobinuria. Electrical silence usually occurs when voluntary activity is followed by

a cramp (11). The severity and duration of the symptoms are related to the amount of exercise and symptoms are relieved by rest (9).

Elevated serum levels of cytoplasmic muscle enzymes and myoglobinuria occur after particularly intense and/or prolonged physical activity. Myoglobinuria occurs in about half of the cases of McArdle's disease (4,9,11) and about half of these patients have acute renal failure (12).

The diagnosis is established by the lack of elevation of serum lactate after exercise, and by histochemical demonstration of an absence of phosphorylase activity in a muscle biopsy specimen. Muscle pathology often shows subsarcolemmal and intermyofibrillar vacuoles filled with glycogen.

In this study, we report a patient with McArdle's Disease who presented with raised serum aminotransaminases. This case report emphasises the importance of considering muscle disease in the differential diagnosis of raised serum aminotransaminases, as it may negate the need for invasive investigations such as liver biopsy.

CASE REPORT

A 21-year-old male patient was admitted with liver enzyme elevation. He had a history of weakness, exercise intolerance, and muscle cramps (contractures) since childhood which generally occurred after exercise and improved a little with rest. There was no history of dark-colored urine. He reported that no diagnosis could be made and no cause for the raised liver enzymes had been found despite repeated medical investigations. His sister (a three-year-old) was suffering from similar symptoms. His mother had diabetes mellitus while his father had bronchitis and heart disease. The patient presented with no neurological abnormalities including muscle atrophy and weakness. Gower's sign was negative. Physical examination was entirely normal.

Initially elevated aspartate aminotransferase (AST) (94 U/L) and alanine aminotransferase (ALT) (93 U/L) values on admission decreased to levels of 54 U/L and 32 U/L respectively within four weeks. However, elevated levels of creatinine phosphokinase (CPK) and lactic dehydrogenase (LDH) continued, which prompted us to consider whether hypertransaminasemia was related to an extrahepatic cause.

Normal laboratory investigations included com-

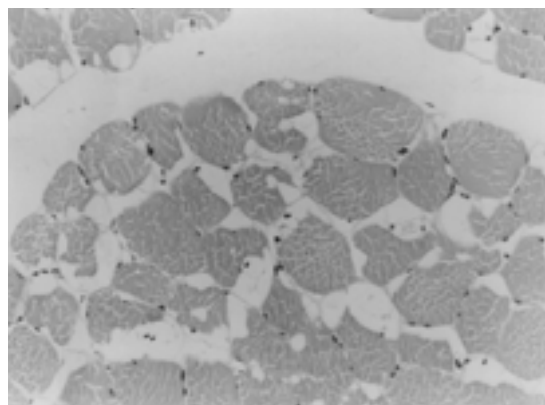


Figure 1. Subsarcolemmal vacuoles are seen in many of the myofibrils (Hematoxylen-Eozin, X 200).

plete blood cell count, chest roentgenogram, ESR, creatinine, urea, sodium, potassium, uric acid, serum calcium, glucose, cholesterol, triglyceride, direct bilirubin, indirect bilirubin, alkaline phosphatase, g-glutamyl transpeptidase, amylase, total protein, albumin, serum copper, ferritin, peripheral blood smear, urinalysis, stool analysis, ANA, Anti ds DNA, Anti Sm Ab, HBsAg, AntiHCV, HCV RNA, Anti-HIV, Rubella IgM, Rubeola IgM, Toxoplasma IgM, Toxoplasma IgG, Anti RNP, Anti Scl-70, Anti Jo-1, ACA IgG, ACA IgM, p ANCA, c ANCA, and thyroid function tests. Abnormal serum chemistry was as follows: CPK 5706 U/L (31-221), AST 94 U/L (8-40), ALT 93 U/L (5-40), LDH 351 U/L (91-232), Rubella IgG 211 (0-20), Rubeola IgG 2.9 (0-1). Serum myoglobin and myoglobinuria could not be investigated due to technical problems. Upper abdominal ultrasonography was normal.

The findings defined in the EMG were considered nonspecific for myopathy. Later, a forearm ischemic exercise (lactate) test was carried out as described by Munsat (13). Serum lactic acid levels remained unchanged after the ischemic forearm exercise test, but ammonia levels were markedly raised (basal 34 and maximum 229 mmol/L). Myoadenilate deaminase and respiratory chain enzyme deficiency were excluded as a result of these findings. All data was thought to support the presence of glycogen storage disease involving striated muscle.

A muscle biopsy was taken from the right thigh region. Variation of the diameter of fibers, random atrophy, hypertrophy and occasional internal

nuclei were observed. Subsarcolemmal vacuolisations were present in many of the myofibrils (Figure-1). Accumulation Periodic Acid Schiff (PAS) positive substance was noted in some of the these vacuoles. Myocyte necrosis and fibrosis were not seen. The histopathological findings were found to be compatible with the diagnosis of Glycogen storage disease (Type V myopathy).

DISCUSSION

Persistent hypertransaminasemia unrelated to hepatic viral infection is a common cause for referral to the hepatologist. However, these enzymes are also present in a variety of extrahepatic tissues, including skeletal muscle. There have been occasional reports in which elevated serum aminotransferase activities have led to the diagnosis of suspected muscle disease (14).

As many patients know their exercise capacity, they limit their exercise before appearance of symptoms. In our patient, there was a history of weakness, exercise intolerance, muscle cramps and pain since childhood, with of the severity and duration of symptoms being related to the amount of exercise, thus the patient had never physically exerted himself greatly. Transaminase levels of our patient were therefore only slightly higher than normal. Determination of increased CPK levels suggested that elevation of transaminases may have an extrahepatic cause.

Serum aminotransferase measurements are often included in blood screening panels performed for a variety of reasons. In contrast, serum CPK measurement is infrequently included in such screening although it is the most useful marker of muscle disease. A careful physical examination in addition to CPK determination will identify the majority of these cases (1,11). Indeed, the diagnosis in our patient was made by muscle biopsy and forearm ischemic exercise test without any need for liver biopsy. It was the absence of a rise in serum lactate levels in the forearm ischemic exercise test and observation of subsarcolemmal and

intermyofibrillar PAS-positive vacuoles filled with glycogen seen in the muscle biopsy material in particular that led to consideration of McArdle's disease. As it is known that McArdle's disease is basically a disease of skeletal muscle, it was not considered to be necessary to perform any invasive procedure such as liver biopsy.

From the clinical point of view, Mc Ardle's disease and Tarui disease (muscle phosphofructokinase deficiency, Type VII glycogen storage disease) may have similarities. Most patients with muscle phosphofructokinase deficiency may also have moderate hemolytic anemia, arthritis and clinical manifestations of gout. Hyperuricemia is common and becomes more marked after exercise (1). Our patient had neither clinical manifestations of gout nor arthritis; complete blood cell count, serum urate and bilirubin levels were all within normal ranges whenever we checked them.

Due to its rarity, McArdle's disease can easily be missed by physicians and sometimes the diagnosis can not be made until renal failure develops (12). Likewise, our patient had a history of symptoms since childhood but was only diagnosed during his military service, although his renal functions were normal. Many life-long sufferers are finally diagnosed in their 50's and 60's (8,9). It is now believed that many cases may go unnoticed.

In conclusion, this case report demonstrates that occult muscle diseases should be taken into account in the evaluation of patients with unexplained chronic hypertransaminasemia. Measurement of serum creatine kinase activity and muscle biopsy should be performed at an early stage for the correct diagnosis of McArdle's disease. Identification of subjects with this disease is important since they may benefit significantly from a high-protein diet (15), avoidance of certain physical activities and genetic counseling. Early diagnosis will also make it possible to avoid exercise-induced rhabdomyolysis and acute renal failure.

REFERENCES

1. Tunçbay T, Tunçbay E. Metabolik miyopatiler. *Nöromusküler Hastalıklar Cilt 2. Ege Üniversitesi Basımevi, Bornova-İzmir.* 2000; 815-46.
2. Tsujino S, Shanske S, Nonaka I, DiMauro S. The molecular genetic basis of myophosphorylase deficiency (McArdle's disease). *Muscle Nerve* 1995; 3: 23-7.
3. Tsujino S, Shanske S, DiMauro S. Molecular genetic heterogeneity of myophosphorylase deficiency (McArdle's disease). *N Engl J Med* 1993; 329: 241-5.
4. El-Schahawi M, Tsujino S, Shanske S, DiMauro S. Diagnosis of McArdle's disease by molecular genetic analysis of blood. *Neurology* 1996; 47: 579-80.
5. Chui LA, Munsat TL. Dominant inheritance of McArdle's syndrome. *Arch Neurol* 1976; 33: 636-41.

6. Lebo RV, Gorin F, Fletterick RJ, et al. High-resolution chromosome sorting and DNA spot-blot analysis assign McArdle's syndrome to chromosome 11. *Science* 1984; 225: 57-9.
7. Pourmand R, Sanders DB, Corwin HM. Late-onset McArdle's disease with unusual electromyographic findings. *Arch Neurol* 1983; 40: 374-7.
8. Wolfe GI, Baker NS, Haller RG, et al. McArdle's disease presenting with asymmetric, late-onset arm weakness. *Muscle Nerve* 2000; 23: 641-5.
9. Harris RA, Dowben RM. McArdle's disease in an elderly woman. *South Med J* 1985; 78: 191-3.
10. Lopez-Pison J, Munoz-Albillos MS, Boudet-Garcia A, et al. McArdle's disease in a 14-year-old girl with fatigability and raised muscle enzymes. *Rev Neurol* 2000;30: 932-4.
11. DiMauro S, Bresolin N. Phosphorylase deficiency. In: Engel AG, Franzini-Armstrong C, Editors. *Myology*. 2nd ed. New York. McGraw-Hill, 1994: 1585-1601.
12. Bonnardeaux A, Querin S, Charron L. McArdle's disease presenting with acute renal failure. *Nephron* 1991; 59: 696-7.
13. Munsat TL. A standardized forearm ischemic exercise test. *Neurology* 1970; 20: 1171-8.
14. Morse RP, Rosman NP. Diagnosis of occult muscular dystrophy: Importance of the chance finding of elevated serum aminotransferase activities. *J Pediatr* 1993; 122: 254-6.
15. Slonim AE, Goans PJ. Myopathy in McArdle's syndrome: improvement with a high-protein diet. *N Engl J Med* 1985; 312: 355-9.