



A rare entity: Cystic lymphangioma of the duodenal bulb and successful treatment with polypectomy in an adult patient

Zahide Şimşek¹, Barış Yılmaz¹, Bora Aktaş¹, Ata Türker Arıkök², Şahin Çoban¹

¹Department of Gastroenterology, Dışkapı Yıldırım Beyazıt Educational and Research Hospital, Ankara, Turkey

²Department of Pathology, Dışkapı Yıldırım Beyazıt Educational and Research Hospital, Ankara, Turkey

ABSTRACT

Gastrointestinal tract lymphangiomas are extremely rarely seen. Here, we present the first case of lymphangioma of the duodenal bulb diagnosed with a deep bite on a bite endoscopic biopsy and treated with polypectomy.

Keywords: Duodenal disease, lymphangioma, adult

INTRODUCTION

Lymphangiomas are uncommon benign vascular tumors that occur mostly in the head, neck, or axillary region and are generally congenital, and they result from developmental failure of the lymphatic system (1). Gastrointestinal tract lymphangiomas are extremely rarely seen and can be found in the esophagus, stomach, jejunum, and colon (2). To our best knowledge, duodenum lymphangioma in the bulb has not been reported before in the literature. Herein, we present the first case of lymphangioma of the duodenal bulb diagnosed with a deep bite on a bite endoscopic biopsy and treated with polypectomy.

CASE PRESENTATION

A 34-year-old male was referred to our clinic for endoscopic examination because of complaints of chronic intermittent upper abdominal pain for 2 years. Physical examination and laboratory data were in the normal limits. Endoscopic examination revealed a polypoid lesion 1 cm in diameter on the duodenal bulb, which changed shape with alterations in the patient's position and showed a pillow sign defined endoscopically; compressibility of the tumor is a characteristic sign. The lesion was covered with lymphatic drainage from distended mucosal vessels. It was soft and easily deformed by pressure (Figure 1). Multiple deep bites on bite biopsies were obtained from the lesion. Histopathologic

examination showed multiple dilated lymphatic channels lined by endothelial cells (Figure 2). Therefore, the lesion was diagnosed as a lymphangioma. Then, it was resected by polypectomy snare without any complications (Figure 3). Some lymphatic leakage was observed while performing the polypectomy. The complaints of the patient were resolved in a short time after polypectomy. The patient's general status was good at the 6-month follow-up.

DISCUSSION

Lymphangioma is a benign tumor, and no cases of malignant transformation have yet been reported. Patients usually present with absent or nonspecific symptoms, including abdominal pain, sour regurgitation, nausea, and vomiting. When severe symptoms or complications, such as bleeding, ileus, intussusceptions, or protein-losing enteropathy are present, surgical or endoscopic resection of lymphangioma may be necessary (3). Endoscopic polypectomy is the recommended method in uncomplicated cases to avoid unnecessary surgery.

Lymphangioma of the duodenal bulb should be kept in mind as a rare clinical condition in adult patients presenting with chronic upper abdominal pain, and it may be removed with endoscopic resection.

Address for Correspondence: Barış Yılmaz, Department of Gastroenterology, Dışkapı Yıldırım Beyazıt Educational and Research Hospital, Ankara, Turkey

E-mail: dryilmazb@gmail.com

Received: 14.2.2014 **Accepted:** 8.4.2012

© Copyright 2014 by The Turkish Society of Gastroenterology • Available online at www.turkjgastroenterol.org • DOI: 10.5152/tjg.2014.3191

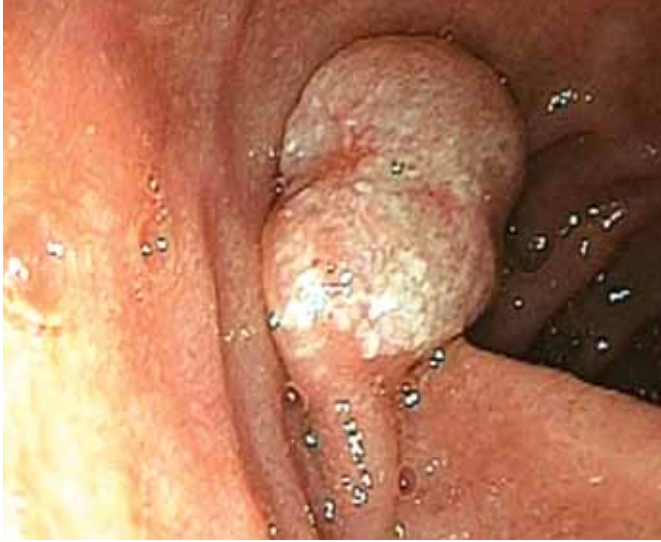

Figure 1. Endoscopic view of lymphangioma of the duodenum bulb.

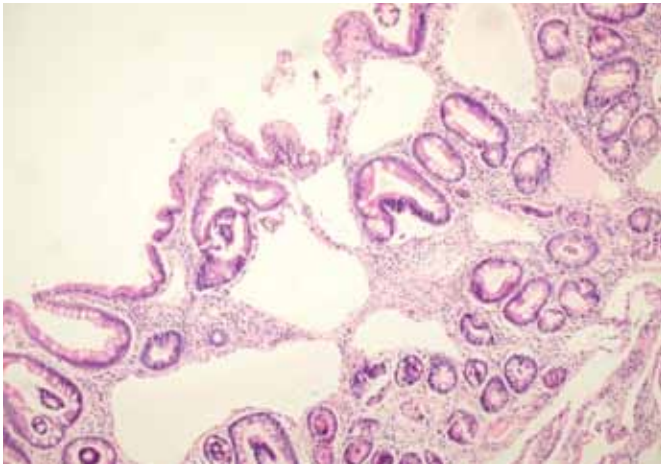


Figure 2. Dilated cystic lymphatic vessels lined by endothelial cells (hematoxylin-eosin).

Ethics Committee Approval: N/A.

Informed Consent: Written informed consent was obtained from patient who participated in this case.

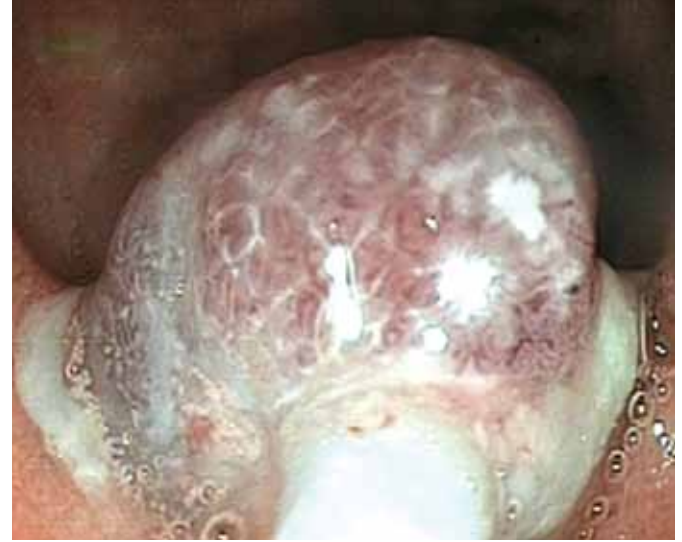

Figure 3. Endoscopic view of the lesion resected by polypectomy snare.

Peer-review: Externally peer-reviewed.

Author contributions: Concept - Z.Ş., B.Y.; Design - Z.Ş., B.Y.; Supervision - Ş.Ç.; Resource - B.A.; Materials - A.T.A.; Data Collection&/or Processing - Z.Ş., B.Y.; Analysis&/or Interpretation - Z.Ş., B.Y.; Literature Search - Z.Ş., B.Y.; Writing - Z.Ş., B.Y.; Critical Reviews - Ş.Ç.

Conflict of Interest: No conflict of interest was declared by the authors.

Financial Disclosure: The authors declared that this study has received no financial support.

REFERENCES

1. Zhu H, Wu ZY, Lin XZ, Shi B, Upadhyaya M, Chen K. Gastrointestinal tract lymphangiomas: findings at CT and endoscopic imaging with histopathologic correlation. *Abdom Imaging* 2008; 33: 662-8. [\[CrossRef\]](#)
2. Karaca G, Koçak E, Pekici R, Güler O, Köklü S. A rare cause of acute appendicitis: Cystic lymphangioma. *Am Surg* 2010; 76: E150-51.
3. Kunitura T, Inagaki T, Hayashi R, Katou H, Iwaku K, Morohoshi T. A case of multiple colonic lymphangiomas causing intussusception. *J Gastroenterol* 2005; 40: 316-8. [\[CrossRef\]](#)