

The hepatoprotective effects of dihydromyrcenol and geranyl formate in an experimental model of acute hepatic injury induced by the use of carbon tetrachloride

İrfan BAYRAM¹, Remzi ERTEN², Yasemin BAYRAM³, Gülay BULUT⁴, Hanefi ÖZBEK⁵

Department of ¹Pathology, Yüzüncü Yıl University, School of Medicine, Van

Department of ²Pathology, Maternity and Children's Hospital, Siirt

Department of ³Microbiology, Van Training and Research Hospital, Van

Department of ⁴Pathology, Yüksek İhtisas Hospital, Van

⁵The Ministry of Health, General Directorate of Pharmaceuticals and Pharmacy, Ankara

Background/aims: We aimed to investigate the hepatoprotective effects of dihydromyrcenol and geranyl formate extracted from the *Vitis vinifera* L. plant in a rat model of acute hepatic injury induced by carbon tetrachloride. **Methods:** The study was performed on 54 Sprague-Dawley male rats. The animals were divided into 9 study groups with 6 rats in each. At the end of the 7-day study period, the animals were sacrificed. The effects of dihydromyrcenol and geranyl formate on hepatic injury were evaluated based on the comparisons of the changes in the weight, serum levels of alanine aminotransferase and aspartate aminotransferase, and histopathological changes in the liver. **Results:** Dihydromyrcenol significantly reduced the carbon tetrachloride-associated ballooning degeneration and apoptotic cell counts; this reduction was moderate with low doses of geranyl formate, while no reductions were observed with high doses of geranyl formate. The changes in the alanine aminotransferase and aspartate aminotransferase levels were in accordance with these findings. **Conclusions:** It can be concluded that in an experimental model of acute hepatic injury induced by carbon tetrachloride, dihydromyrcenol presents a hepatoprotective effect, while geranyl formate presents partial hepatoprotective effects at low doses and no hepatoprotective effects at high doses.

Key words: Acute hepatic injury, dihydromyrcenol, geranyl formate, hepatoprotective activity, carbon tetrachloride, *Vitis vinifera* L., rat

Dihydromyrcenol ve geranyl formate'in sıçanlarda karbon tetraklorür ile oluşturulmuş akut karaciğer hasarı modelinde hepatoprotektif etkileri

Amaç: *Vitis vinifera* L. bitkisinde bulunan dihydromyrcenol ve geranyl formate'in sıçanlarda karbon tetraklorür ile oluşturulmuş akut karaciğer hasarı modelinde hepatoprotektif etkilerinin araştırılması amaçlandı. **Yöntem:** Çalışmada, Sprague-Dawley cinsi 54 adet sıçan kullanıldı. Dokuz çalışma grubu oluşturuldu (n=6) ve yedi günlük çalışma sonrası sıçanlar sakrifiye edildi. Dihydromyrcenol ve geranyl formate'in akut karaciğer hasarı üzerindeki etkileri çalışma gruplarının vücut ağırlığı değişimleri, serum alanin aminotransferaz ve aspartat aminotransferaz seviyeleri ve karaciğerdeki histopatolojik değişiklikler karşılaştırılarak değerlendirildi. **Bulgular:** Çalışmada karbon tetraklorür'ün etkisine bağlı artan balon dejenerasyonu ve apoptotik hücre sayısının; dihydromyrcenol ile anlamlı şekilde azaldığı ve geranyl formate'in düşük dozları ile kısmen azaldığı ancak geranyl formate'in yüksek dozu ile azalmadığı görüldü. Ayrıca alanin aminotransferaz ve aspartat aminotransferaz seviyelerindeki değişiklikler de bu bulgular ile uyumluluk gösterdi. **Sonuç:** Karbon tetraklorür ile oluşturulan deneysel akut karaciğer hasarında, dihydromyrcenol'un hepatoprotektif etkisinin olduğu ve geranyl formate'in ise düşük dozlarda kısmen hepatoprotektif etkisinin olduğu ancak yüksek dozlarda hepatoprotektif etkisinin olmadığı söylenebilir.

Anahtar kelimeler: Akut karaciğer hasarı, dihydromyrcenol, geranyl formate, hepatoprotektif aktivite, karbon tetraklorür, *Vitis vinifera* L., sıçan

INTRODUCTION

Hepatic injury may occur due to numerous reasons, some of which are highly widespread (1,2). Hepatic injury can be prevented with the use of free radical scavengers and agents that prevent lipid peroxidation (3). Various forms of hepatic injury occur due to oxidative stress followed by the production of free radicals (4-7). Carbon tetrachloride (CCl_4), one of the substances that damages the liver, promotes the release of free radicals. This effect is formed through the following stages: Dehalogenation of the CCl_4 molecule to trichloromethyl ($\text{CCl}_3\cdot$) free radical is catalyzed by cytochrome-P450. By addition of oxygen molecules to $\text{CCl}_3\cdot$, the trichloromethyl peroxy ($\text{CCl}_3\text{O}_2\cdot$) radical is formed. This reactive compound initiates lipid peroxidation after a few stages. Lipid peroxidation and the resultant toxic lipid peroxidation products induce membrane damage. If the membrane damage is not prevented, cell death occurs (4,8-10).

Geranyl formate (GF) is a monoterpene ester (11) and a rose-like odor compound (12), and is reported to be found in geranium oils (13,14). Dihydromyrcenol (DM) is a monoterpene alcohol (11) and a widely used fragrance ingredient with a strong fresh-lime cologne odor (15). In their study, Rocha et al. (11) reported that *Vitis vinifera* L. cv. 'Fernão-Pires' white grape was found to contain 56 monoterpenoids including DM and GF. In their study, Orhan et al. (16) showed the hepatoprotective effects of ethanol extracts of *Vitis vinifera* L. (VVL) leaves on CCl_4 -induced hepatotoxicity and suggested that further studies should be conducted to determine the effects of the active compounds of the VVL plant. To our knowledge, there are a limited number of studies conducted with DM and/or GF, but no studies evaluated their effects on the liver.

The present study aimed to investigate the hepatoprotective effects of DM and GF extracted from the VVL plant in a rat model of acute hepatic injury induced by CCl_4 and to make contributions to the existing experimental and clinical data.

MATERIALS AND METHODS

Chemicals

Olive oil was obtained from Fluka (Steinheim, Germany); CCl_4 was obtained from Merck (KgaA, 64271 Darmstadt, Germany); DM was obtained from Sigma-Aldrich (196428, Germany), and GF was obtained from Sigma-Aldrich (W251402, FCC, Kosher, Germany).

Experimental Animals

In the present study, 54 Sprague-Dawley male rats (weight: 150 and 250 g; age: 16-20 weeks) obtained from the Neuroscience Research Animals Unit of Yuzuncu Yil University Faculty of Medicine were used. Prior to the experimental procedure, the animals were randomly allocated into 9 groups with 6 rats in each and placed in plastic cages, where they were kept under room temperature ($22\pm 2^\circ\text{C}$) and fed standard pellet rat chow (Van Food Industry) and provided with tap water.

The study was conducted at the Neuroscience Research Animals Unit of Yuzuncu Yil University Medical Faculty, upon the approval of the Ethics Committee of Yuzuncu Yil University Medical Faculty (date: 09.20.2005, reg. no: 2005/06-03) and Neuroscience Research Unit of the same university (date: 10.31.2007, reg. no: 2007/16).

Study Groups

The animals were randomly divided into 9 groups with 6 rats in each as follows: Group 1 (controls): the rats were injected with 0.2 ml serum physiologic (SP) (17,18); Group 2 (Olive oil): the rats were injected with olive oil at a dose of 0.8 ml/kg (17,18); Group 3 (CCl_4): the rats were injected with 0.8 ml/kg CCl_4 :Olive oil (1:1) mixture (17,19); Group 4 (DM-1): 0.8 ml/kg CCl_4 :Olive oil (1:1) was injected into the right abdominal cavity and 0.05 ml/kg DM:Olive oil (1:9) was injected into the left abdominal cavity using different injectors for each side; Group 5 (DM-2): 0.8 ml/kg CCl_4 :Olive oil (1:1) was injected into the right abdominal cavity, and 0.1 ml/kg DM:Olive oil (1:9) was injected into the left abdominal cavity using different injectors for each side; Group 6 (DM-3): 0.8 ml/kg CCl_4 :Olive oil (1:1) was injected into the right abdominal cavity, and 0.2 ml/kg DM:Olive oil (1:9) into the left abdominal cavity using different injectors for each side; Group 7 (GF-1): 0.8 ml/kg CCl_4 :Olive oil (1:1) was injected into the right abdominal cavity, and 0.05 ml/kg GF:Olive oil (1:9) was injected into the left abdominal cavity using different injectors for each side; Group 8 (GF-2): 0.8 ml/kg CCl_4 :Olive oil (1:1) was injected into the right abdominal cavity, and 0.1 ml/kg GF:Olive oil (1:9) was injected into the left abdominal cavity using different injectors for each side; and Group 9 (GF-3): 0.8 ml/kg CCl_4 :Olive oil (1:1) was injected into the right abdominal cavity, and 0.2 ml/kg GF:Olive oil (1:9) was injected into the left abdominal cavity using different injectors for each side.

All injections were performed intraperitoneally (i.p.) and for 7 days.

Body Weight Monitoring

The rats were weighed daily for 8 days. The changes in their weights were compared to their baseline weights and calculated according to the following formula: Weight Change Rate = $[100 \times (\text{Weight}_n - \text{Weight}_1) / (\text{Weight}_1)]$, where Weight_n indicates the weight measurements after the first day in grams, and Weight_1 indicates the weight on the first day in grams.

Evaluation of Hepatic Function

On the 8th day, the rats were injected (i.p.) with 0.2 ml ketamine (Ketalar[®] flakon, Pfizer) for anesthesia. About 2 ml blood sample was then obtained through the intracardiac route with an injector and the serums were separated. To evaluate hepatic function, serum alanine aminotransferase (ALT) and aspartate aminotransferase (AST) levels were measured spectrophotometrically using Roche COBAS Integra[®] 800 (Roche Diagnostics, Switzerland) autoanalyzer.

Histopathological Evaluation

The rats were sacrificed by cervical dislocation, and the livers were removed. Small sections of the liver tissue were obtained to achieve better fixation and were placed into Hollande's fixative stored in light-free containers that were prepared a day before at the Pathology Laboratory of Yuzuncu Yil University Medical Faculty. The tissue samples were kept in this solution for 2 days and evaluated under a light microscope using an automatic vacuum tissue analyzer (Leica ASP[®] 300, Leica Microsystems, Germany). The tissue samples were then embedded into paraffin. Sections of 4 μm were obtained from the paraffin blocks using a rotary microtome (Leica RM[®] 2135, Leica Microsystems, Germany). The sections were then mounted onto microscope slides and stained with hematoxylin and eosin (H&E) for routine histopathological evaluation, with Masson's trichrome (MT) for the evaluation of liver fibrosis and with reticulin (silver-coating) for examination of the reticulin network.

The preparations were evaluated histopathologically at the Pathology Department of Yuzuncu Yil University Medical Faculty under a light microscope (Olympus BX50F-3, Olympus Optical Co., LTD, Japan). The preparations were photographed using Zeiss Axioplan 2 Imaging microscope (Carl Zeiss, Göttingen, Germany) with photo at-

tachment and Zeiss AxioCam HRc camera (Carl Zeiss Vision GmbH, Germany). For histopathological evaluation, 10 magnification areas (x40 objective) were randomly selected, and the mean ballooning degeneration, apoptotic hepatocytes and mitotic cells were counted. In addition, the liver tissues were evaluated for the presence of fibrosis, bridging necrosis and fat accumulation.

Statistical Analyses

The data for the animals in each group were tested using one-way ANOVA. The results were expressed as mean \pm standard deviation (SD). A *p* value <0.05 was considered statistically significant. To determine the significance of differences between the groups and the groups responsible for the difference, post-hoc Student-Newman-Keuls (SNK) test was used.

RESULTS

Follow-up of the Study Groups

None of the rats in the control, olive oil, CCl_4 , or DM groups died throughout the experiment. In GF groups, however, 1 rat from the GF-1 group, 1 rat from the GF-2 group, and 2 rats from the GF-3 group died.

Results of Weight Monitoring

Body weights of the rats were measured daily during the study. Daily changes in body weights were recorded as percentages. The changes in body weights of the study groups are presented in Table 1.

Biochemical Results

The serum ALT and AST levels of the study groups are presented in Table 2.

Table 1. Changes in body weights of the study groups

Groups (n=6 in each)	Changes in body weight (%)
Control	9.0
Olive Oil	2.0
CCl_4	-12.6
DM-1	-9.3
DM-2	-8.2
DM-3	-9.5
GF-1	-11.1
GF-2	-5.8
GF-3	-14.1

DM: Dihydromyrcenol. GF: Geranyl formate.

Histopathological Evaluation

The histopathological changes of the study groups are outlined in Table 3.

In the control and olive oil groups, no changes were observed in the hepatocytes, portal triad, sinusoidal structures, central vein, and hexagonal liver lobules. Almost no ballooning degeneration or apoptotic hepatocytes were observed, whereas there was very little mitosis (Figures 1, 2).

In the CCl₄ group, histopathological appearance showed severe ballooning degeneration, particularly in the hepatocytes around the central vein, reflecting the hepatic damage, multiple apoptotic hepatocytes with acidophilic degeneration, sporadic bridging necrosis, pleomorphism, rare mitosis, and disrupted reticulin network (Figure 3). As

compared with the control and olive oil groups, the CCl₄ group showed significantly increased ballooning degeneration and apoptotic hepatocyte count (p<0.05); however, no significant differences were observed in terms of mitotic counts (p>0.05).

Despite increased ballooning degeneration and apoptotic cell count in the DM groups, the difference was not statistically significant as compared with the control and olive oil groups (p>0.05). However, the severity of ballooning degeneration and apoptotic cell counts in the DM groups were significantly lower than those of the CCl₄ and GF groups (p<0.05). Comparisons of the DM groups with the other groups regarding mitotic counts revealed no significant differences (p>0.05). Intergroup comparisons of the DM groups with respect to ballooning degeneration, apoptotic cell counts and

Table 2. Serum levels of alanine and aspartate aminotransferases of the study groups

Groups (n=6 in each)	ALT (IU/L) (Mean±SD)	AST (IU/L) (Mean±SD)
Control	45.75±2.67	193.13±15.61
Olive oil	47.38±2.56	142.75±15.78
CCl ₄	^a 1052.25±136.60	^a 2089.00±294.60
DM-1	^b 177.42±39.04	^b 312.09±61.59
DM-2	^b 405.06±72.34	^b 556.70±83.61
DM-3	^b 323.65±62.21	^b 474.56±69.37
GF-1	^{acde} 1238.42±518.50	^{abcde} 1246.40±457.31
GF-2	^{acde} 1185.93±282.35	^{acde} 1435.75±339.47
GF-3	^{acde} 1763.16±311.39	^{acde} 1718.91±208.10
F-value / p value	8.791/0.000	11.833/0.000

DM: Dihydromyrcenol. GF: Geranyl formate. SD: Standard deviation.

Post-hoc Student-Newman-Keuls (SNK) test results: a: p<0.05, as compared with SP and olive oil groups; b: p<0.05, as compared with CCl₄ group; c: p<0.05, as compared with DM-1 group; d: p<0.05, as compared with DM-2 group; e: p<0.05, as compared with DM-3 group.

Table 3. Histopathological results of the study groups

Groups (n=6 in each)	Ballooning degeneration (Mean±SD)	Apoptotic cell counts (Mean±SD)	Mitotic counts (Mean±SD)
Control	0.13±0.03	0.05±0.03	0.02±0.02
Olive Oil	0.18±0.03	0.08±0.03	0.03±0.02
CCl ₄	^a 39.98±5.93	^a 4.10±0.35	0.20±0.07
DM-1	^b 1.53±0.80	^b 0.68±0.11	0.20±0.10
DM-2	^b 8.20±1.87	^b 1.10±0.12	0.27±0.10
DM-3	^b 6.75±2.65	^b 1.22±0.15	0.20±0.10
GF-1	^{abcde} 18.08±3.08	^{abcde} 1.93±0.44	0.13±0.08
GF-2	^{abcde} 23.08±6.80	^{abcde} 2.70±0.65	0.86±0.72
GF-3	^{acdefg} 45.18±5.37	^{acdefg} 4.78±0.39	0.13±0.05
F value/p value	21.732/0.000	29.474/0.000	1.175/0.337

DM: Dihydromyrcenol. GF: Geranyl formate. SD: Standard deviation.

Post-hoc Student-Newman-Keuls (SNK) test results: a: p<0.05, compared with SP and olive oil groups; b: p<0.05, compared with CCl₄ group; c: p<0.05, compared with DM-1 group; d: p<0.05, compared with DM-2 group; e: p<0.05, compared with DM-3 group; f: p<0.05, compared with GF-1 group; g: p<0.05, compared with GF-2 group.

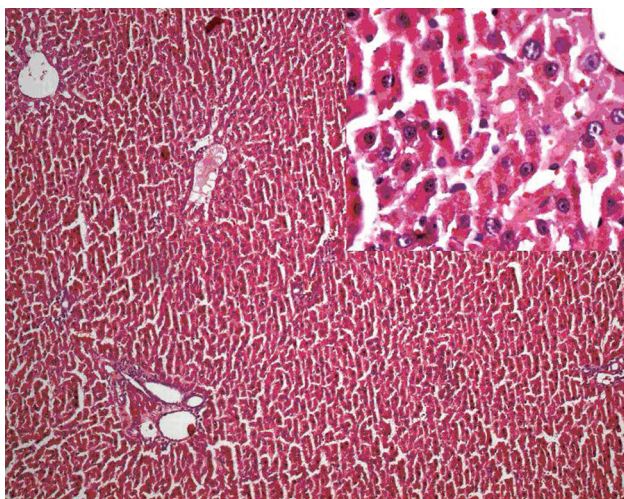


Figure 1. Group 1 (Control, Serum Physiologic [SP]) (H&E x10; inset: H&E x40).

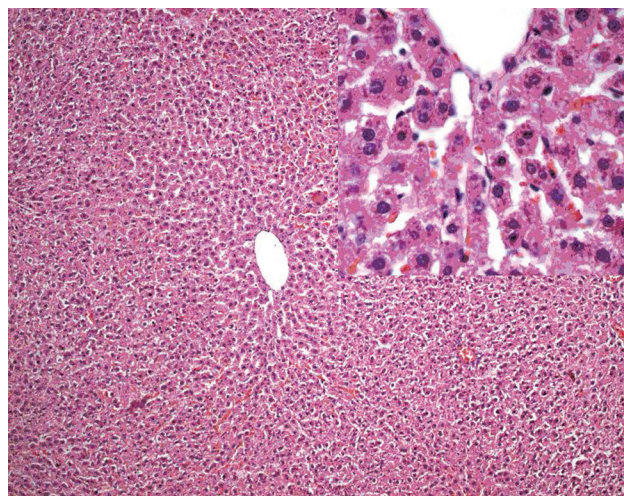


Figure 2. Group 2 (Olive oil) (H&E x10; inset: H&E x40).

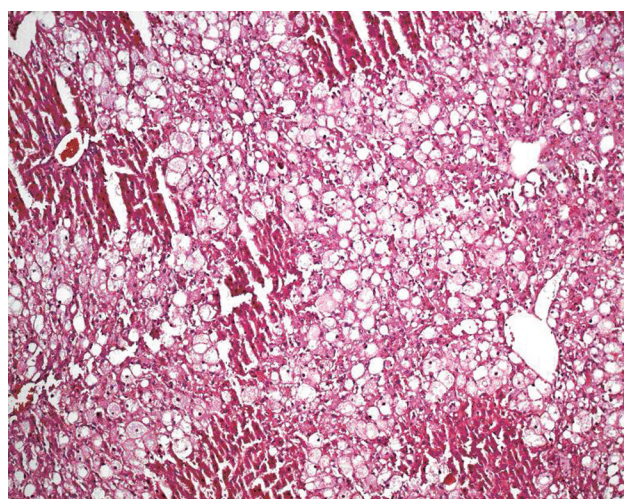


Figure 3. Group 3 (CCl₄) (H&E x20).

mitotic counts showed no significant differences ($p > 0.05$). In the DM groups, mild pleomorphism was observed; however, no bridging necrosis was noted (Figure 4).

In the GF groups, a number of hepatocytes with ballooning degeneration and apoptotic hepatocytes were observed. The GF-2 group had multiple mitoses, contrary to the other groups. The severity of ballooning degeneration and apoptotic cell counts were significantly higher in the GF-1 and GF-2 groups than in the control, olive oil, and DM groups; however, they were significantly lower than those in the GF-3 and CCl₄ groups ($p < 0.05$). When the GF-3 group was compared with the control, olive oil, DM-1, DM-2, DM-3, GF-1, and GF-2 groups in terms of ballooning degeneration and apoptotic cell counts, a statistically significant increase was observed ($p < 0.05$), whereas there was no statistically significant difference between the GF-3 and CCl₄ groups ($p < 0.05$). In the comparisons of the GF groups with the other groups for mitotic counts, no statistically significant differences were determined ($p > 0.05$). In the GF groups, on the other hand, sporadic bridging necrosis and marked pleomorphism were observed (Figure 5).

In MT staining, which was performed to evaluate the fibrosis reflecting chronic hepatic damage, no fibrosis was observed except a mild connective tissue increase around the portal areas of the CCl₄ and GF groups only.

In reticulin staining, the reticulin network was found to be protected in the control and olive oil groups, while a mild disturbance was noted in a limited number of areas in the DM groups. Strikingly, the reticulin network was severely disordered in the GF groups and the CCl₄ group.

DISCUSSION

In the present study, the hepatoprotective effects of DM and GF on acute hepatic injury induced by CCl₄ were investigated in an experimental rat model.

The liver is often exposed to oral or parenteral drugs, toxic substances and microbic agents, and is thus affected by their negative effects. However, the liver either detoxifies these agents or responds with its regeneration ability (1,2,20,21).

In our study, in which the hepatoprotective effects of DM and GF were investigated, acute hepatic injury was induced by CCl₄. CCl₄ is one of the well-known and most frequently used agents to induce

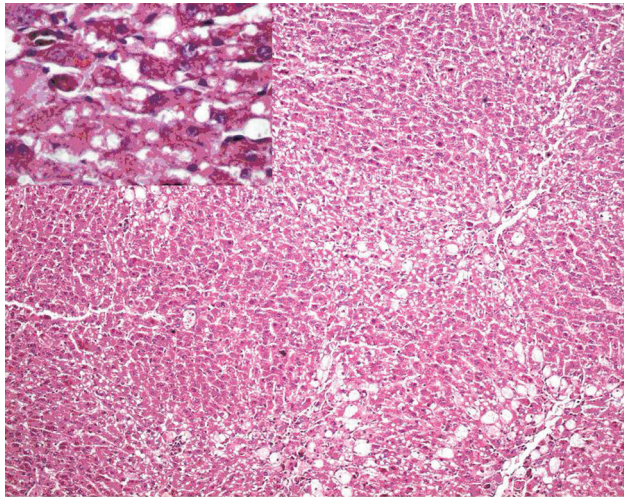


Figure 4. Group 6 (DM-3) (H&E x10; inset: H&E x40).

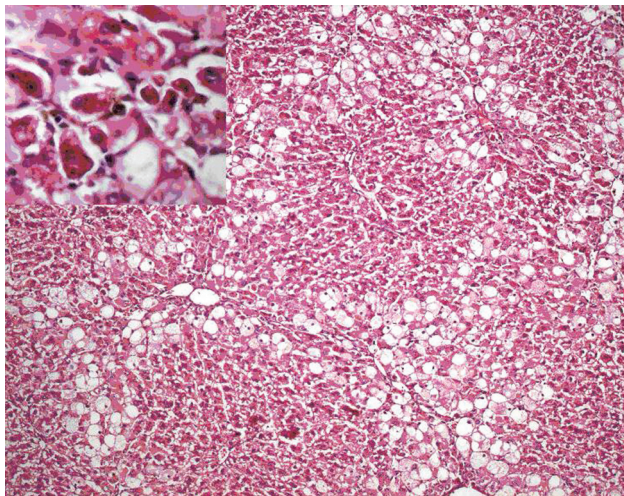


Figure 5. Group 9 (GF-3) (H&E x10; inset: H&E x40).

hepatic injury. Hepatic injuries induced by CCl_4 in experimental animals are similar to those in humans (22-27).

The limitation of the study duration to 7 days prevents further damages and increases the survival rates of the animals; thus, it allows monitoring and defining of the procedures. Thus, a 7-day experimental model of CCl_4 -induced acute hepatic injury is a conclusive and practical method (17,18).

The liver enzyme levels rapidly increase due to membrane damage in the hepatocytes caused by CCl_4 . The severity of CCl_4 -associated hepatic damage is correlated with the serum levels of liver enzymes (22,28-30).

Bruckner et al. (31) observed ballooning degeneration in the centrilobular hepatocytes, ground-glass appearance, pleomorphism in the nuclei, enlargement in the centrilobular areas, and rarely, necrotic cells in rats exposed to CCl_4 . In the study of Grizzi et al. (32), in which the rats were treated with CCl_4 , the authors determined hepatocyte necrosis in the centrilobular zone and inflammatory cell infiltration with high macrophage and lymphocyte concentration 2 hours after the application of CCl_4 . In that particular study, in the hepatocytes located near the centrilobular zone, hydropic degeneration, vacuolization and swelling were observed (32). Additionally, changes involving fat were in the form of a few drops of variable size to diffuse involvement (32). After 24 hours, the same characteristic findings were reported to be more severe (32). In our study, histopathological and biochemical changes were observed in the rats exposed to CCl_4 , which were compatible with the results of earlier studies.

The extracts of the *Vitis vinifera* plant, which is used as an alternative medicine and food in many areas, have been used in studies on biological activity. In these studies, the chemicals obtained from this plant and the plant itself were found to protect the hepatic, renal and cardiovascular systems, to have antioxidant, antibacterial, antiulcer, anti-inflammatory, vasodilatory, and antiplatelet effects, and to reduce carcinogenic metabolite formation (16,33-43).

Orhan et al. (16) demonstrated hepatoprotective effects of the VVL plant in a rat model of CCl_4 -induced acute hepatic injury. In another study, the *Vitis vinifera* seed proanthocyanidin extract was reported to prevent liver damage and liver cell death, and also to prevent DNA damage by reducing the oxidative stress in rats (34).

In the study by Folts (35), grape flavonoids administered at proper doses were reported to reduce the risk of platelet-associated acute coronary thrombosis.

Yamakoshi et al. (36) studied atherosclerosis in rabbits and observed that the proanthocyanidins extracted from *Vitis vinifera* seeds reduced low-density lipoprotein oxidation in the arterial endothelia and plasma.

In their study on type-II diabetes mellitus patients, Zoppo et al. (38) used seed extract of the VVL plant and determined that lipid peroxidation significantly reduced as a result of its antioxidant effects.

In an experimental study, the substances with different polarities in the ethyl-acetate fractions of the watery extract obtained from the leaves of VVL were shown to have significant hypoglycemic effects and to reduce diabetes-related hypoglycemia and damage, and to increase levels of glutathione, one of the natural antioxidants (39).

In a biological activity study, Frankel *et al.* (37) proved that the catechin oligomers obtained from VVL extract, procyanidin dimers and trimers, and other flavonoids had significant antioxidant effects. In their study, Jayaprakasha *et al.* (40) reported that procyanidin-rich extracts from the *Vitis vinifera* seed exhibited antibacterial effects against both the gram-positive and -negative bacteria tested.

Alam *et al.* (42) determined that the VVL extract prevented DNA damage in a dose-dependent manner and thus prevented tumor formation. In another study, resveratrol, which is produced by the stimulating effects of microorganisms or ultraviolet rays in the leaves, was shown to prevent tumor formation and development (43).

In our study, the damage induced by CCl₄ improved significantly with the use of DM. A significant reduction was observed in terms of ballooning degeneration and apoptotic cell counts in DM groups as compared with the CCl₄ group on histopathologic examination. In accordance with these histopathological results, a significant decrease was also observed in the ALT and AST levels in DM groups as compared with the CCl₄ group. Since an elevation in AST and ALT enzyme activities can be considered as a sign of cell membrane damage, which can be prevented by antioxidants, the effect of DM observed on CCl₄-induced hepatotoxicity may be attributed to the antioxidant effect of DM. The situation was slightly different in GF groups. Although a partial improvement was observed with low doses of GF, no improvement was observed with its high doses. This mechanism observed with GF may present similarity with the mechanism observed with acetylsalicylic acid. While acetylsalicylic acid exhibits blood thinning effect at low doses, this effect disappears at high doses.

Thus, further studies are required to investigate the effects of GF at low and high doses. It should be noted that one of the limitations of the present study is the lack of data on antioxidant status, regarding the measurements of antioxidant enzymes such as malondialdehyde and superoxide dismutase. Thus, to determine the antioxidant nature of DM and also GF, future studies are required on this issue. In addition, a literature review has revealed that there are a limited number of studies conducted with DM and/or GF, and none of them evaluated their effects on the liver. Thus, the findings of our study could not be compared with earlier data.

Based on the results of the present study, DM found in the extract of the VVL plant, known to have hepatoprotective effects, was thought to protect the liver from the damage that may be induced by lipid peroxidation. Nevertheless, to benefit from the hepatoprotective effects of the VVL plant, similar studies with all the constituents of the plant are needed (11,16). Moreover, to determine the best hepatoprotective agent, other agents known to have hepatoprotective effects should be compared in future studies.

In conclusion, in the present CCl₄-induced acute hepatic injury model of rats, the hepatoprotective effects of DM and GF, the differences between their effects, and dose-related differences were evaluated. The following results were obtained:

1. SP and olive oil did not cause changes reflecting damage in the hepatocytes, portal triad, sinusoidal structure, central veins, or liver lobes.
2. High doses of CCl₄ and GF increase the severity of ballooning degeneration and apoptotic cell counts, reflecting the hepatic damage.
3. DM significantly reduces the ballooning degeneration and apoptotic hepatocyte counts caused by CCl₄, and thus has hepatoprotective effects.
4. GF causes partial hepatoprotective effects only at low doses.
5. The mitotic count is not a marker of hepatic damage.

REFERENCES

1. Zimmerman HJ, Maddrey WC. Toxic and drug-induced hepatitis. In: Schiff L, Schiff ER, eds. Diseases of the liver. 6th ed. Philadelphia: JB Lippincott, 1987; 591-668.
2. Orrego H, Blake JE, Blendis LM, Medline A. Prognosis of alcoholic cirrhosis in the presence and absence of alcoholic hepatitis. *Gastroenterology* 1987; 92: 208-14.

3. Seven A, Candan G. Antioksidan savunma sistemleri. *Cerhaşa J Med* 1996; 27: 41-50.
4. Brattin WJ, Glende EA, Recknagel RO. Pathological mechanisms in carbon tetrachloride hepatotoxicity. *J Free Radio Biol Med* 1985; 1: 27-38.
5. Bacon BR, Tavill AS, Brittenham GM, et al. Hepatic lipid peroxidation in vivo in rats with chronic iron overload. *J Clin Invest* 1983; 71: 429-39.
6. Comporti M. Lipid peroxidation and cellular damage in toxic liver injury. *Lab Invest* 1985; 53: 599-623.
7. Kaplowitz N, Fernandez-Checa J, Ookhtens M. Glutathione, alcohol and hepatotoxicity. In: Halsted CH, Rucker RB, eds. *Nutrition and the origins of disease*. 1st ed. San Diego: Academic Press, 19; 267-82.
8. Slater TF. Free-radical mechanisms in tissue injury. *Biochem J* 1984; 222: 1-15.
9. Yao T, Delgi Esposti S, Huang L, et al. Inhibition of carbon tetrachloride-induced liver injury by liposomes containing vitamin E. *Am J Physiol* 1994; 267: 476-84.
10. Halliwell B, Murcia MA, Chirico S, Aruoma OI. Free radicals and antioxidants in food and in vivo: what they do and how they work. *Crit Rev Food Sci Nutr* 1995; 35: 7-20.
11. Rocha SM, Coelho E, Zrostlíková J, et al. Comprehensive two-dimensional gas chromatography with time-of-flight mass spectrometry of monoterpenoids as a powerful tool for grape origin traceability. *J Chromatogr A* 2007; 1161: 292-9.
12. Rohloff J. Volatiles from rhizomes of *Rhodiola rosea* L. *Phytochemistry* 2002; 59: 655-61.
13. Verma RS, Verma RK, Yadav AK, Chauhan A. Changes in the essential oil composition of rose-scented geranium (*Palergonium graveolens* L'Herit. Ex Ait.) due to the date of transplanting under hill conditions of Uttarakhand. *Indian J Natural Products Resources* 2010; 1: 367-70.
14. Rao BR, Kaul PN, Syamasundar KV, Ramesh S. Water soluble fractions of rose-scented geranium (*Palergonium species*) essential oil. *Bioresour Technol* 2002; 84: 243-6.
15. Palitano VT, Lewis EM, Hoberman AM, et al. Evaluation of the developmental toxicity of dihydromyrcenol in rats. *Int J Toxicol* 2009; 28: 80-7.
16. Orhan DD, Orhan N, Ergun E, Ergun F. Hepatoprotective effect of *Vitis vinifera* L. leaves on carbon tetrachloride-induced acute liver damage in rats. *J Ethnopharmacol* 2007; 112: 145-51.
17. Bayram İ, Özbek H, Uğraş S, et al. Askorbik asit ve Alfa-tokoferol'ün karbon tetraklorürle oluşturulmuş akut karaciğer toksisitesi modelinde karaciğeri koruyucu etkisi. *Van Tıp Dergisi* 2004; 11: 32-8.
18. Erdoğan E, Kaya A, Rağbetli MÇ, et al. Anason (*Pimpinella anisum*) ekstresinin deneysel akut karaciğer hasarında karaciğeri koruyucu etkisi var mı?. *Van Tıp Dergisi* 2004; 11: 69-74.
19. Handa SS, Sharma A. Hepatoprotective activity of andrographolide from *Andrographis paniculata* against carbon tetrachloride. *Indian J Med Res* 1990; 92: 276-83.
20. Akşit D, Yıldız Z, Çelik H, Sargon M. Karın II: karın boşluğu. In: Yıldırım M. *Klinik anatomi*. 5. baskı. İstanbul: Yüce Yayınları, 198; 216-9.
21. Crawford JM. The liver and the biliary tract. In: Kumar V, Cotran RS, Robbins SL, eds. *Robbins basic pathology*. 7th ed. Philadelphia: Elsevier Saunders, 2002; 592-611.
22. Boll M, Weber LW, Becker E, Stampfl A. Mechanism of carbon tetrachloride-induced hepatotoxicity. Hepatocellular damage by reactive carbon tetrachloride metabolites. *Z Naturforsch C* 2001; 56: 649-59.
23. Gruebele A, Zawaski K, Kaplan D, Novak RF. Cytochrome P4502E1-cytochrome P4502B1/2B2-catalyzed carbon tetrachloride metabolism. *Drug Metab Dispos* 1996; 24: 15-22.
24. Gilani AH, Janbaz KH. Preventive and curative effects of *Artemisia absinthium* on acetaminophen and CCl4 induced hepatotoxicity. *Gen Pharmacol* 1995; 26: 309-15.
25. Recknagel RO, Glende EA, Dolak JA, Waller RL. Mechanisms of carbon tetrachloride toxicity. *Pharmacol Ther* 1989; 43: 139-54.
26. Pérez-Tamoya R. Is cirrhosis of the liver experimentally produced by CCl4 an adequate model of human cirrhosis?. *Hepatology* 1983; 3: 112-20.
27. Paquet KJ, Kamphausen U. The carbon-tetrachloride-hepatotoxicity as a model of liver damage. *Acta Hepatogastroenterol (Stuttg)* 1975; 22: 84-8.
28. Yu BP. Cellular defenses against damage from reactive species. *Physiol Rev* 1994; 74: 139-62.
29. Recknagel RO. Carbon tetrachloride hepatotoxicity. *Pharmacol Rev* 1967; 19: 145-208.
30. Wang GS, Eriksson LC, Xia L, et al. Dietary iron overload inhibits carbon tetrachloride-induced promotion in chemical hepatocarcinogenesis: effects on cell proliferation, apoptosis, and antioxidation. *J Hepatol* 1999; 30: 689-98.
31. Bruckner JV, MacKenzie WF, Muralidhara S, et al. Oral toxicity of carbon tetrachloride: acute, subacute, and subchronic studies in rats. *Fundam Appl Toxicol* 1986; 6: 16-34.
32. Grizzi F, Franceschini B, Gagliano N, et al. Mast cell density, hepatic stellate cell activation and TGF-beta1 transcripts in the aging Sprague-Dawley rat during early acute liver injury. *Toxicol Pathol* 2003; 31: 173-8.
33. Bombardelli E, Morazzoni P. *Vitis vinifera* L. *Fitoterapia* 1995; 66: 291-317.
34. Bagchi D, Bagchi M, Stohs SJ, et al. Free radicals and grape seed proanthocyanidin extract: importance in human health and disease prevention. *Toxicology* 2000; 148: 187-97.
35. Folts JD. Antithrombotic potential of grape juice and red wine for preventing heart attacks. *Pharm Biol* 1998; 36: 21-7.
36. Yamakoshi J, Kataoka S, Koga T, Ariga T. Proanthocyanidin-rich extract from grape seeds attenuates the development of aortic atherosclerosis in cholesterol-fed rabbits. *Atherosclerosis* 1999; 142: 139-49.
37. Frankel EN, Meyer AS. Antioxidants in grapes and grape juices and their potential health effects. *Pharm Biol* 1998; 36: 14-20.
38. Zoppo A, Viappiani S, Tragni E, et al. Treatment with natural anti-oxidants from *Vitis vinifera* decreases lipid peroxidation in non insulin-dependent diabetics. *Atherosclerosis* 2000; 15: 61-2.
39. Şendoğdu N. *Vitis vinifera* L. yapıklarının şeker hastalığı üzerindeki etkilerinin araştırılması. Gazi Üniversitesi, Sağlık Bilimleri Enstitüsü, Farmakognozi AD, Yüksek Lisans Tezi, Ankara, 2004.
40. Jayaprakasha GK, Selvi T, Sakariah KK. Antibacterial and antioxidant activities of grape (*Vitis vinifera*) seed extracts. *Food Res Int* 2003; 36: 117-22.
41. Carini M, Stefani R, Adlini G, et al. Procyanidins from *Vitis vinifera* seeds inhibit the respiratory burst of activated human neutrophils and lysosomal enzyme release. *Planta Med* 2001; 67: 714-7.
42. Alam A, Khan N, Sharma S, et al. Chemopreventive effect of *Vitis vinifera* extract on 12-O-tetradecanoyl-13-phorbol acetate-induced cutaneous oxidative stress and tumor promotion in murine skin. *Pharmacol Res* 2002; 46: 557-64.
43. Latruffe N, Delmas D, Jannin B, et al. Molecular analysis in the chemopreventive properties of resveratrol, a plant polyphenol microcomponent. *Int J Mol Med* 2002; 10: 755-60.