

Upper gastrointestinal findings in oral lichen planus

Oral liken planusta üst gastrointestinal bulgular

Hatice SANLI¹, Hülya ÇETİNKAYA², Ümit TÜRSEN², Muhsin KAYA², Işınsoy KUZU³, Aysel GÜRLER¹

Ankara University School of Medicine, Departments of Dermatology¹, Gastroenterology² and Pathology³, Ankara

Background/aims: Lichen planus is an inflammatory disease of the skin and mucous membranes. Oral mucosa is known to be frequently affected by the disease, but it has also been observed that gastrointestinal mucosae are sometimes involved. **Methods:** In this study, the upper gastrointestinal tract was investigated endoscopically and histopathologically in 20 patients with oral lichen planus. **Results:** Endoscopy determined antral gastritis in seven patients, esophagitis in four, bulbitis in three, chronic duodenal ulcer in one and esophageal sphincter dysfunction in one patient. Lichen planus-like changes on the esophageal mucosa at histopathological examination were found in one patient. Findings in the other patients were as follows: chronic atrophic gastritis (nine), helicobacter pylori infection (nine), esophagitis (two), bulbitis (two) and erosive gastritis (one). **Conclusion:** Patients with Lichen planus should be evaluated for possible gastro-intestinal involvement with endoscopy.

Key words: Lichen planus, mucosa, gastrointestinal tract.

Amaç: Liken planus deri ve mukozaların kronik inflamatuvar bir hastalıktır. Oral mukoza sık tutulur. Nadiren gastrointestinal mukoza tutulumu da tanımlanmıştır. **Yöntem:** Çalışmamızda 20 oral liken planuslu hastada üst gastrointestinal sistem endoskopik ve histopatolojik olarak incelenmiştir. **Bulgular:** Endoskopik incelemede 7 hastada antral gastrit, 4 hastada özofajit, 3 hastada bulbit, 1 hastada kronik duodenal ülser ve 1 hastada alt özofageal sfinkter disfonksiyonu saptanmıştır. Histopatolojik olarak bir hastada, özofagusta liken planus benzeri değişiklikler saptanmıştır. Diğer hastaların 9'unda atrofik gastrit, 9'unda helicobacter pylori infeksiyonu, 7'sinde özofajit, 2'sinde bulbit, 1'inde eroziv gastrit saptanmıştır. **Sonuç:** Liken planus olguları, gastrointestinal tutulum açısından değerlendirilmelidir.

Anahtar kelimeler: Liken planus, mukoza, gastro-intestinal traktus.

INTRODUCTION

Lichen planus (LP) is an inflammatory disease of the skin and mucosa affecting from 0.5% to 2% of the population (1-5). Mucous membrane lesions occur in about two-thirds of all cases (6). The lesions are found on the buccal mucosa, tongue, lips, gums, palate, tonsils and pharynx and also throughout the gastro-intestinal (GI) tract from the stomach to the rectum and anal mucosa (1-7). Early diagnosis and treatment are important in mucosal involvement because of the possibility of malignant transformation and strictures (8). The purpose of this study was to evaluate upper gastro-intestinal findings of patients with oral LP.

MATERIAL AND METHODS

Upper GI findings of 20 patients with oral LP, diagnosed clinically and histopathologically were evaluated in this prospective study. An examina-

tion was performed to establish the type and location of oral lesions and whether there were cutaneous lesions and nail involvement. Patients were also questioned about gastro-intestinal symptoms (dysphagia, odynophagia, flatus, pyrosis, melena, hematemesis, hunger pain). Evaluation of the upper GI tract by upper GI endoscopic examination was performed after 2 mg-5 mg premedication of midazolam. Biopsies were taken from at least three different places (lower third of the esophagus, corpus and antrum of the stomach) and particularly suspicious lesions during endoscopic examination. Histological examination of biopsy specimens were stained with H&E.

RESULTS

Of the 20 patients, there were 10 (50%) women and 10 (50%) men with an age range of 28 to 65

Table 1. Endoscopic and histopathologic features of patients with oral lichen planus

Case	Oral lesions	Endoscopic findings	Histopathologic findings
36, M	white plaque	normal	Chronic atrophic gastritis, Helicobacter pylori(+)
48, M	white plaque	bulbitis, antral gastritis	esophagitis, antral erosive gastritis, bulbitis
49, M	white plaque, erosion	bulbitis	bulbitis
55, F	white plaque	antral gastritis	chronic atrophic gastritis, Helicobacter pylori (+)
64, F	white plaque, erosion, atrophy	esophageal sphincter dysfunction	esophagitis
52, M	white plaque, erosion	antral gastritis	achantotic mucosa of esophagus
46, F	white plaque, erosion	normal	normal
38, M	white plaque, erosion	normal	chronic atrophic gastritis, Helicobacter pylori (+)
48, F	white plaque, erosion, atrophy	normal	normal
34, F	white plaque	normal	chronic atrophic gastritis, Helicobacter pylori (+).
50, M	white plaque, erosion	antral erosive gastritis, esophagitis	chronic atrophic gastritis, Helicobacter pylori (+)
58, F	white plaque, erosion	esophagitis, pangastritis	chronic esophagitis, chronic atrophic gastritis, Helicobacter pylori (+)
65, F	white plaque, erosion	esophagitis, antral gastritis, chronic duodenal ulcer	chronic atrophic gastritis, Helicobacter pylori (+)
60, M	white plaque, erosion	bulbitis	esophagitis
28, M	white plaque, erosion	normal	chronic atrophic gastritis, Helicobacter pylori (+)
29, F	white plaque	normal	esophagitis
58, F	white plaque, erosion	normal	esophagitis
39, F	white plaque, erosion	normal	normal
54, M	white plaque, erosion	antral gastritis	chronic atrophic gastritis, Helicobacter pylori (+)
36, M	white plaque	Esophagus normal, chronic active gastric ulcer	mild esophagitis, Lichen planus like changes

years (mean 47.3), the range of chronicity of mucocutaneous symptoms was from two months to 17 years (mean chronicity four years). Evaluation of oral LP lesions were that 20 patients (100%) had white plaque, 14 (70%) erosions, and four (20%) had atrophy. There was involvement of the buccal mucosa in 19 cases (95%), tongue in five (25%), lips in two (10%) and gingivae in one (5%) case. Sixteen cases (80%) also had cutaneous involvement, with 12 of these having local and six having generalized cutaneous involvement. There was nail involvement in seven cases (35%), with longitudinal grooving in all cases and pterygium in only one case.

Gastrointestinal complaints were present in four cases (20%), with hunger pain in three patients, dysphagia in one and flatus in one. Endoscopic studies of these patients showed that seven had antral gastritis, four had esophagitis, three had bulbitis, one had chronic duodenal ulcer and one patient had lower esophageal sphincter dysfunction. In histopathological examinations, nine cases had chronic atrophic gastritis, nine had helicobacter pylori infection, seven had esophagitis, two had bulbitis, one had erosive gastritis and one

cases had lichen planus-like changes (Table 1). In the last case, from whom biopsies were taken from the lower third of the esophagus, it was observed that the lamina propria contained band like mononuclear inflammatory infiltrations surrounding the epithelium and that the epithelium was infiltrated by the inflammatory cells (Figure 1). Endoscopic studies of this patients esophagus were found to be completely normal, but a chronic gastric ulcer was found. There were white plaque lesions on the buccal mucosa.

DISCUSSION

Mucous membrane lesions occur in about two-thirds of all LP cases. While approximately 50% of patients with skin lesions have oral lesions, these may be the only manifestation of the disease in about 15 to 25 percent of cases (6-7, 9-12). In oral LP, the buccal mucosa, gingiva and tongue are primarily affected, with typical lesions consisting of reticulated white plaques and erosive, atrophic and/or bullous lesions (1, 12, 13). In this study, buccal mucosa involvement was present in 95% and white plaque lesions in all cases. Lesions of LP may be seen throughout the GI tract (6, 14).

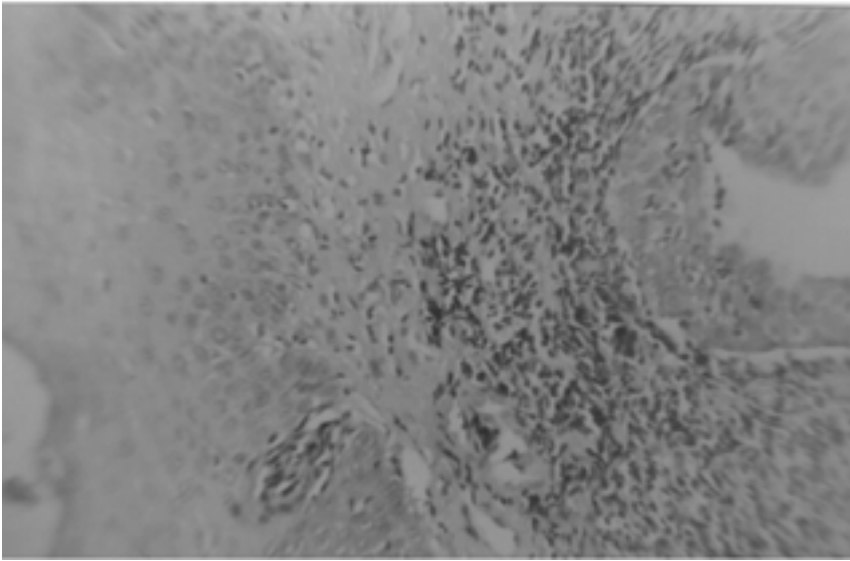


Figure 1. Esophageal mucosa with squamous epithelium (right side). There is section of mucosal invagination under the luminal epithelium in the lamina propria which contains striking band like mononuclear inflammatory infiltration surrounding the epithelium. The epithelium is also infiltrated by the inflammatory cells. These features may be describe as lichenoid infiltration.

The esophagus is the most frequently involved part of GI tract but it is a rarely reported condition in the literature (11, 15, 16). Although there are no reported cases of malignant change in esophageal lichen planus, the possibility of malignant change has been suggested. In 1982, Gueden et al. described a patient with midesophageal stricture and postulated that the formation of LP at the site of presumed peptic esophagitis was an example of the Koebner phenomenon (17). In 1982, Lefer described one case indicating an esophageal web with oral LP (18). In the same year, Al-Shihabi & Jackson described a patient with a mid-esophageal stricture that could have been due to esophageal involvement of LP (19, 20). In endoscopic examination of LP esophageal involvement, erythema, ulcer or erosions throughout the esophagus can be seen (21). In 1990, Dichens et al found esophageal lesions in five of the 19 patients with lichen planus found at endoscopy. There were severe erosive changes throughout the esophagus in one of these patients and subtle papular lesions were observed in the other four (11). Diagnosis of biopsy specimens of the esophageal mucosa lesions at histopathologic

examination was not possible due to acid reflux. Characteristic lesions consist of bandlike lymphocytic infiltrations of submucosal tissues. In severe esophageal disease however, heavy polymorphonuclear and plasma cells can be seen in the fibromuscular tissue underlying the necrotic areas (10, 11, 22). Histopathologic examination of our case revealed that the lamina propria contained band-like mononuclear inflammatory infiltrations surrounding the epithelium and also among the epithelium cells. It is of interest that the esophagus was completely normal at endoscopic examination of this case, only gastric ulcer was found and on questioning, the patient had no complaints. Evaluation of lower esophageal sphincter dysfunction was negative for gastro-esophageal reflux disease and our patient also responded well to corticosteroid treatment. There were white-reticulated plaques on the buccal mucosa and tongue, localized skin lesions and longitudinal grooving on the nails of the patient.

The most common findings at endoscopy were antral gastritis (35%), esophagitis (20%) and bulbitis (15%). Correspondingly, histopathologic examination detected chronic atrophic gastritis

(45%), esophagitis (35%) and bulbitis (10%). In accordance with the established rate of prevalence in Turkey, half of the patients were positive for *Helicobacter pylori* infection in gastric and duodenal mucosa lesions (23 -27). Most of these patients were symptom free.

In conclusion, patients presenting with LP should

be questioned about GI symptoms and if GI system involvement is suspected, upper gastrointestinal endoscopy should be performed. When severe esophageal involvement is found, steroid treatment should be commenced to reduce the symptoms and complications such as strictures and possible malignant transformation.

REFERENCES

1. Brown RS, Bottomly WK, Puente E et al. A retrospective evaluation of 193 patients with oral lichen planus. *J Oral Pathol Med* 1993; 22: 69-72.
2. Eversol LR. Lichen planus. In: Millard HD, Mason DK eds. *World workshop on oral medicine*. Chicago: Year Book Medical Pub, 1989:60-5.
3. Axell T, Rundquist L. Oral Lichen planus-demographic study. *Community Dent Oral Epidemiol* 1987; 15: 52-6.
4. Bouquot JE, Gorlin RJ. Leukoplakia, Lichen planus and other oral keratoses in 32, 616 white Americans over the age of 35 years. *Oral Surg Oral Med Oral Pathol* 1986; 61: 373-81.
5. Scully C, El-Kom M. Lichen planus: review and update on pathogenesis. *J Oral Pathol* 1985; 14: 431-58.
6. Arnt KA Lichen planus. In: Fitzpatrick TB, Eisen AZ et al eds. *Dermatology in General Medicine*. 4th ed. Mc-Graw Hill Inc, USA. 1993; 1134-44.
7. Neuman R, Dutt CJ, Foster CS. Immunohistopathologic features and therapy of conjunctival lichen planus. *A m J Ophthal* 1995; 115: 494-500.
8. Sigurgeirsson B, Lindelöf B. Lichen Planus and Malignancy: an epidemiologic study of 2071 patients and a review of the literature. *Arch Dermatol* 1991; 127: 1684-8.
9. Sheehan-Dare RA, Cotterill JA, Simmons AV. Esophageal lichen planus. *British J Dermatol* 1986; 115: 729-30.
10. Holder PD, Wong WL, Pemberton J, et al. Diagnosis and treatment of an esophageal stricture due to lichen planus. *British J Radiol* 1992; 65: 451-2.
11. Dickens CM, Heseltine D, Walton S, Bennet JR. The esophagus in lichen planus: an endoscopic study. *BMJ* 1990; 300: 84.
12. Jungell P. Oral lichen planus. *Int J Oral Maxillofac Surg* 1991; 20: 129-35.
13. Moncarz V, Ulmanský M, Lustmann J. Lichen planus: Exploring its malignant potential. *JADA* 1993; 124:102-8.
14. Shklar G, McCarthy PL. The oral lesions of lichen planus. Observations of 100 patients. *Oral Surg Oral med Oral Pathol* 1961; 14: 168.
15. Abraham SC, Ravich WJ, Anhalt GJ, et al. Esophageal lichen planus: case report and review of the literature. *Am J Pathol* 2000; 24: 1678-82
16. Harewood GC, Murray JA, Cameron AJ. Esophageal lichen planus: the Mayo Clinic experience. *Dis Esophagus* 1999; 12: 309-11.
17. Guedon C, Kuffer R, Thomine E, et al. Stenosing lichen planus of the esophagus. *Gastroenterol Clin Biol* 1982; 12: 1049
18. Lefer LG. Lichen planus of the esophagus *Am J Dermatopathol* 1982; 4:269
19. Al-Shihabi BMS, Jackson JM. Dysphagia due to pharyngeal and esophageal lichen planus. *J Laryngol Otol* 1982; 96: 567-71.
20. Ottingon Y, Carayon P, Deschamps JP et al. Stenosing lichen planus of the esophagus. *Gastroenterol Clint Biol*. 1983; 10: 830.
21. Mirowski GW, Berger TG. Oral and cutaneous manifestations of gastrointestinal disease. In: eds Sleisenger MH, Seldman M, Schar Schmidt BS eds. *Gastrointestinal and Liver Disease*. 6th ed. WB Saunders Company, Philadelphia. 1998; 439-53.
22. Morson BC. *Alimentary Tract*. 1st ed. Churchill Livingstone, London 1987: 20-22.
23. Özden A, Dumlu, Dönderici Ö ve ark. *Helikobakteri pylori* infeksiyonunun ülkemizdeki epidemiyolojisi. *Turk J Gastroenterol* 1992; 3: 664-8.
24. Doğan ÜB, Tuncer C, Dursun A, et al. Türkiye'de *helikobakteri pylorinin* yaş gruplarına göre dağılımı. *Turk J Gastroenterol* 1996; 3: 664-8.
25. Kansu A, Kalaycı AG, Ulukol B, et al. Çocuklarda kronik tekrarlayıcı karın ağrısı etyolojisinde *helikobakteri pylorinin* önemi. *Turk J Gastroenterol* 1998; 9; 39, B114.
26. Kutlu T, Çullu F, Tümay GT, et al. Çocuklarda *Helikobakteri pylori* enfeksiyonu. XI. Ulusal Türk Gastroenteroloji Kongresi Bildirileri Kitabı 1994:p 202.
27. Kalkan A, Bulut A, Bahçecioğlu, et al. Elazığ yöresinde *helikobakteri pylori* prevalansı. XIV. Ulusal Gastroenteroloji Kongresi Bildirileri Kitabı. 1997: p209.