

A new and safe technique for removing cervical esophageal foreign body

Taş Boğaz: Servikal özofagustaki yabancı cisimlerin çıkartılmasında yeni ve güvenli bir teknik

Serdar HAN¹, Burçak KAYHAN², Koray DURAL¹, Bülent KOÇER¹, Ünal SAKİNCİ¹

¹Department of Thoracic Surgery, ²Department of Gastroenterology, Ankara Numune Education and Research Hospital, Ankara

Despite the recent advances in instrumentation and anesthesia, removal of esophageal foreign bodies remains a challenge. Endoscopic removal of foreign bodies has yielded a success rate of 80%. Surgical removal of these foreign bodies is necessary when the endoscopic manipulations fail. Localization and size of the bodies play a critical role in the method of treatment. Here we present a patient with a large stone with sharp edges located in the cervico-thoracic region which was removed after being pushed into the hypopharynx through the esophagus rather than being pushed into the stomach. The technique used proved to be effective and safe; this may be the first use of the procedure in the literature.

Endoskopik olarak özofagustaki yabancı cisim çıkarılma başarısı %80'dir. Endoskopinin yetersiz olduğu yerlerde cerrahi gerekli hal almaktadır. Bu tür cerrahi tedavilerde yabancı cismin büyüklüğü ve yeri tedavi şekli yönünden önemli rol oynamaktadır. Biz burada servikotorasik bölgede yerleşmiş keskin kenarlı yabancı cismin mideden hipofarinkse itilmesi yoluyla çıkarılmasını sunuyoruz.

Anahtar kelimeler: Özofagus, yabancı cisim, cerrahi

Key words: Esophagus, foreign body, surgery

INTRODUCTION

Esophageal foreign bodies are matters or food items of a diameter larger than that of the esophageal lumen that do not fit into the esophagus in size or in form, thus blocking the lumen. Rather than the blockage itself, the main problem is the mediastinitis caused by esophagus perforation. Perforation of the esophagus has poor prognosis. Mortality rates about more than 50% in the first one to two days (1, 5).

Flexible and rigid esophagoscopy, catheterization, and endoscopy with bougie are common techniques used to remove the foreign bodies (2, 6, 8). The success rates of these techniques are around 80%. The remaining cases require surgical intervention (3, 7). A new surgical technique applied on a case with a large-sized esophageal foreign body is presented.

CASE REPORT

A 25-year-old male applied to the emergency department with the complaint of difficulty in swallowing for the last couple of days. He had the complaints of dysphagia and inability to swallow saliva. The size of the foreign body was about 4-5 cm in diameter. It was located in the upper esophagus narrowing.

He was mentally retarded. The physical examination was unremarkable. Postero-anterior chest radiograph revealed a stone in the upper one-third of the esophagus (Figure 1). On the direct abdominal radiograph obtained in standing position, there were multiple stones in his abdomen (Figure 2). The endoscopy revealed that the stone was located at the 15th cm of the esophagus and had caused complete obstruction of the cervical esophagus. Although the endoscopist tried various manipulations, the stone could not be removed. Therefore,

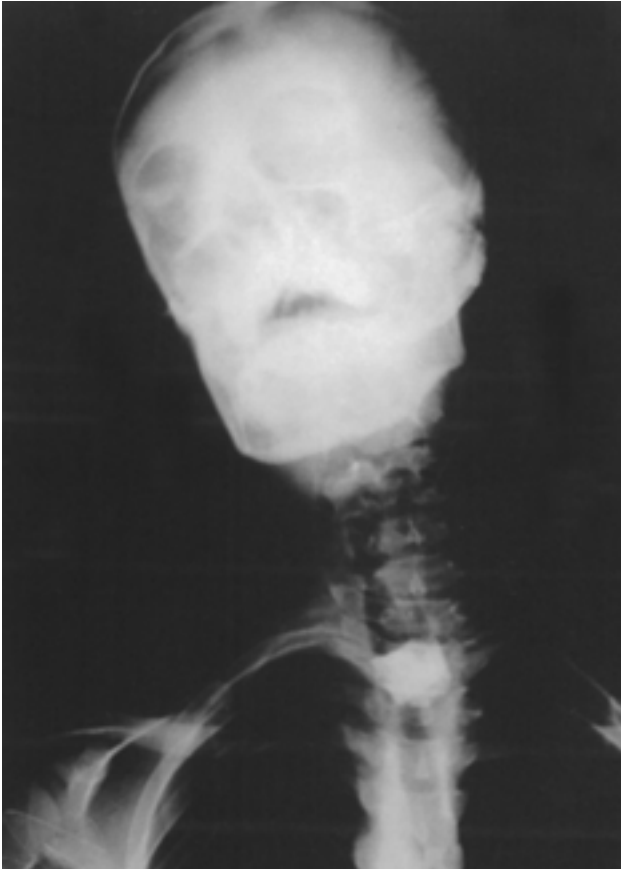

Figure 1. Postero-anterior cervical radiograph

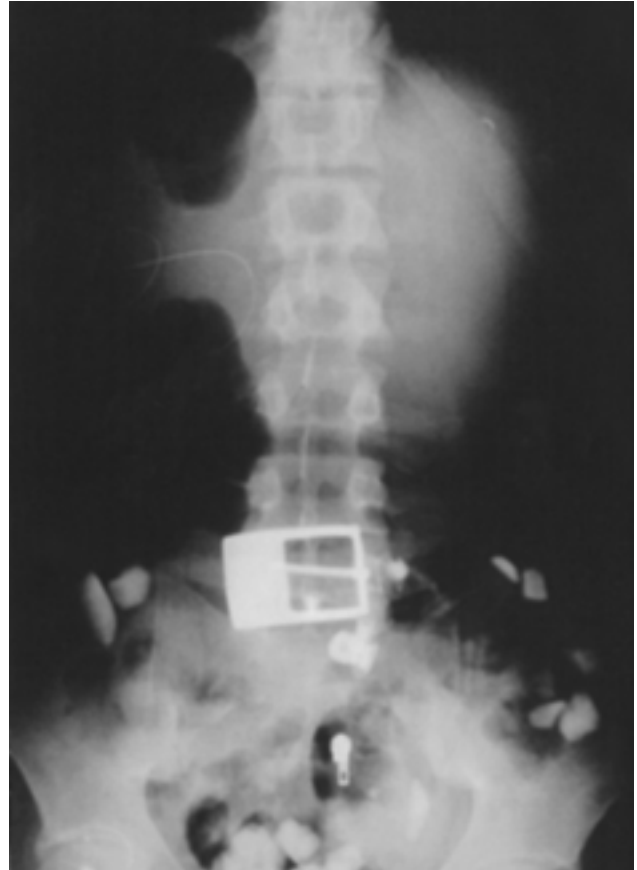


Figure 2. Direct abdominal radiograph

an open surgical intervention was decided as the treatment method.

A midline incision was performed to access the abdomen. A 2 cm gastrostomy incision was performed through the stomach corpus at a location where it would be across from the cardia of the esophagus. Guide-wire was introduced into the lumen of the esophagus through the incision and a long and dull silicone-tipped tube was inserted using Seldinger method. The patient's mouth was kept open with laryngoscope to control the upper esophageal sphincter of the esophagus, and the stone was pushed up with the silicone tube inserted into the esophagus from the stomach. The stone was pushed into the hypopharynx, where it was retrieved by a forceps. Following the removal of the stone, the esophageal mucosa was examined thoroughly by esophagoscopy, and no damage was observed.

The chest X-ray and all the routine examinations revealed normal findings after the operation. On the third postoperative day, enteral feeding was initiated and the patient was discharged without any problems on the fifth postoperative day.

DISCUSSION

Esophageal foreign bodies can be evaluated in four different categories: oblivious swallowing by children or psychiatric patients of foreign bodies; accidents; blockage due to an obstruction or narrowing of esophagus; and distal esophagus blockage due to over-consumption of meat, also termed as "steak house" syndrome (1, 8, 9). Our case was a mentally retarded patient who obviously swallowed a large-sized stone causing complete obstruction of the cervical region.

The physical findings and symptoms of aspirations caused by foreign body vary, depending on the location, tissue reaction, and the size, form, and the constitution of the object. It is usually presented with dysphagia or inability to swallow saliva in children, and is often mistaken for odynophagia, symptoms such as pain in the retrosternal region and the back, angina pectoris, and cardiovascular injuries. Additional findings may be present in case of complications. The obstruction usually occurs at cricopharyngeal cartilage, arcus aortae and/or diaphragmatic hiatus levels. Particularly

in small children, esophageal foreign bodies may mimic airway foreign bodies by causing external pressure on the airway. In case of perforation and mediastinitis, the patient must be immediately hospitalized and prepared for operation. One of the early symptoms of mediastinitis is supraclavicular subcutaneous emphysema (4-7).

Postero-anterior, lateral cervical and chest radiographs are basic radiological methods of foreign body detection. Since most foreign bodies are radiolucent, for nonopaque objects, indirect findings such as larynx and tracheal deviation, as well as computerized tomography, can aid in the diagnosis (3, 5, 8). In our case, the foreign body was a stone and could be easily and clearly imaged by the direct radiograph.

Foreign bodies should be removed in a previously set up and fully equipped operation theater with resuscitation equipment. Despite the recent advances in anesthesia and instrumentation, foreign bodies remain challenging even to highly skilled and experienced endoscopists. Complications still arise, mostly because of delayed diagnosis, incorrect choice of instruments or technique, and lack of communication between the surgeon and the anesthetist (4, 5). In our case, various techniques had been used by experienced endoscopists, but upon realizing complication risks, open surgery was planned.

Children and psychiatric patients may swallow objects with sharp edges such as nails, razors, and dental prostheses, which are difficult to remove.

These kinds of foreign bodies may often proceed as far as the stomach without any complication. However, they may lead to obstructions and perforation in the thoracic esophagus, gastroesophageal junction, or hypopharynx (3, 6). Though cervical esophagomyotomy is a classical operation method for this location, because of the cervico-thoracic localization, this classical operation was not sufficient for this case. On the other hand, we could have tried to push the foreign body to the stomach with rigid endoscopy, but this procedure may have led to the possible etiology of esophageal perforation by the sharp-edged stone. In our case, the large and sharp-edged stone was located near the cervical region, and with concerns of possible severe complications if pushed into the stomach, the retrograde method was the treatment of choice to remove the foreign body, which yielded the desired outcome. Thus, this technique as described could prove to be safe and effective in other similar cases; this style of procedure is rare in the literature.

In conclusion, endoscopic removal of foreign bodies is a well-established technique. However, the condition may have indications for surgical intervention, and it should be regarded as a technique of choice with no hesitation in the more challenging cases. The cervical esophageal foreign bodies that cannot be removed endoscopically are usually pushed into the stomach and removed through laparotomic gastrostomy. The technique used in this patient was proven effective and safe; it might have been used for the first time in the literature.

REFERENCES

1. Athanassiadi K, Gerazounis M, Metaxas E, et al. Management of esophageal foreign bodies: a retrospective review of 400 cases. *Eur J Cardiothorac Surg* 2002; 21: 653-6.
2. Bendig DW. Removal of blunt esophageal foreign bodies by flexible endoscopy with general anesthesia. *Am J Dis Child* 1986; 140: 789.
3. Webb WA. Management of foreign bodies of the upper gastrointestinal tract: update. *Gastrointest Endosc* 1995; 41: 39-50.
4. Al-Qudah A, Daradkeh S, Abu-Khalaf M. Esophageal foreign bodies. *Eur J Cardiothorac Surg* 1998; 13: 494-9.
5. Singh B, Kantu M, Har-El G, et al. Complications associated with 327 foreign bodies of the pharynx, larynx and esophagus. *Ann Otol Rhinol Laryngol* 1997; 106: 301-4.
6. Ginsberg GG. Management of ingested foreign bodies and food bolus impactions. *Gastrointest Endosc* 1995; 41: 33-8.
7. Herranz-Gonzalez J, Martinez-Vidal J, Garcia-Sarandese A, et al. Oesophageal foreign bodies in adults. *Otolaryngol Head Neck Surg* 1991; 105: 649-50.
8. Cambell JB, Foley LC. A safe alternative to endoscopic removal of blunt esophageal foreign bodies. *Arch Otolaryngol* 1983; 109: 323-5.
9. Bergreen PJ, Harrison ME, Sanowski RA, et al. Techniques and complications of esophageal foreign body extraction in children and adults. *Gastrointest Endosc* 1993; 39: 626-30.