

Evaluation of malignancy risk and endoscopic follow up in achalasia: Case report

Akalazyada malignite riskinin ve endoskopik takibin bir vaka nedeni ile değerlendirilmesi

Filiz AKYÜZ¹, Duygu İBRİŞİM¹, Emre BALIK², Oya YONAL¹, Sabahattin KAYMAKOĞLU¹, Dursun BUĞRA², Zeynel MÜNGAN¹

Department of ¹Gastroenterohepatology, ²General Surgery, İstanbul University, İstanbul Medical Faculty, İstanbul

Achalasia is an esophageal motility disorder that is accepted as a risk factor for the development of cancer. Especially in megaesophagus, chronic irritation of foods and bacterial overgrowth may contribute to the formation of high-grade dysplasia and squamous cell carcinoma. We present a case of advanced stage achalasia with high-grade dysplasia detected three years after a cardiomyotomy operation. Cancer risk continues after surgical operation in achalasia, like in this case. In conclusion, endoscopic follow up is necessary for these patients even after surgical treatment.

Key words: Achalasia, cancer, endoscopic follow up

INTRODUCTION

Achalasia is an esophageal motility disorder predominantly presented with dysphagia, sometimes with regurgitation and complications of this disease. Although there is no cure for achalasia, the aim of the treatment should be palliation of symptoms and improvement in esophageal emptying. The most effective treatments are pneumatic balloon dilatation and cardiomyotomy. Botulinum injection or calcium channel blockers are the other options for the treatment of patients who are at high risk for pneumatic balloon dilatation and cardiomyotomy (1-3). The most important complication is the development of esophageal cancer. The esophageal cancer development risk is 1.7-20% in achalasia (4). Patients have similar symptoms in achalasia and esophageal cancer; therefore, most of the cancer cases are diagnosed at advanced stage. Prognosis of cancers due to achalasia is very poor. In achalasia, either adenocarcinoma or squ-

Akalazyada, kanser gelişimi için risk faktörü olarak kabul edilen özofagusun motilite bozukluğu ile ilişkili bir hastalıktır. Özellikle megaözofagusda, lümen içindeki gıdaların kronik iritasyonu ve bakteriyel aşırı gelişim yüksek dereceli displazi ve skuamöz hücreli karsinom gelişimine zemin hazırlayabilir. Bu yazıda kardiyomyotomi operasyonundan 3 yıl sonra yüksek derecede displazi saptanan ileri dönemdeki bir akalazyada vakasını sunuyoruz. Kanseri riski, bu vakada görüldüğü gibi operasyon sonrasında da devam etmektedir. Sonuç olarak cerrahi tedaviden sonra bile endoskopik takip gereklidir.

Anahtar kelimeler: Akalazyada, kanser, endoskopik takip

amous cell carcinoma may develop (4-6). In untreated patients, food retained for a long time can cause putrefaction, bacterial overgrowth and increase of nitrosamine, following which dysplasia and squamous cell carcinoma may arise (4). In this paper, we present a case of advanced stage achalasia in whom a high-grade dysplasia developed three years after cardiomyotomy, and we review endoscopic follow up in achalasia cases.

CASE REPORT

A 43-year-old man was admitted to our hospital with the complaints of dysphagia, sometimes chest pain and weight loss. Dysphagia, vomiting and cough began 10 years ago, but he was admitted to hospital because of the increasing severity of his symptoms four years ago, and the diagnosis of achalasia was made. The patient was treated with open cardiomyotomy. His symptoms partially

Address for correspondence: Filiz AKYÜZ
Şakacı Sokak. Birlik Apt. No: 43/6 Kazasker, 81090, İstanbul, Turkey
Phone: +90 216 463 03 25 • Fax: +90 212 631 97 43
E-mail: filizakyuz@hotmail.com

Manuscript received: 01.06.2005 **Accepted:** 27.10.2005

regressed after surgery and he did not go to follow-up examinations. Three years after cardiomyotomy, weight loss (10 kg in 5 months) was added to severe dysphagia, vomiting and chest pain. He was in a cachectic (body mass index 13.8 kg/m²) status and there was a skin pallor in physical examination; other systems were normal. Laboratory analyses were as follows: hemoglobin: 7.6 g/dl, hematocrit: 28.5%, mean corpuscular volume: 60fl, platelets: 524000/mm³, serum iron: 11 mcg/dl, total iron-binding capacity: 348 mcg/dl, and ferritin: 1.33 ng/ml. Other laboratory tests were normal. Mediastinal enlargement was seen in chest X-ray (Figure 1). During gastroscopy, esophagus was full

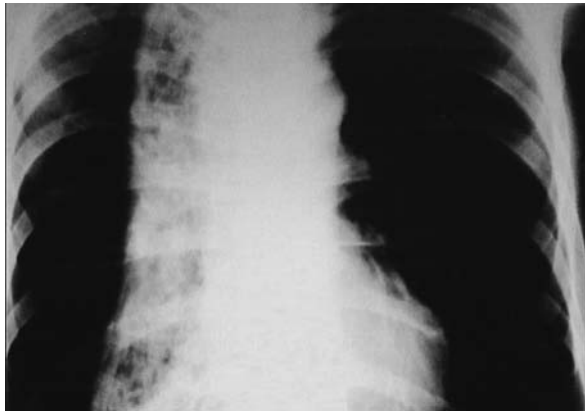


Figure 1. Mediastinal enlargement in chest X-ray

with retained food and it was impossible to reach the esophagogastric junction because of the tight stricture. Barium X-ray revealed S-shaped dilated esophagus (Figure 2) and computerized thorax tomography showed diffuse concentric thickness at gastroesophageal junction and severe esophageal dilatation. Liquid material (1 L) including retained food was drained by 18F esophageal tube. Mediastinal enlargement related to megaesophagus disappeared on chest X-ray after decompression. Oral feeding was stopped and parenteral nutritional support was started. Esophageal manometry was performed. The catheter was replaced under endoscopic view. First, a guide-wire was inserted through the stenotic esophagogastric junction by endoscopy and then a manometry catheter was replaced. A direct radiogram was performed to control the localization of the catheter. His esophageal manometry was also compatible with achalasia [simultaneous contractions and absence of lower esophageal sphincter (LES) relaxation].

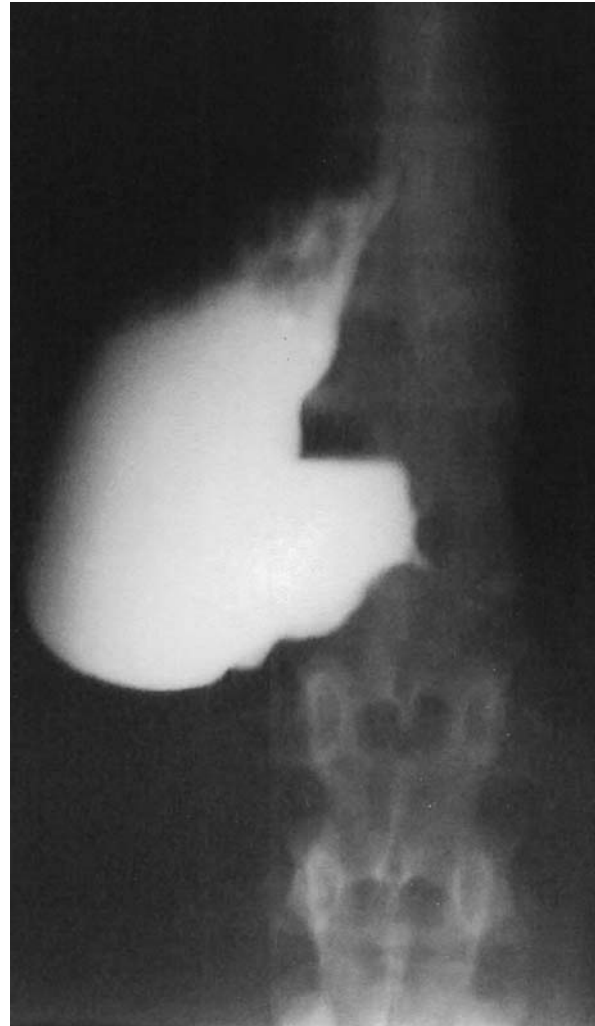

Figure 2. S-shaped dilated esophagus in barium X-ray

In the second look gastroscopy after decompression, there was a stenotic segment in the distal esophagus and the esophagogastric junction was not reached. Multiple biopsies were taken from distal esophagus; focal high-grade dysplasia was detected on histopathologic examination. The patient was hospitalized at the department of surgery. For nutritional support, the patient was operated after his admission, and jejunal feeding tube was inserted in open laparotomy. After three weeks of enteral and parenteral nutritional support, the patient gained 5 kg, and biochemical parameters and blood count were normal. The patient was informed about his disease status and total esophagectomy with thoracotomy was suggested. After obtaining consent of the patient, total esophagectomy with right thoracotomy was performed

(Figure 3). Gastrointestinal continuity was achieved with pharyngo-gastrostomy. Postoperative course was uneventful and the patient started to consume a regular diet on the 7th postoperative day. The patient was discharged on the 13th postoperative day after removal of the jejunal feeding tube. He is followed regularly and there has been no nutritional problem as of the end of the first year. Histopathologic examination of the specimen revealed high-grade dysplasia on the distal end of the esophagus.

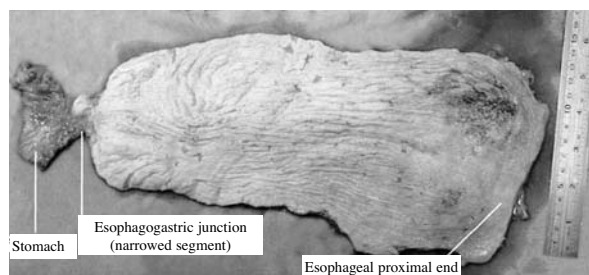


Figure 3. Postoperative view of the resected esophagus

DISCUSSION

The relationship between achalasia and cancer was first described in 1872 by Fagge (7). Recently, there is a common view that achalasia is a precancerous lesion, but there is still no accepted endoscopic long-term follow up protocol for achalasia. In megaesophagus seen in the late phase of achalasia, chronic irritation of foods and bacterial overgrowth cause epithelial proliferation of the mucosa and may trigger carcinogenesis (8). Esophageal emptying partially improves after cardiomyotomy, but it does not become normal because of the aperistalsis of the esophagus body (9). For this reason, cancer risk is still higher after cardiomyotomy compared with the normal population due to continuous chronic irritation. In our case, high-grade dysplasia was detected three years after a cardiomyotomy operation. Endoscopic view of gastroesophageal junction resembled a malignant stricture, but histological examination of endoscopic biopsy and postoperative specimens revealed only high-grade dysplasia. Thus, we thought the stricture of the gastroesophageal junction was related to unsuccessful surgery rather than malignancy.

Failure of treatment in achalasia is higher than expected. Achkar *et al.* (10) evaluated achalasia patients four years following cardiomyotomy and

pneumatic balloon dilatation, and they found a much higher failure rate than expected. This can be related to the absence of routine follow up programs, late admission to hospital after a long symptomatic period and to ineffective treatment modalities. Because of high cancer risk in advanced stage achalasia, esophagectomy should be the first choice of treatment, as in our patient. Cancer development must be suspected in patients admitted to hospital with recurrent dysphagia after cardiomyotomy, especially in the presence of megaesophagus.

Aggestrup *et al.* (11) evaluated 147 achalasia patients at the end of 23 years (6-41) mean follow up and reported that mortality caused by esophageal cancer rate was 66% after 30 years. Esophageal cancers are generally diagnosed in advanced stage because achalasia and esophageal cancer have similar symptoms and because 80% of patients are inoperable when they are diagnosed (4). Therefore early diagnosis is very important. Lugol dye endoscopy can help to detect dysplasia or carcinoma earlier than conventional endoscopic examination (12). A follow-up program may be developed for high-risk patients (age, cigarette, alcohol, p53 gene mutation detected by immunohistochemical analysis, flow cytometric DNA analyses) (13). Sandler *et al.* (14) reported that mean age at entry was 57.2 and mean age at cancer diagnosis was 71 years in the analyses of 1062 achalasia patients. They showed that there was a high risk of cancer development after the diagnosis of achalasia and suggested regular endoscopic follow up.

In our case, surgical therapy was preferred because of the presence of sigmoid esophagus and severe symptoms related with achalasia. Detection of high-grade dysplasia also supported the choice of surgical therapy. Thus we did not need to confirm high-grade dysplasia with a second endoscopy and immunohistochemical examination.

Endoscopic mucosal resection can be suggested in the treatment of high-grade dysplasia. Most reports about this subject are related to Barrett's esophagus. However, an invasive cancer was detected in 30 to 40% of cases with high-grade dysplasia who underwent surgery (15). There is no data about mucosal resection for the treatment of high-grade dysplasia in sigmoid esophagus of achalasia.

In the light of these results, achalasia patients must followed up regularly. Evaluating patients

with objective rather than subjective data may be helpful in early diagnosis and treatment. Endoscopic control should be performed in the first year after the diagnosis of achalasia and repeated every

four years in the follow-up period, even after all types of treatment. Lugol dye endoscopy may also help in early diagnosis and decrease the morbidity and mortality in high-risk patients.

REFERENCES

1. Vaezi MF, Richter JE. Diagnosis and management of achalasia. *Am J Gastroenterol* 1999; 94: 3406-12.
2. Parkman HP, Reynolds JC, Ouyang A, et al. Pneumatic dilatation or esophagocardiomyotomy treatment for idiopathic achalasia: clinical outcomes and cost analysis. *Dig Dis Sci* 1993; 38: 75-85.
3. Urbach DR, Hansen PD, Khajanchee YS, Swanstrom LL. A decision analysis of the optimal initial approach to achalasia: laparoscopic Heller cardiomyotomy with partial fundoplication, thoracoscopic Heller cardiomyotomy, pneumatic dilatation, or botulinum toxin injection. *J Gastrointest Surg* 2001; 5: 192-205.
4. Brücher BLD, Stein HJ, Bartels H, et al. Achalasia and esophageal cancer: incidence, prevalence and prognosis. *World J Surg* 2001; 25: 745-9.
5. Guo JP, Gilman PB, Thomas RM, et al. Barrett's esophagus and achalasia. *J Clin Gastroenterol* 2002; 34: 439-43.
6. Ellis FH Jr, Gibb SP, Balogh K, Schwaber JR. Esophageal achalasia and adenocarcinoma in Barrett's esophagus: a report of two cases and a review of the literature. *Dis Esophagus* 1997; 10: 55-60.
7. Fagge CH. A case of simple stenosis of the oesophagus, followed by epithelioma. *Guy's Hosp Rep* 1872; 17: 413.
8. Pajeccki D, Zilberstein B, dos Santos MA, et al. Megaesophagus microbiota: a qualitative and quantitative analysis. *J Gastrointest Surg* 2002; 6: 723-9.
9. Liu JF, Zhang J, Tian ZQ, et al. Long-term outcome of esophageal cardiomyotomy for achalasia. *World J Gastroenterol* 2004; 10: 287-91.
10. Achkar E, Richter J. Diagnosis and follow-up of patients with achalasia. *Am J Gastroenterol* 2003; 98: 696-7.
11. Aggestrup S, Holm JC, Sorensen HR. Does achalasia predispose to cancer of the esophagus? *Chest* 1992; 102: 1013-6.
12. Yamamuro EM, Ceconello I, Iriya K, et al. Lugol dye endoscopy for analysis of esophageal mucosa in achalasia. *Hepatogastroenterol* 1999; 46: 1687-91.
13. Farr CM. Achalasia and esophageal carcinoma. *Am J Gastroenterol* 1994; 89: 1600-1.
14. Sandler RS, Nyren O, Ekblom A, et al. The risk of esophageal cancer in patients with achalasia: a population based study. *JAMA* 1995; 274: 1359-62.
15. Spechler ST. Dysplasia in Barrett's esophagus: limitations of current management strategies. *Am J Gastroenterol* 2005; 100: 927-35.