

Image-based assessment of esophageal stricture in experimental corrosive esophagitis in animals: An objective, adjunct diagnostic tool

Deney hayvanlarında oluşturulan korroziv özofajitlerdeki özofageal darlıkların görüntü analizi ile belirlenmesi: Objektif tanıya yardımcı bir araç

Enver VARDAR¹, Rukiye VARDAR², Vahit YÜKSELEN³, Özer MAKAY⁴, Nazif ERKAN⁵, Ümit BAYOL¹, Ömer ÖZÜTEMİZ²

Department of ¹Pathology, Tepecik Research and Training Hospital, İzmir

Departments of ²Gastroenterology and ⁴General Surgery, Ege University, School of Medicine, İzmir

Department of ³Gastroenterology, Adnan Menderes University, School of Medicine, Aydın

Department of ⁵General Surgery, Bozyaka Research and Training Hospital, İzmir

Background/aims: Many studies have reported image analysis techniques, such as nuclear morphometry, counting or calculating of mitotic figures or estimation of the ratio of positive-stained areas immunohistochemically. The esophagus is the most commonly involved organ during caustic ingestion, which leads to progressive and devastating results after caustic burn. The aim of this work was to compare the classical stenosis index method with a new objective method based on image analysis that was used to determine experimental stricture of the rat esophagus. **Methods:** We investigated this technique by randomly allocating 20 rats each to sham laparotomy and corrosive esophagitis groups. The images of the sham laparotomy group and corrosive esophagitis group were reviewed, analyzed and used in a mathematical operation on the computer. The numbers and the ratio of luminal area and total esophageal area were used to determine the esophageal stricture of the rat, and results were compared with stenosis index ratios. **Results:** The mean area of the lumen of the esophagus and the ratio of esophageal lumen / total esophageal area were 0.83 (0.51-1.28) mm² and 0.21 (0.08-0.37), respectively, in the corrosive esophagitis group. In the sham laparotomy group, these values were 1.28 (0.47-3.03) mm² and 0.26 (0.13-0.92), respectively. The differences between the two groups in luminal area and ratio of esophageal lumen / total esophageal area were statistically significant (p<0.05). **Conclusions:** This new technique based on image analysis seems more objective and reproducible than the classical, manual method. It is concluded that the use of this new technique dramatically reduced the subjectivity of the measurement process.

Key words: Image analysis, esophageal stricture

INTRODUCTION

After the integration of computer into medical sciences, studies related with morphometry were

Amaç: Nükleer morfolometri, mitotik figürlerin sayımı veya hesaplanması veya immünohistokimyasal olarak pozitif boyanan alanların oranını belirlemek gibi görüntü analizi teknikleri ile yapılmış çok sayıda çalışma vardır. Özofagus, koroziv yanığın yol açtığı ilerleyici ve hasarlayıcı sonuçlara neden olabilen koroziv madde alımı sırasında en sık etkilenen organdır. Bu çalışmanın amacı, ratlardaki deneysel özofagus striktürlerinin saptanmasında kullanılan klasik stenosis indeksi yöntemi ile görüntü analizi esaslı yeni objektif yöntemin karşılaştırılmasıdır. **Yöntem:** Sham laparotomi yapılmış ve koroziv özofajit oluşturulmuş 2 gruptan random seçilen 20'şer rat üzerinde bu tekniği araştırdık. Sham laparotomi ve koroziv özofajitli grupların bilgisayardaki görüntüleri gözden geçirilip, analiz edilerek matematiksel işlemlerde kullanıldı. Lüminal alan / total özofagus alanı oranı ve sayısı ratlarda özofagus striktürünü belirlemede kullanıldı ve stenosis indeksi ile karşılaştırıldı. **Bulgular:** Koroziv özofajitli grupta, ortalama özofageal lümen alanı ve özofagus lümeni / total özofagus alanı sırasıyla 0.83 (0.51-1.28) mm² ve 0.21 (0.08-0.37) olarak hesaplandı. Diğer taraftan sham laparotomi yapılmış olan grupta ortalama özofageal lümen alanı ve özofagus lümeni / total özofagus alanı sırasıyla 1.28 (0.47-3.03) mm² ve 0.26 (0.13-0.92) idi. Lüminal alan ve özofageal lümen / total özofageal alanlarının değerleri karşılaştırıldığında iki grup arasındaki fark istatistiksel olarak anlamlıydı (p<0.05). **Sonuç:** Görüntü analizinin baz alındığı yeni yöntem klasik manuel yöntemden daha objektif ve tekrarlanabilir gibi görünmektedir. Yeni yöntemin hesaplama sürecinin subjektifliğini dramatik olarak azalttığı sonucuna varılmıştır.

Anahtar kelimeler: Görüntü analizi, özofageal darlık

published; these studies were later performed with superimposed test-grids and by counting the

Address for correspondence: Enver VARDAR

915 Sok. No: 172 Yeşil Evler Sitesi

Osmangazi Bornova, İzmir, Turkey

E-mail: vardaren@superonline.com

Manuscript received: 06.11.2008 **Accepted:** 07.01.2008

points of the areas examined. Finally, stereology then provided data related with three dimensions by using the measurements determined from microscopic pictures. It has been demonstrated by extensive experimentation, using real image data, that the proposed strategy is fast and robust in the environment of a personal computer (PC) (1-3). Further, these images that are stored in the PC will be subject to a further histological or morphometric analysis. Many studies have been performed using image analysis techniques such as nuclear morphometry or by counting or calculating mitotic figures or positive-stained areas (1-3).

The esophagus is the most commonly involved organ in caustic ingestion, which leads to progressive and devastating results after caustic burn. Esophageal stricture is a serious and continuing problem, since preventive strategies especially for the child, psychotic patient and the drug-addicted are inadequate. Due to the probability of stenosis following the ingestion of corrosive agents, many studies have investigated prevention of esophageal stricture (4-7).

There are many serious problems related with the methods used in the assessment of stricture and efficiency of the treatment methods in the studies of experimental corrosive esophagitis. At present, no objective and reproducible criteria are being used to estimate the severity of the corrosive agents' effect and efficacy of the drugs in esophageal experimental studies. Determination of muscularis mucosa and muscularis propria and fibroblastic proliferation in addition to stenosis index (SI) are the criteria used to estimate the injury and efficacy of therapy. SI has been used to determine the stricture and efficacy of the treatment in the experimental studies related with corrosive esophagitis. The formula of the SI is $[SI = ((A1 + A2) : 2) : B]$. Determination of the axis or direction to be used in the calculation of the SI is variable and depends completely on personal experience and even predilection. There is no gold standard method to describe the condition of the esophagus. We observed these difficulties in our studies published previously (4-6).

Determining the starting and ending points of the axis of the line to be used in measurement of the SI is the basic source of the problem. As in Figure 1, if we select line A1, A2 for wall thickness and B1 for luminal diameter to determine the SI, a larger ratio is obtained than would be calculated for A3, A4 and B2 for wall thickness and diameter,

respectively. Because of the presence of subjectivity in the measurement of SI via this technique, we propose an alternative and objective method based on only measuring the area of the esophagus lumen with image analysis software (ImageJ, version 1.38x) instead of SI. ImageJ is an image analysis software and freely available for download on the web (8). The aim of this work is the comparison of the classical assessment method with the new objective method based only on figures that are used to determine the stricture of the esophagus. Final results of this new technique were compared with the results obtained by classical methods.

Classical determination of the esophageal stricture using variable means requires some standardization. There are many difficulties related with measuring the thickness of the wall of the esophagus, especially in the determination of the axis of the esophageal wall and starting or ending points of the axis. Our technique is based on two algorithms that process digital color images for extracting the morphometric features as two types: (A) luminal area of esophagus and (B) ratio of luminal area to total esophageal area.

This technique offers a reliable and repeatable high level of automation. The extraction of morphometric features of the lumen and the wall of the esophagus allows for establishing a significant correlation between the quantitative and qualitative information related with the esophagus and clinical status of the rats. This may contribute to a better understanding of corrosive esophagitis and




Figure 1. Different luminal widths and wall thicknesses were seen in the two axes of the image (Van Gieson stain x4).

esophageal stricture evolution and, implicitly, to determination of the therapy. We present herein an original computerized histometric technique for esophageal stricture assessment that outlines the role of quantitative information in the morphologic analysis of the luminal area of the esophagus.

ImageJ is the most vital biomedical image processing software since 1987 on Mac, multi-platform in Java since 1997, and it is interactive, programmable (macro and Java), usable as applet, and usable as library for other software.

MATERIALS AND METHODS

We investigated this technique on rats by randomly selecting 20 rats each for sham laparotomy and corrosive esophagitis groups. Basically, this study is based on the images of previous three studies, which were randomized, controlled and experimental (4-6). Histological sections of esophageal specimens were obtained from 40 male Wistar albino rats with a mean body weight of 250–300 g and with a median age of 8-10 months. All were housed in groups of 10 in an identical wire-bottomed cage with a 12 h day–night cycle at a constant room temperature of $24 \pm 1^\circ\text{C}$. The animals were acclimatized to these conditions for 10 days before the experiment. Standard rat food and water were freely available. All rats were treated according the “UFAW Handbook on the Care and Management of Laboratory Animals” (9) and “Guide for the Care and Use of Laboratory Animals” (NIH publication) (10). The protocol of these studies was approved by Ege University Animal Ethics Committee and Ege University, Department of Experimental Surgery.

The rats were randomized into the following groups according to the procedure and treatment to which each was subjected:

1. Group A, the sham laparotomy group, was instilled only with 0.9% saline after preparation of the distal esophagus.
2. Group B, the corrosive esophagitis group, underwent caustic esophageal burn with 37.5% NaOH.

The esophageal lumen was washed out with 2 ml of 0.9% saline and abdominal esophagus plus stomach were removed en bloc. The abdominal esophagus segment was transversally sectioned into two equal parts. The proximal portion was resected and fixed in 10% neutral buffered formaldehyde and embedded in paraffin after tissue process.

Pathologic Examination

Histopathologic analyses were performed in groups A and B. Four slides from each rat esophagus, each 4 micrometer in thickness, were obtained and stained with hematoxylin–eosin (H-E) and Van Gieson stain. The slides were examined microscopically and images were acquired with a Nikon Coolpix 995 attached to the microscope with C-mount adapter for histopathological damage score. All pictures were taken on the same appropriate photographic settings. For the computerized quantitative analysis, we used digital color images of microscopic fields from sections of the esophagus stained with Van Gieson stain, since this stain has more contrast than classical H-E stained sections. The images of the sham laparotomy group and corrosive esophagitis group were reviewed, analyzed and used in mathematical operations on the computer. Before starting the calculation of luminal area and total esophageal area, an image was captured of a translucent ruler with the same thickness of the slide. Using two lines of the ruler that reflect millimeter, calibration of the distance was performed. A millimeter (mm) was equal to 376 pixel, and a square with dimension of 1 mm x 1 mm was equal to $(376 \times 376 \text{ pixel} = 1 \text{ mm}^2 =) 141.376 \text{ pixel}$. Before using these figures as reference point in calculation of the esophageal luminal area, they were calculated and checked with DP2-BSW software attached on Olympus BX-51 light microscope. These figures were used in all calculations after this confirmation.

The calculation is based on segmentation, yielding binary images used for measurements. Each of the considered images comprised only one transverse section of the esophagus. The colorful images were firstly converted into 8 bit form (white-black) (Figure 2), and then threshold procedure was applied in all images on the same settings (Figure 3). After digitizing of the images, luminal area was selected with wizard function of ImageJ software (version 1.38x) (Figure 4). If the wizard function was not successful in the selection of luminal area for any reason, the selection procedure of the area was finished simply with freehand selection. After selection of the luminal area, “measure” command was selected from the “analyze” menu. The second step was selection and calculation of the total esophageal area, similar to luminal area. The numbers and the ratio of luminal area/total esophageal area were used to determine the esophageal status of the rat and values were compared

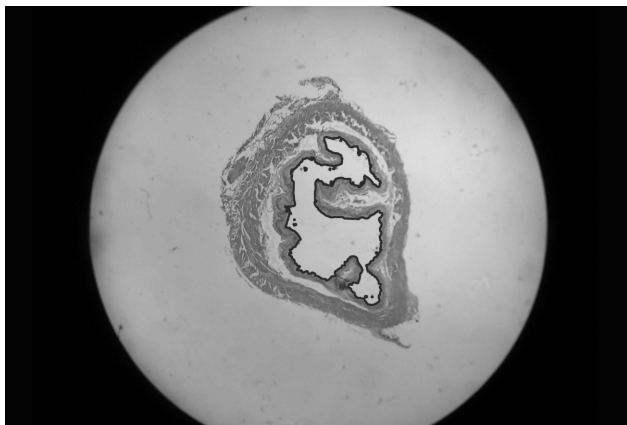


Figure 2. Classical light microscopic view of cross-section of the esophagus and the used in quantitative analysis. Luminal area was selected with the wizard function and highlighted with bold line (gray-scale converted of Figure 1).




Figure 3. Binary image corresponding to esophageal lumen of the same esophageal section.

with ratios of the SI. SIs were calculated with the formula given above. Light microscope examination and morphometric analysis were carried out by two pathologists (E.V., Ü.B.) independent of the status of the rat.

Statistical Analysis

Statistical analyses were carried out using the SPSS software package (version 10, SPSS Inc, Chicago, IL). *p* values less than 0.05 were regarded as significant. Mann-Whitney U or Kruskal-Wallis test was used to test statistical differences between the clinicopathologic parameters and the SI and the ratio of luminal area to total area of the esophagus.

RESULTS

The distribution of papillary infolding and the contour of the esophageal lumen in corrosive esophagitis vary from case to case and area to area.



Figure 4. Binary image corresponding to esophageal lumen of the same esophageal section.

Analysis of reliability and repeatability of the proposed technique: Basically, quantitative measurement of esophageal lumen (QMEL) extracts the following two morphometric features of an esophageal lumen (absolute values expressed in mm²): 1) luminal area and 2) the ratio of luminal area / total esophageal transverse section area. Mean area of the lumen of the esophagus (Table 1), and the ratio of esophageal lumen/total esophageal area were 0.83 (0.51-1.28) mm² and 0.21 (0.08-0.37), respectively, in the corrosive esophagitis group. In the sham laparotomy group, on the other hand, mean area of the esophageal lumen and the ratio of esophageal lumen/total esophageal area were 1.28 (0.47-3.03) mm², and 0.26 (0.13-0.92), respectively. Statistically significant differences were seen related with the value of the area of the esophageal lumen between the corrosive esophagitis and sham laparotomy groups (*p*<0.05). Mean SIs were 1.06 (0.54-1.67) in the corrosive esophagitis group and 0.63 (0.34-1.22) in sham laparotomy group (Table 2), and the difference between groups was also statistically significant (*p*<0.05).

DISCUSSION

The histopathological and morphological aspects of esophageal strictures are important in experimen-

Table 1. Mean esophagus luminal area (mm²) calculated with new computer based method in sham and corrosive esophagitis groups (*p*<0.05).

	Esophageal luminal area-mm ² -New computer based method- (Min-Max)
Sham laparotomy group (n:20)	1.28 (0.47-3.03)
Corrosive esophagitis group (n:20)	0.83 (0.51-1.28)

Table 2. Mean stenosis index results in classic stenosis index method ($p < 0.05$).

	Stenosis index method [SI= ((A1 + A2):2):B] (Min-Max)
Sham laparotomy group (n:20)	0.63 (0.34-1.22)
Corrosive esophagitis group (n:20)	1.06 (0.54-1.67)

tal procedures (4-7). Computer-assisted quantitative image analysis is a method of assessing computerized images of histological preparations (1-3). The ability to study luminal area quantitatively has been made possible by advances in computer imaging technology. A few experimental studies on caustic burns of the esophagus have been attempted (4-7). These investigators have used a variety of animal species with widely varying esophageal strictures.

Manual delineation has been used in many morphometric studies, not only in esophageal pathology. For our purpose, it seems subjective, inadequate and time-consuming because of extremely numerous elements that need to be carefully measured. We developed this technique in the determination of esophageal stricture, since to date no technique has emerged as the gold standard. The new computer-based esophageal luminal area calculating method as proposed in this manuscript appears to be more objective than the classical SI method. Additionally, the reproducibility of the proposed new computer-based technique is different and more easily applicable than the old classical SI calculating technique.

The difficulties lie mainly in the determination of the starting and ending points of axes that will be used in calculating the SI. The issue of "which one of the tips and which one of the papillary structures of the squamous epithelium will be used" is very important. We demonstrated by extensive experimentation, using real image data, that the proposed technique is fast and robust in the PC environment. These images may also be subjected to any other morphometric analysis.

The analysis was done on images digitized from Van Gieson stain applied in histological sections using an automated multiple thresholding for segmenting the luminal area from the epithelium and stromal area. However, this technique can also be easily applied to routine H-E stained sections. In

contrast with the SI method, this method does not permit making subjective or faulty determination of the esophageal lumina. In the SI method, there is difficulty in the determination of the tips and pits of the esophageal luminal surface. As a result, thickness of the esophageal wall or diameter of the esophagus may be highly variable. Also, due to the variability of these figures, SI calculations may not be true.

Also, instead of planometer, image analysis based technique can be used on images taken from a variety of sites, including any ulcer or specific distinct area (e.g. more red area) to facilitate calculation of these figures taken from the stomach, intestine and skin etc, objectively and easily.

Lee et al. (1) used ImageJ software to calculate the nuclear scores and the numbers of nuclear grooves or inclusions per 5000 tumor cells of each case in order to determine the clinicopathologic significance of nuclear grooves and inclusions in variants like clear cell carcinoma, chromophobe and papillary types of renal cell carcinoma. In their preliminary study, Ozdamar et al. (3) studied the concordance of the morphometric results and general histomorphologic data and the correlation of some nuclear morphometric properties like mean nuclear area, mean nuclear roundness factor and mean nuclear form ellipse in gastrointestinal stromal tumors. On the other hand, Morales et al. (11) proposed an alternative scheme using morphological filters and components to eliminate the impulsive noise resulting from the image segmentation of blood vessels in the angiogenesis process of malignant tumors. It seems that in addition to computer-based techniques like image analysis, molecular targeted and genetic techniques in medicine will be more popular.

The procedure in the current SI method is labor-intensive and subjective, with the bottleneck step being the manual drawing of a line at any angle to estimate wall thickness. The more advanced computerization of this procedure is a tempting solution, and as we already realized, it is easy. This new technique based on image analysis seems more objective and reproducible than the classical, manual method. It is concluded that the use of this new technique dramatically reduced the subjectivity of the measurement process.

REFERENCES

1. Lee JH, Han EM, Lin ZH, et al. Clinicopathologic significance of nuclear grooves and inclusions in renal cell carcinoma image database construction and quantitative scoring. *Arch Pathol Lab Med* 2008;132:940-6
2. Helander HF, Poorkhalkali N. Parietal cell density during gastric ulcer healing in the rat. *Scand J Gastroenterol* 2004;39:20-6.
3. Özdamar SO, Bektas S, Özdamar SE, et al. Nuclear morphometric analysis in gastrointestinal stromal tumors: A preliminary study. *Turk J Gastroenterol* 2007;18:71-6.
4. Makay O, Yukselen V, Vardar E, et al. Role of allopurinol on oxidative stress in caustic burn: cure for stricture? *Pediatr Surg Int* 2007;23:1105-12.
5. Yukselen V, Vardar E, Yukselen O, et al. Infliximab in experimental alkali burns of the oesophagus in the rat. *Acta Gastroenterol Belg* 2008;71:21-6.
6. Yukselen V, Vardar E, Yukselen O, et al. Colchicine in experimental alkaline burns of the rat esophagus: an old drug, a new indication? *Pediatr Surg Int* 2006;22:363-68.
7. Apaydın BB, Paksoy M, Artis T, et al. Influence of pentoxifylline and interferon-alpha on prevention of stricture due to corrosive esophagitis. *Eur Surg Res* 2001;33:225-31.
8. Image processing and analysis in Java. Download page. Accessed in 2008 Sep 7. <http://rsbweb.nih.gov/ij/download.html>.
9. The Universities Federation For Animal Welfare (UFAW) Handbook on the care and management of laboratory animals 7th ed. (Ed.: T. Poole) Blackwell Science, Iowa, USA 1999.
10. National Institutes of Health (NIH) Publication No. 86-23, "Guide for the care and use of laboratory animals", United States Department of Health and Human Services, National Institutes of Health, Revised 1985.
11. Morales RR, Castellanos IB, Alarcon TE, et al. Elimination of noise via morphological filters and components labeling. Its use in the study of angiogenesis. Invited Symposium: New Technologies in Pathology and Medical Imaging in 6th Internet World Congress for Biomedical Sciences (Presentation 151) (<http://www.conganat.org/inabis2000/posters/listpost.htm> accessed in 13.09.2008).