

# Gallbladder ascariasis with uneventful worm migration back to the duodenum: A case report

Majid MUSHTAQUE, Parwez Sajad KHAN, Mohammad Farooq MIR, Samina Ali KHANDAY

Department of General Surgery, Sher-i-Kashmir Institute of Medical Sciences, Soura Srinagar Kashmir India, Srinagar, India

*Ascariasis, a worldwide parasitic disease, is regarded by some authorities as the most common parasitic infection in humans. The causative organism is Ascaris lumbricoides, which normally lives in the lumen of the small intestine. From the intestine, the worm can invade the bile duct or pancreatic duct, but invasion into the gallbladder is quite rare because of the anatomical features of the cystic duct, which is narrow and tortuous. Once it enters the gallbladder, it is exceedingly rare for the worm to migrate back to the intestine. We report a case of gallbladder ascariasis with worm migration back into the intestine, in view of its rare presentation.*

**Key words:** Gallbladder ascariasis, biliary ascariasis, worm migration

## Duodenuma sorunsuz geri dönen safra kesesi ascariasisi: Olgu sunumu

*Dünya çapında yaygın görülen Ascariasis, bazı otoriteler tarafından insanlarda görülen en sık parazit enfeksiyonu olarak tanımlanmaktadır. Etken organizma olan Ascaris lumbricoides, normalde ince barsakta yaşar. Kurt, barsaktan safra kanalı ve pankreatik kanalı invaze edebilir, ancak sistik kanalın dar ve kıvrımlı anatomik özellikleri nedeniyle safra kesesi invazyonu oldukça nadir görülmektedir. Bir kere safra kesesine girdikten sonra, kurdun tekrar barsağa migrasyonu ise son derece nadir görülmektedir. Burada nadir görülen, barsağa tekrar göç eden safra kesesi ascariasisi vakasını sunuyoruz.*

**Anahtar kelimeler:** Safra kesesi ascariasisi, biliyer ascariasis, kurt migrasyonu

## INTRODUCTION

Ascariasis, a worldwide parasitic disease, is regarded by some authorities as the most common parasitic infection in humans. The causative organism is *Ascaris lumbricoides*, which normally lives in the lumen of the small intestine (1). When the worm load is high, which may reach up to 1000 worms, the worms tend to migrate away from the usual site or habitat. From the intestine, the worm can invade the bile duct or pancreatic duct, but invasion into the gallbladder is quite rare because of the anatomical features of the cystic duct, which is narrow and tortuous. Once it enters the gallbladder, it is exceedingly rare for the worm to migrate back to the intestine (2). We report a case of gall-

bladder ascariasis with worm migration back into the intestine, in view of its rare presentation.

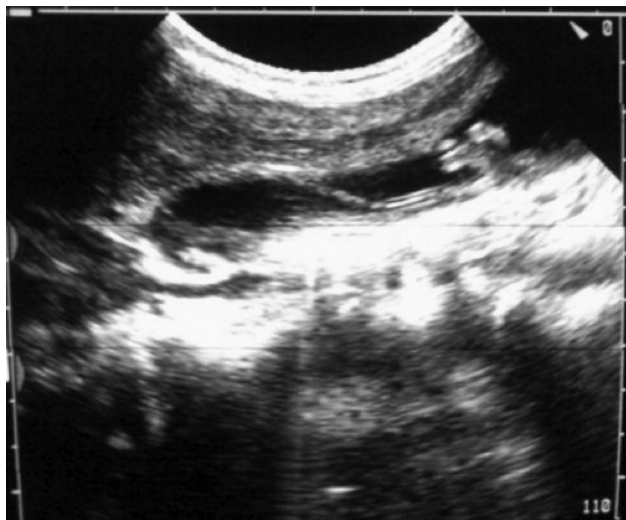
## CASE REPORT

A 40-year-old female who had been under regular follow-up after acute acalculous cholecystitis was scheduled for cholecystectomy after approximately six weeks of cholecystitis. The patient was admitted two days prior to the scheduled date of surgery. A new ultrasonography performed one day prior to surgery showed a linear echogenic image without acoustic shadow (Fig 1) in the lumen of the gallbladder, with erratic, non-directional, zig-

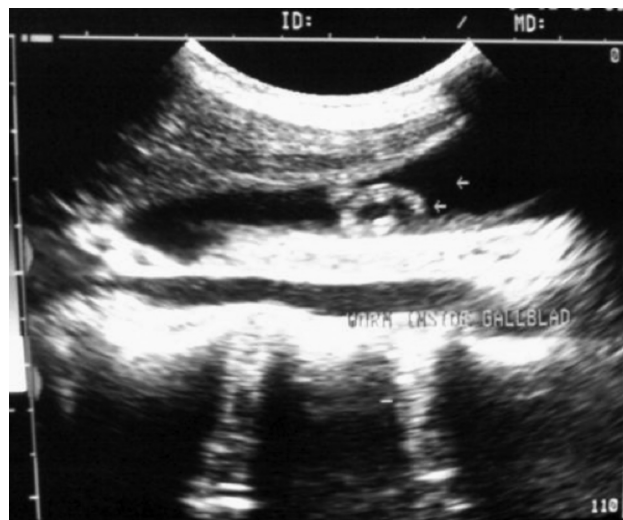
**Address for correspondence:** Parwez Sajad KHAN  
Sher-i-Kashmir Institute of Medical Sciences,  
Soura Srinagar Kashmir India, General Surgery, Srinagar, India  
E-mail: parwezsajad@yahoo.co.in

**Manuscript received:** 30.10.2010 **Accepted:** 08.12.2010

*Turk J Gastroenterol* 2012; 23 (2): 169-171  
doi: 10.4318/tjg.2012.0287



**Figure 1.** Ultrasonographic image showing a linear echogenic image without acoustic shadow characteristic of worm.



**Figure 2.** Showing curled echogenic image of worm on ultrasonography.

zag movements, characteristic of live ascaris with active movements (Fig 2). The patient was operated the next morning. There were many adhesions between the gallbladder and gut and omentum. Cholecystectomy was done, and the gallbladder was split open to search for the ascaris. The gallbladder was empty and the common bile duct was mildly dilated but free of stones or ascaris. Postoperative ultrasonography and magnetic resonance cholangiopancreatography (MRCP) were done to exclude its presence in the biliary tree, which was clear on ultrasonography. The worm had migrated back into the duodenum, which is extremely rare. The patient had an uneventful postoperative recovery and was discharged on the fourth postoperative day. She remains in good health six months after surgery.

## DISCUSSION

Biliary ascariasis is commonly reported from highly endemic regions like the Far East, Indian subcontinent, Latin America, parts of the Middle East, and Africa. *Ascaris lumbricoides* has a tendency to migrate through natural body orifices and enter Wirsung's duct and the common bile duct through the papilla of Vater. Previous surgery on the biliary tract like sphincterotomy and Roux-en-Y hepaticojejunostomy predisposes to bi-

liary ascariasis. In endemic regions, recurrent worm invasion of the ducts has been observed frequently. Khuroo *et al.* (3) reported a similar observation in their study. Biliary ascariasis is more common in females. Symptoms of biliary colic occur when the worm migrates across the papilla. If the worm remains in the bile duct and gallbladder, acute and chronic complications can occur, like cholangitis, strictures, calculi, cholecystitis, and pancreatitis (4,5).

Ultrasound is diagnostic in biliary ascariasis and is quite sensitive in the diagnosis and can also be used for follow-up. The worms present as a linear echogenic image without acoustic shadow in the lumen of the gallbladder and common bile duct (6,7). The findings of erratic, non-directional, zig-zag movements are characteristic of a live worm (8).

Most cases of gallbladder ascariasis require surgical intervention (9), though there have been a few isolated reports of their management by anthelmintics only (10).

The uneventful migration of the parasite from the gallbladder back into the duodenum is exceedingly rare because of the anatomical features of the cystic duct, which is narrow and tortuous (2). However, in the present case, the worm migrated back to the intestine uneventfully.

## REFERENCES

1. Mahmoud Adel AF. Intestinal nematodes (round worms). In: Mandell GL, Douglas RG, Bennett JEB, eds. Principles and practice of infectious diseases. 3<sup>rd</sup> ed. New York: Churchill Livingstone, 1990; 2135-42.
2. Khuroo MS, Zargar SA, Yattoo GN, et al. Sonographic findings in gallbladder ascariasis. *J Clin Ultrasound* 1992; 20: 587-91.
3. Khuroo MS, Zargar SA, Mahajan R. Hepatobiliary and pancreatic ascariasis in India. *Lancet* 1990; 335: 1503-6.
4. Saul C, Pias VM, Jannke HA, Braga NH. Endoscopic removal of *Ascaris lumbricoides* from the common bile duct. *Am J Gastroenterol* 1984; 79: 725-7.
5. Javid G, Wani N, Gulazar GM, et al. Gallbladder ascariasis: presentation and management. *Br J Surg* 1999; 86: 1526-7.
6. Gomez NA, Leon CJ, Ortiz O. Ultrasound in the diagnosis of roundworms in gallbladder and common bile duct. *Surg Endosc* 1993; 7: 339-42.
7. Aslam M, Dore SP, Verbanck JJ, et al. Ultrasonographic diagnosis of hepatobiliary ascariasis. *J Ultrasound Med* 1993; 12: 573-6.
8. Filice C, Marchi L, Maloni C, et al. Ultrasound in the diagnosis of gallbladder ascariasis. *Abdom Imaging* 1995; 20: 320-2.
9. Puneet SK, Tiwary S, Singh S, et al. Gallbladder ascariasis: a case report. *The Internet Journal of Parasitic Diseases* 2006; 1(1).
10. Cha DY, Song IK, Choi HW, et al. Successful elimination of *Ascaris lumbricoides* from the gallbladder by conservative medical therapy. *J Gastroenterol* 2002; 37: 758-60.