

Iloprost reduces colitis induced oxidative stress: An experimental study in rats

Erman AYTAÇ¹, Serkan TEKSÖZ¹, Seha SAYGILI², Osman Baran TORTUM¹, Nihat YAVUZ¹,
Volkan SÖZER³, Süha GÖKSEL⁴, Hafize UZUN⁵, Hakkı Oktay SEYMEN², Ertuğrul GÖKSOY¹

Departments of ¹General Surgery, ²Physiology, ⁴Pathology and ⁵Biochemistry, İstanbul University Cerrahpaşa Medical Faculty, İstanbul,
Department of Chemistry, ³Division of Biochemistry, Yıldız Technical University, İstanbul

Background/aims: Reactive oxygen species have a known potent role in the pathogenesis of ulcerative colitis. Iloprost, a pharmaceutical, is a chemically stable derivative of a naturally- occurring human prostacyclin. Several studies have demonstrated protective effects of iloprost via its antioxidant and its anti-inflammatory activity. The aim of this study is to evaluate the effects of iloprost on oxidant/antioxidant status, as well as the large bowel histopathology in experimental colitis. **Materials and Method:** Forty adult male Wistar-albino rats were randomly divided in to four equal weight-matched groups: sham group (n=10), iloprost administered sham group (n=10), colitis group (n=10), iloprost administered colitis group (n=10). Acetic acid (1 ml of 4% solution) was used to induce colonic inflammation in the rats. **Results:** Colonic tissue and plasma malondialdehyde levels were significantly lower in the iloprost administered colitis group than the colitis group (p<0.01). Tissue glutathione levels of the iloprost administered colitis group were significantly higher than the colitis group (p<0.001). **Conclusion:** We have demonstrated in this study iloprost to be an antioxidant, as well as iloprost demonstrating protective activity against colitis induced oxidative stress.

Key words: Iloprost, prostacyclin, colitis, experimental, oxidative stress

Iloprost kolit nedeniyle oluşan oksidatif hasarı azaltır: Deneysel çalışma

Giriş ve Amaç: Reaktif oksijen ürünleri, ülseratif kolit patogeneğinde önemli rol oynarlar. İloprost, doğal oluşan prostasiklinin kimyasal olarak stabil türevidir. İloprostun antioksidan ve antiinflamatuvar etkileri ile koruyucu etkileri olduğunu gösteren çalışmalar mevcuttur. Bu çalışmanın amacı iloprostun oksidan/antioksidan denge ve kalın bağırsak histopatolojisi üzerine etkilerini deneysel kolit modelinde değerlendirmektir. **Gereç ve Yöntem:** Kırk adet erkek Wistar-albino cinsi suçan rastlantısal olarak dört eşit ağırlıklı gruba dağıtıldı: sham grubu (n=10), iloprost uygulanan sham grubu (n=10), kolit grubu (n=10), iloprost uygulanan kolit grubu (n=10). Asetik asid (1 ml of %4' lük solüsyonun 1 mililitresi ile) ile kolon enflamasyonu oluşturuldu. **Bulgular:** İloprost uygulanan kolit grubu kolon dokusu ve plazma malondialdehit değerleri kolit grubundan anlamlı derecede düşüktü (p<0.01). İloprost uygulanan kolit grubu doku glutatyon değeri kolit grubundan anlamlı derecede yüksekti (p<0.001). **Sonuç:** Kolit nedeniyle oluşan oksidatif hasara karşı iloprostun antioksidan ve koruyucu etkisini gösterdik.

Anahtar kelimeler: Iloprost, prostasiklin, kolit, deneysel, oksidatif stres

INTRODUCTION

Reactive oxygen species (ROS) including superoxide and hydroxyl free radicals, together with hydrogen peroxide, show direct toxicity to organs. ROS can initiate free-radical-mediated chain reactions which can cause additional cellular damage

(1). Malondialdehyde (MDA) is one of the end products of lipid peroxidation. Tissue concentrations of MDA are assayed as an index of membrane oxidative damage (2). Antioxidant defense mechanisms lessen the harmful effects of ROS in normal

Address for correspondence: Erman AYTAÇ
İstanbul University Cerrahpaşa Medical Faculty, Department of
General Surgery, İstanbul, Turkey
E-mail: eaytacr@yahoo.com

Manuscript received: 31.10.2011 **Accepted:** 13.02.2012

Turk J Gastroenterol 2013; 24 (3): 224-229
doi: 10.4318/tjg.2013.0491

physiological conditions. Glutathione (GSH) and superoxide dismutase (SOD) are the major known defenders of cells from oxidative damage. The oxidized form of GSH is a dimer—GSSG, and it is involved in the transport of certain amino acid. GSSH is a coenzyme for various enzymes and protects against oxygen radicals as well as other toxic compounds. SOD catalyzes the dismutation of superoxide to hydrogen peroxide. This causes the conversion of two O_2^- molecules into H_2O_2 and O_2 . SOD exists in mitochondrial (Mn-SOD) and cytoplasmic forms (Cu/Zn-SOD) (3). Increased oxidation activity is known to take place within the pathophysiology of the ulcerative colitis (UC). It is also known that ROS are involved in the development of experimental colitis (4). Local and systemic inflammation depletes the antioxidant response in UC (5).

Iloprost is a chemically stable derivative of a naturally-occurring prostacyclin. Prostacyclin, which is derived from endothelium, is a known vasodilator, and it has antithrombotic effects, inhibits activation of neutrophil leukocytes, and activates fibrinolysis (6). Several studies have demonstrated protective effects of iloprost via its antioxidant and anti-inflammatory activity (7, 8).

In literature, the data regarding iloprost against colitis is limited. The aim of this study is to evaluate the effects of iloprost on a basis of oxidant/antioxidant status, as well as the large bowel histopathology in experimental colitis.

MATERIALS and METHODS

This study was performed after approval from the Ethics Committee of the Animal Care Review Board of Istanbul University, Cerrahpasa Medical Faculty. Forty adult male Wistar-albino rats weighing between 200 grams and 250 grams were obtained from the Experimental Animal Production and Research Laboratory of Istanbul University Cerrahpasa Medical Faculty. These rats were randomly divided into four equal weight-matched groups: sham (S) group (n=10), after sham operation iloprost administered (IS) group (n=10), colitis (C) group (n=10), after colitis induction iloprost administered (IC) group (n=10). The rats were kept in standard colony cages (15 cm by 25 cm by 40 cm) under controlled conditions including temperature (18 °C), light (12 hours of light and then 12 hours of darkness), and controlled humidity (50-55%). The rats were fed with standard rat chow and tap water ad libitum during the experimental proce-

dures except during the 24 - hour – period prior to the colitis induction.

Induction of colitis

Six centimeters of a soft six French catheter was inserted in to the anal canal of the rat, under ketamine chloride [40 mg/kg, intraperitoneal (IP)] anesthesia. Acetic acid (AA) (1 ml of 4% solution) was used for the induction of colonic inflammation. After AA injection, two ml of air was insufflated into the colon to spread the AA completely prior to the removal of the catheter. This procedure was performed for the C and the IC groups. The S and the IS groups received the same volume of isotonic saline, under the same conditions as described for the C groups.

Iloprost administration

The IS and the IC groups received IP 2 µg/kg/day iloprost (Ilomedin®: Bayer Schering Pharma; Bayer Turk Kimya San. Ltd. Sti, Umraniye, Istanbul) immediately after colitis induction, for five consecutive days. The same volume of isotonic saline was given intraperitoneally to the S and the C groups at the same time intervals. The rats were subsequently killed by cervical dislocation five days after colitis induction, and the blood and tissue samples were then collected and processed.

Biochemical procedures

Preparation of the tissue samples

The colonic samples were diluted to 20% w/v in 20 mM ice-cold Tris-HCl, at a pH of 7.4, and homogenized with a Bosch Scintilla SA (Switzerland). The homogenate was then centrifuged at 5000 xg for 10 min, and various analytical determinations were performed in the supernatant fraction.

Assay of malondialdehyde

Lipid peroxidation levels in plasma and colonic tissue were measured with the thiobarbituric acid (TBA) reaction (9). This method was used to obtain a spectrophotometric measurement of the color produced during the reaction of TBA with malondialdehyde (MDA) at 535 nm. The coefficients of intra-assay and inter-assay variations for the MDA assay were 3.6% and 5.3%, respectively.

Assay of glutathione

The glutathione (GSH) concentrations within the colonic tissue were estimated according to the Ellman method (10). One milliliter of tissue homogenate was de-proteinized, and then subsequently centrifuged at 600 xg for 20 min. After addition of

dithiobis-nitrobenzoate and a phosphate buffer (pH 8.0) into the clear supernatants of the samples, the color this reaction produced was read at 412 nm. The GSH concentrations of the samples were calculated using $1.36 \times 10^4 \text{ M}^{-1} \text{ cm}^{-1}$ as the molar absorption coefficient. The intra-assay and inter-assay coefficients of variation for GSH were 3.5% and 3.7%, respectively.

Assay of Cu-Zn superoxide dismutase activity

The plasma and the colonic tissue Cu-Zn superoxide dismutase (SOD) activity were determined utilizing the method of Sun *et al.* (11). The assay involves inhibition of nitroblue tetrazolium (NBT) (Sigma Chemical Co., St Louis, MO, USA) and reduction with xanthine-xanthine oxidase (Sigma Chemical Co.), which is used as a superoxide generator. One unit of SOD is defined as the amount of protein that inhibits the rate of NBT reduction by 50%. The coefficients of intra-assay and inter-assay variations were 1.8 % and 3.2%, respectively.

Histopathology evaluation

Macroscopic evaluation

The large bowel of the rats were taken out in toto (from ileocecal junction to the anus), and cleaned with normal saline. Colon weight (g), colon length (cm), stool, and macroscopic inflammation were the parameters of the macroscopic evaluation. The parameters were scored from normal findings of 0 (least severe pathologic change) to 4 (the most severe pathological change) in terms of their ratio change, according to the normal values. Separate index scores for these macroscopic parameters were determined for each rat.

Microscopic evaluation

Four randomly selected tissue sections from the distal colon were taken from the first to fourth centimeter of the anus in each rat, and were rinsed in saline, fixed in 10% neutral buffered formalin, embedded in paraffin, sectioned, and finally stained with hematoxylin and eosin (H&E). The tissues were examined and were then scored, between 0 to 3 for epithelial damage, cellular infiltration, and damage or alteration of smooth muscle architecture.

Epithelial damage was assessed in terms of blunted mucosa, destruction of crypt architecture, and/or loss of epithelium. Muscle damage was assessed in terms of sub mucosal edema, hyperplasia, and/or loss of architecture. Normal appearance was defined as 0 and severe damage (greater than 66% of tissue length) was numbered as 3. Separate index scores for microscopic parameters were determined for each rat. All of the above procedures were performed in every rat for the experimental groups. The metric scoring system for macroscopic and microscopic histopathology has been defined by Kimball *et al.* (12) previously.

Statistical analysis

All data are expressed as means, standard deviations (means \pm SD), and 95% confidence intervals. One-way ANOVA and post hoc Tukey's test was used for statistical analysis, and $p < 0.05$ was considered to be significant for all biochemical parameters.

RESULTS

The results of the oxidative stress parameters are summarized in Table 1. We did not observe any harmful effects of iloprost on oxidative stress parameters, macroscopic, or on microscopy of the colonic tissue. The colonic tissue ($p < 0.01$) and plasma ($p < 0.001$) MDA levels of the C group was determined to be significantly higher than the S group. The colonic tissue and plasma Cu-Zn SOD levels, as well as the colonic tissue GSH levels of the C group were significantly lower than the S group

Table 1. The results of the biochemical parameters.

Groups	Tissue MDA	Tissue SOD	Tissue GSH	Plasma MDA	Plasma SOD
S	1,21 \pm 0,32	66,89 \pm 7,96	5,50 \pm 1,07	2,73 \pm 0,78	22,56 \pm 2,79
IS*	0,96 \pm 0,26	68,20 \pm 6,53	5,34 \pm 1,10	2,43 \pm 0,57	24,70 \pm 2,67
C	1,85 \pm 0,52 •	53,90 \pm 9,56 †	4,02 \pm 0,54 †	4,41 \pm 0,52 †	16,90 \pm 2,38 †
IC	1,23 \pm 0,33‡	58,90 \pm 6,51	5,93 \pm 0,46 §	3,46 \pm 0,48‡	19,70 \pm 2,71

S: Sham group; IS; iloprost administered sham group; C: Colitis group; IC: iloprost administered colitis group; MDA: malondialdehyde; SOD: superoxide dismutase; GSH: glutathione.

(*) There was no difference between the biochemical parameters of the S and the IS groups. (•) Significantly different than S group ($p < 0.01$).

(†) Significantly different than S group ($p < 0.001$). (‡) Significantly different than C group ($p < 0.01$). (§) Significantly different than C group ($p < 0.001$).

($p < 0.001$). The colonic tissue as well as plasma MDA levels were significantly lower in the IC group than the C group ($p < 0.01$). Tissue GSH levels of the IC group were noted to be significantly higher than the C group ($p < 0.001$).

Active inflammation was observed in the C group in macroscopic and microscopic analysis (Figure 1B) compared to the S group (Figure 1A).

There was no significant difference between the groups for the colon weights ($p > 0.05$). However, the colon length of the IC group was significantly shorter than the S and IS groups ($p < 0.001$). In the macroscopic evaluation, the stool scores of the IC group were significantly lower than the C group ($p < 0.01$) (Table 2). In the microscopic evaluation, the muscular damage score in the IC (Figure 1C) group was significantly lower than the C group ($p < 0.05$) (Table 3).

DISCUSSION

In this study, we have demonstrated antioxidant as well as protective activity of iloprost against oxidative stress induced by experimental colitis. Recurrent diarrhea and severe destruction of the colonic mucosa is seen almost always in the clinical presentation of UC. Unfortunately at the current time, resection of the colon and rectum is the only curative treatment option for patients. However, most cases with limited colonic extent coupled with determination of mild to moderate inflammatory activity are managed by medical treatment, generally with successful outcomes under endoscopic surveillance (13).

This reality forces physicians to find alternative medical treatment strategies for UC, and treatment which generally will continue for life (13, 14). There are various theories that attempt to

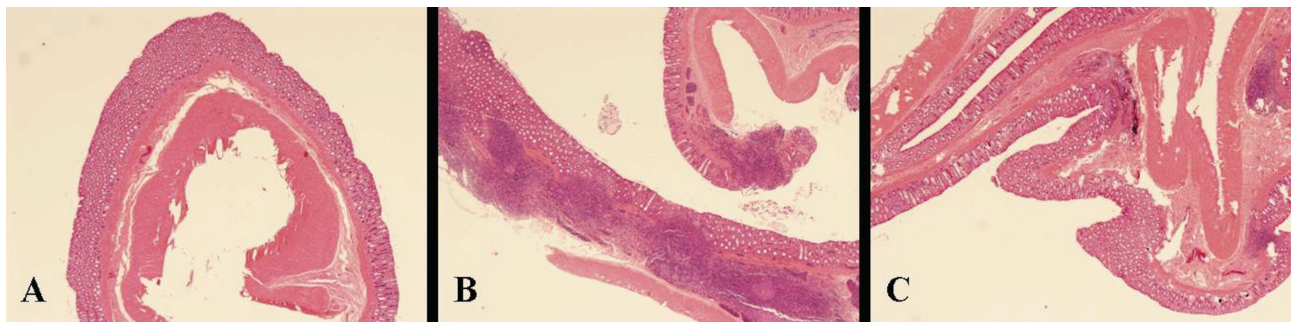


Figure 1. (A) Normal colon tissue; (B) Active colitis; (C) Regressed colonic inflammation with iloprost administration. (Hematoxylin and eosin stain, magnification X 40).

Table 2. Macroscopic scores of the experimental groups.

Groups	Colon length	Colon weight	Stools	Inflammation
S	0	0	0	0
IS*	0,33±0,52	0,5±0,55	0,5±0,55	1,17±0,41
C	0,83±0,75	1±0,63	2,33±0,32 †	2,17±0,75 †
IC	2,17±0,75 †	1±0,63	1,33±0,32 §	1,67±0,82

S: Sham group; IS; iloprost administered sham group; C: Colitis group; IC: iloprost administered colitis group.

(*) There was no difference between the biochemical parameters of the S and the IS groups. (†) Significantly different than S group: $p < 0.001$.

(‡) Significantly different than C group ($p < 0.05$). (§) Significantly different than C group ($p < 0.01$).

Table 3. Microscopic scores of the experimental groups.

Groups	Epithelial damage	Cellular infiltration	Muscle damage
S*	0	0	0
IS	0,33±0,52	0,5±0,55	0
C	3,17±0,75 †	2,83±0,75 †	2,33±0,52 †
IC	2,83±0,75	2,5±0,84	1,67±0,52 ‡

S: Sham group; IS; iloprost administered sham group; C: Colitis group; IC: iloprost administered colitis group.

(*) There was no difference between the biochemical parameters of the S and the IS groups. (†) Significantly different than S group: $p < 0.001$.

(‡) Significantly different than C group ($p < 0.05$).

explain the pathophysiology of UC. One of these theories is the radical induction theory, in which uncontrolled oxidant production within the colonic epithelial cells via a pathologic cellular pathway is blamed for damaging the epithelial barrier in the theory. This initial occurrence could diminish the immune mechanisms in luminal surfaces of the large bowel, and ultimately could cause an inflammatory disease on colonic epithelium (14).

ROS have a potent role in the pathogenesis of UC. Neutrophils and macrophages produce large amounts of ROS by infiltrating the bowel wall in colitis (15). Impaired antioxidant defense in the red blood cells of UC patients have been reported (16). A tragic experience showed us the relationship between oxidants and UC in which H₂O₂ enemas had been used for the treatment of fecal impaction at the beginning of 20th century. With this form of enema, severe rectitis and colitis was reported following H₂O₂ enema application (13,14,16,17). H₂O₂ is also produced after aerobic and anaerobic metabolism of the cell, and its overproduction plays a key factor of many pathological pathways (3). It has been shown previously that UC causes DNA damage by increasing oxidative stress (17, 18). Colorectal cancer in UC patients occurs when there are diseased colonic epithelial cells with damaged DNA (19).

Prostacyclin regulates cAMP levels in the cell, and this controls vascular function, inhibits platelet aggregation, down-regulates neutrophil adhesion, and scavenges free radicals (20). Epithelial and stromal cells produce prostaglandins, which are important factors for cell to cell interactions in colonic tissue (21). Prostacyclin is one of the most important defenders of the gastrointestinal mucosal surfaces, as well as for the vascular structures (22). The molecular mechanism of prostacyclin activity is currently under investigation. As a stable prostacyclin analogue, the primary effect of iloprost is vasodilation. Antioxidant and anti-inflammatory properties of iloprost have been reported by presenting different molecular mechanisms on different types of tissue (6-8). The efficacy of iloprost against active colitis has not been evaluated up until now however. In our study, iloprost application augmented GSH production, which was diminished after the induction of colitis in the colonic wall. GSH is one of the body's scavengers of

H₂O₂ (22,23). Iloprost may show its antioxidant properties by initiating GSH production in colonic cells. Additionally, iloprost administration seemingly initiated a conspicuous decrease on the lipid peroxidation of the colonic tissue, as well as for the plasma. Stool formation improved in iloprost treated rats, however no significant macroscopic change were observed on the colon tissue. In the microscopic analysis, the muscular layer of the iloprost treated group appeared more natural as well as healthier than the colitis group. The beneficial effects of the same dose and application route of iloprost that we applied in the study had also been reported in previous studies investigating colon ischemia and anastomotic healing in Wistar albino rats (24,25).

While our study was being performed, Karatepe *et al.* (24) reported that iloprost ameliorates ischemic colitis in rats. This study presented an original idea and beneficial results were well documented in the study, however the difference of the method from the ischemia model of colon was not well defined (23, 24). Ischemic colitis is difficult to evaluate experimentally, as ischemia is only one part of the complex pathogenesis of ischemic colitis (25, 26). The parameter for which they evaluated utilizing microscopy could have been changed in part to the actual ischemia, rather than as a result of colitis. This fact makes this study difficult to differentiate from a classical ischemia type presentation, versus a colitis presentation. The AA induced colitis model resembles UC in humans in terms of the histopathological appearance, due in part because of the over production of oxidant radicals (26,27). Most UC patients have rectal involvement, and UC also tends to occur on the rectal mucosa initially, and subsequently progresses retrograde to the other parts of the colon. These features of the UC are simulated with the AA induced colitis experimentally by chemical irritation of the mucosa of the large intestine from the rectum, which then extends in a retrograde fashion.

Iloprost has antioxidant effects in experimental colitis and could potentially protect colon tissue against inflammation, however further studies containing inflammatory parameters are needed to better understand the effects of iloprost against colonic inflammation.

REFERENCES

1. Ghoneim AI, Abdel-Naim AB, Khalifa AE, El-Denshary ES. Protective effects of curcumin against ischemia/reperfusion insult in rat forebrain, *Pharmacol Res* 2002; 46: 273-9.
2. Koudelova J, Mourek J. The lipid peroxidation in various parts of the rat brain: effect of age, hypoxia and hyperoxia. *Physiol Res* 1994; 43: 169-73.
3. Nita DA, Nita V, Spulber S, et al. Oxidative damage following cerebral ischemia depends on reperfusion-a biochemical study in rat. *J Cell Mol Med* 2001; 5: 163-70.
4. Grisham MB, Volkmer C, Tso P, Yamada T. Metabolism of trinitrobenzene sulfonic acid by the rat colon produces reactive oxygen species, *Gastroenterology* 1991; 101: 540-7.
5. Riccardi L, Mazzon E, Bruscoli S, et al. Peroxisome proliferator-activated receptor-alpha modulates the anti-inflammatory effect of glucocorticoids in a model of inflammatory bowel disease in mice. *Shock* 2009; 31: 308-16.
6. Grant SM, Goa KL. Iloprost: a review of its pharmacodynamic and pharmacokinetic properties and therapeutic potential in peripheral vascular disease, myocardial ischemia and extracorporeal circulation procedures. *Drugs* 1992; 43: 889-924.
7. Aytac E, Seymen HO, Uzun H, et al. Effects of iloprost on visual evoked potentials and brain tissue oxidative stress after bilateral common carotid artery occlusion. *Prostaglandins Leukot Essent Fatty Acids* 2006; 74: 373-8.
8. Kiris I, Tekin I, Yilmaz N, et al. Iloprost down regulates expression of adhesion molecules and reduces renal injury induced by abdominal aortic ischemia-reperfusion. *Ann Vasc Surg* 2009; 23: 212-23.
9. Yagi K. Assay for blood plasma or serum. *Methods Enzymol* 1984; 105: 328-31.
10. Ellman GL. Tissue sulfhydryl groups. *Arch Biochem Biophys* 1959; 82: 70-7.
11. Sun Y, Oberly LW, Ying LA. Simple method for clinical assay of superoxide dismutase. *Clin Chem* 1988; 34: 497-500.
12. Kimball ES, Palmer JM, D'Andrea MR, et al. Acute colitis induction by oil of mustard results in later development of an IBS-like accelerated upper GI transit in mice. *Am J Physiol Gastrointest Liver Physiol* 2005; 288: 1266-73.
13. Katz JA. Management of inflammatory bowel disease in adults. *J Dig Dis* 2007; 8: 65-71.
14. Pravda J. Radical induction theory of ulcerative colitis. *World J Gastroenterol* 2005; 28: 2371-84.
15. Risques RA, Rabinovitch PS, Brentnall TA. Cancer surveillance in inflammatory bowel disease: new molecular approaches. *Curr Opin Gastroenterol* 2006; 22: 382-90.
16. Krzystek-Korpaczka M, Neubauer K, Berdowska I, et al. Impaired erythrocyte antioxidant defense in active inflammatory bowel disease: impact of anemia and treatment. *Inflamm Bowel Dis* 2010; 16: 1467-75.
17. Pumphery RE. Hydrogen peroxide proctitis, *Am J Surg* 1951; 81: 60-2.
18. Aslan M, Nazligul Y, Bölükbaş C, et al. Peripheral lymphocyte DNA damage and oxidative stress in patients with ulcerative colitis. *Pol Arch Med Wewn* 2011; 16: 223-9.
19. Hussain SP, Amstad, Raja K, et al. Increased p53 mutation load in noncancerous colon tissue from ulcerative colitis: A cancer prone chronic inflammatory disease. *Cancer Res* 2000; 60: 3333-7.
20. Fink AN, Frishman WH, Azizad M, Agarwal Y. Use of prostacyclin and its analogues in the treatment of cardiovascular disease. *Heart Dis* 1999; 1: 29-40.
21. Lawson LD, Powel DW. Bradykinin-stimulated eicosanoid synthesis and secretion by rabbit ileal components. *Am J Physiol* 1987; 252: 783-90.
22. Lee SH, Soyoola E, Chanmungam P, Hart S, et al. Selective expression of mitogen-inducible cyclooxygenase in macrophages stimulated with lipopolysaccharide. *J Biol Chem* 1992; 267: 25934-8.
23. Rebrin I, Kamzalov S, Sohal RS. Effects of age and caloric restriction on glutathione redox state in mice. *Free Radicals Biol Med* 2003; 35: 626-35.
24. Karatepe O, Cakir A, Unal O, et al. Iloprost reduces colonic injury in ischemic colitis in rats. *Acta Cir Bras* 2011; 26: 220-6.
25. Vasiliadis K, Pramateftakis MG, Blouhos K, et al. Effect of iloprost on impaired anastomotic healing caused by 5-fluorouracil plus leucovorin. *Dis Colon Rectum* 2007; 50: 899-907.
26. Carlson RM, Madoff RD. Is "ischemic" colitis ischemic? *Dis Colon Rectum* 2011; 54: 370-3.
27. Bitiren M, Karakilcik AZ, Zerim M, et al. Protective effects of selenium and vitamin E combination on experimental colitis in blood plasma and colon of rats. *Biol Trace Elem Res* 2009; 136: 87-95.