

Primary hepatic tuberculosis masquerading as cholangiocarcinoma: A clinical nugget

Irfan Ali Shera , Muzafar Rashid Shawl , Prem Rajan, Ram Chandra Soni

Department of Gastroenterology, Asian Institute of Medical Science, Haryana, India

Cite this article as: Shera IA, Shawl MR, Rajan P, Soni RC. Primary hepatic tuberculosis masquerading as cholangiocarcinoma: A clinical nugget. *Turk J Gastroenterol* 2019; 30(8): 764-6.

Dear Editor,

Tuberculosis (TB) is one of the oldest known infective bacterial diseases to mankind, with a history that dates back to the ancient Egyptian times where scientists found evidence of TB in mummies. It can have varied presentations from weight loss, malaise, and low grade fever to fulminant meningitis leading to death. Hepatic TB is an extremely rare form of extrapulmonary TB and can be seen as miliary TB, tubercular abscess, or portal hepatitis. Medical management is key treatment of hepatic TB with excellent prognosis, rarely warrant surgery in certain situations like complicated abscess and refractory disease. Here we present a case of isolated hepatic TB presented as a malignant appearing perihilar mass with obstructive jaundice.

A 37-year-old woman was referred to gastroenterology clinic of our hospital with chief complaints of pain in the upper abdomen for 1 month associated with significant weight loss and progressive yellowish discoloration of eyes and skin and dark urine. She was worked up at a primary hospital and was diagnosed as a case of obstructive jaundice with suspected distal cholangiocarcinoma on ultrasound, which showed large perihilar mass with dilated upstream biliary radicles. On further evaluation, her CA 19-9 was 45 IU (reference value: 35 IU) and carcinoembryonic antigen was negative. Contrast enhanced computed tomography (CECT) of the abdomen showed large perihilar mass lesion with high grade biliary obstruction and intrahepatic biliary radicle dilatation (Figure 1). There was no obvious evidence of metastasis on CECT. Endoscopic ultrasound (EUS)-guided fine needle aspiration was performed for the tissue diagnosis of suspected perihilar mass. On endoscopic ultrasound, it appears heteroechoic necrotic perihilar mass as shown in Figure 2. EUS-guided aspirated specimens showed acid fast

bacilli and well-formed granulomas, as depicted in Figure 3. Endoscopic retrograde cholangiopancreatography (ERCP)-assisted CBD drainage and plastic biliary stent placement were performed. She received anti-tubercular therapy for 6 months. She is currently on follow up and doing well.

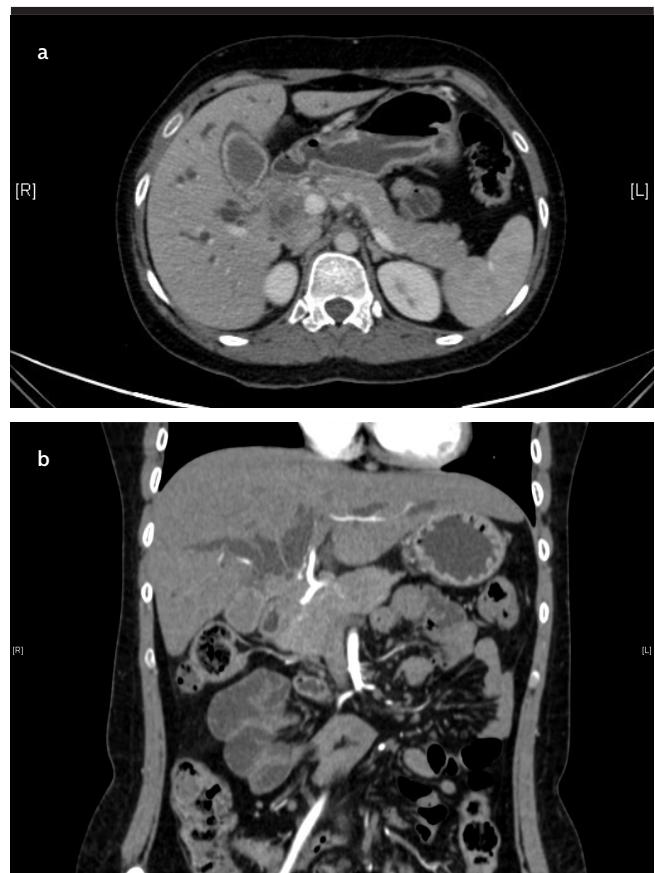


Figure 1. a, b. CT showing perihilar mass lesion with bilobar dilation of intrahepatic biliary radicals

Corresponding Author: Irfan Ali Shera; sherairfan@gmail.com

Received: July 8, 2018 Accepted: September 24, 2018 Available online date: November 28, 2018

© Copyright 2019 by The Turkish Society of Gastroenterology · Available online at www.turkjgastroenterol.org

DOI: 10.5152/tjg.2018.18558

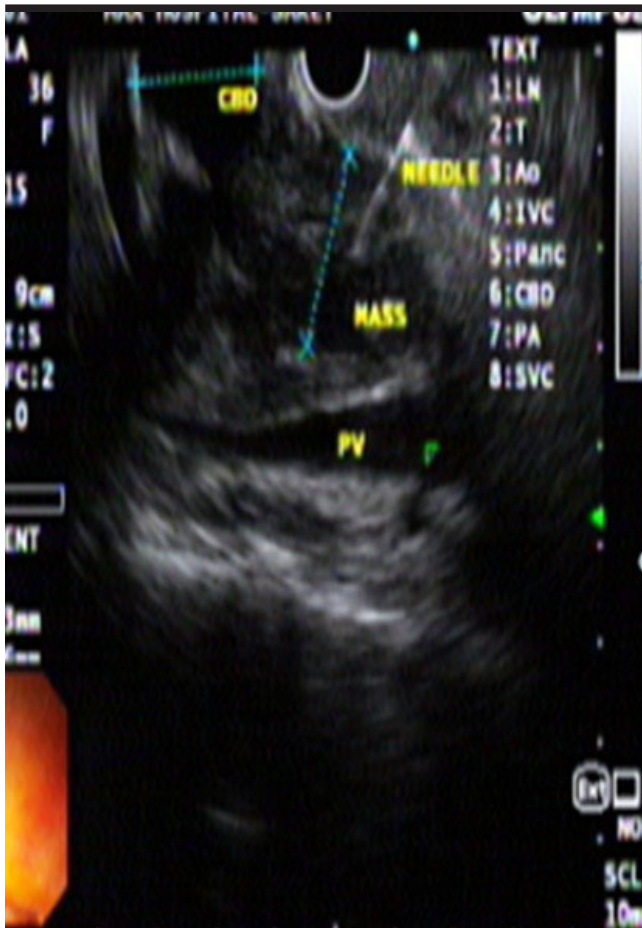

Figure 2. Shows fine needle aspiration of heteroechoic mass lesion of common bile duct on linear array endoscopic ultrasound

Abdominal TB is generally classified as gastrointestinal TB, peritoneal TB, TB of the mesentery, and TB of solid organ viscera and abdominal lymph nodes. It is prevalent in developing nations as a complication of pulmonary TB, as a part of disseminated infection, and often as an isolated presentation. Primary involvement of the liver in TB is rare because of the low tissue oxygen level, which makes the liver unfriendly for the propagation of the bacilli (1). Hepatic TB is observed in predominantly three forms, namely, (1) miliary hepatic TB, seen as a part of systemic tubercular infection where small tubercular lesions can be seen diffusely distributed across the liver and where patient remains almost asymptomatic from the hepatic perspective, (2) primary TB of the liver without the involvement of other organs present as granulomatous hepatitis, and (3) tubercular abscess and nodular TB.

Primary pyogenic lesions in the liver is a rare clinical entity, and most of these lesions are <2 cm and >3 cm, are

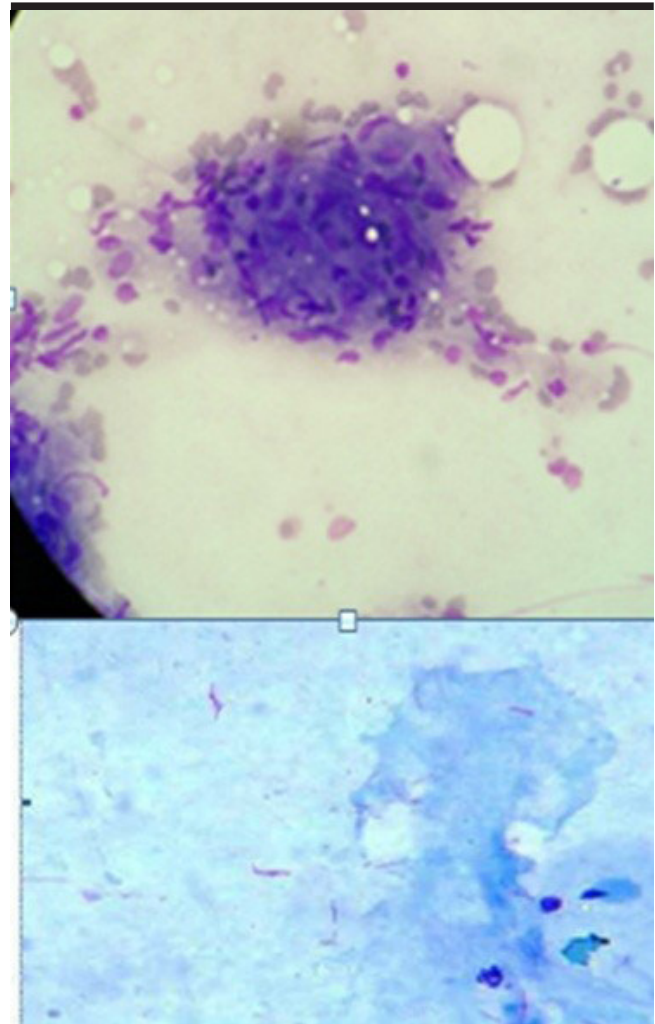


Figure 3. Showing necrotizing granuloma and acid-fast bacilli

named as macronodular tuberculomas, and described as pseudotumors by DeBary et al (2). The diagnosis of hepatic TB include (a) the demonstration of acid fast bacilli in the liver tissue, (b) hepatic granuloma with or without caseation and tuberculi bacilli present elsewhere, (c) characteristic visual appearance on laparotomy or peritoneoscopy, and (d) response to anti-tubercular medications (3).

Imaging has little role in the diagnosis of hepatic TB. Due to its varied presentations, on CECT, it appears as a hypodense mass with heterogeneous consistency with or without rim enhancement and central necrotic areas (4). On ultrasound lesions, it is generally visualized as hypoechoic nodules (5). Moreover, yield of acid fast bacilli and culture positivity may reach 40%-60%, and necro-

tizing granuloma is not fairly seen. PCR for Mycobacterium tuberculosis had a positivity rate of approximately 60% (6). Classically, tubercular granulomas are necrotizing caseous granulomas with lymphoplasmacytic infiltration and lymphoid hyperplasia, but these granulomas are poorly formed and inflammatory response is less marked in immunocompromised individuals (7). In view of histological evidence of necrotizing granulomas, acid fast positivity and response to anti-tubercular therapy are corroborative evidence supporting the diagnosis of TB once differentiating from perihilar lesions of the liver. The prognosis of perihilar TB varies with the time of diagnosis: if diagnosed early and effective treatment is administered, the prognosis is good. These patients often present with obstructive jaundice, early diagnosis is warranted to differentiate from cholangiocarcinoma. The diagnosis is made by image-guided tissue acquisition. The treatment ranges from effective biliary drainage, administration of anti-tubercular therapy and in rare situations, may need surgical assistance.

Peer-review: Externally peer-reviewed.

Author Contributions: Concept - I.A.S., M.R.S., P.R., R.C.S.; Design - I.A.S., M.R.S., P.R., R.C.S.; Supervision - I.A.S., M.R.S., P.R., R.C.S.; Data Collection and/or Processing - I.A.S., M.R.S., P.R., R.C.S.; Analysis and/or Interpretation - I.A.S., M.R.S., P.R., R.C.S.;

Literature Search - I.A.S., M.R.S., P.R., R.C.S.; Writing Manuscript - I.A.S., M.R.S., P.R., R.C.S.; Critical Reviews - I.A.S., M.R.S., P.R., R.C.S.

Conflict of Interest: The authors have no conflict of interest to declare.

Financial Disclosure: The authors declared that this study has received no financial support.

REFERENCES

1. Kanagaraj A, Marthandam LR, Sriramakrishnan V, Rajesh A, Meenakumari P. Tuberculous liver abscess. *J Assoc Phys India* 2008; 56: 647-8.
2. Zipser RD, Ran JE, Ricketts RR, et al. Tuberculous pseudotumors of the liver. *Am J Med* 1976; 61: 946-51. [\[CrossRef\]](#)
3. Maharaj B, Leary WP, Pudifin DJ. A prospective study of hepatic tuberculosis in 41 black patients. *Q J Med* 1987; 63: 517-22.
4. Buxi TB, Vohra RB, Sujatha Y, et al. CT appearances in macronodular hepatosplenic tuberculosis: a review with five additional new cases. *Comput Med Imaging Graph* 1992; 16: 381-7. [\[CrossRef\]](#)
5. Tan TCF, Cheung AYC, Wan WYL, et al. Tuberculoma of the liver presenting as a hyperechoic mass on ultrasound. *Br J Radiol* 1997; 70: 1293-5. [\[CrossRef\]](#)
6. Diaz ML, Herrera T, Vidal YL, et al. Polymerase chain reaction for the detection of Mycobacterium tuberculosis DNA in tissue and assessment of its utility in the diagnosis of hepatic granulomas. *J Lab Clin Med* 1996; 127: 359-63. [\[CrossRef\]](#)
7. Lebovics E, Thung SN, Schaffner F. The liver in the acquired immunodeficiency syndrome: A clinical and histologic study. *Hepatology* 1985; 5: 293-8. [\[CrossRef\]](#)