

Endoscopic resection using argon plasma coagulation for treating esophageal mucosal bridge in a patient with acquired immunodeficiency syndrome

Tae Hee Lee¹ , Tae Hyong Kim² 

¹Institute for Digestive Research, Digestive Disease Center, Soonchunhyang University Seoul Hospital, Seoul, Republic of Korea

²Division of Infectious disease, Department of Internal Medicine, Soonchunhyang University Seoul Hospital, Seoul, Republic of Korea

Cite this article as: Lee TH, Kim TH. Endoscopic resection using argon plasma coagulation for treating esophageal mucosal bridge in a patient with acquired immunodeficiency syndrome. *Turk J Gastroenterol* 2019; 30(8): 758-60.

Dear Editor,

An esophageal mucosal bridge is a very rare endoscopic finding. The condition is also termed a double-lumen esophagus (1). The epidemiology, etiology, pathogenesis, and optimal management of such a mucosal bridge remain poorly known. This condition has been reported to be due to reflux esophagitis (1), esophageal candidiasis (2), radiotherapy (3), Crohn's disease (4), variceal sclerotherapy (5), and fundoplication (6). Its clinical presentation likely depends on both the mechanical effect of the bridge itself and the underlying disease. Few studies have reported the management of this condition. Here we describe a very rare case of successful endoscopic treatment of an esophageal mucosal bridge in a patient with acquired immunodeficiency syndrome (AIDS).

A 73-year-old male was referred to our Department of Gastroenterology for dysphagia and difficulty with oral feeding. We considered percutaneous endoscopic gastrostomy. The patient had been hemiplegic since developing an intracerebral hemorrhage in the left basal ganglia 1 year prior and had been under HIV/AIDS treatment with viral-suppressive antiretroviral therapy for 10 years. He suffered from frequent episodes of aspiration pneumonia during nasogastric tube-feeding prior to the evaluation of his dysphagia. His previous medical history included hypertension, chronic kidney disease, aortic dissection, a pressure sore on the coccyx, and gastric ulcers. The patient was conscious, and his vital signs were stable. Targeted physical examination of the dysphagia revealed reduced bilateral jaw strength, palatal and tongue weakness, and poor oral hygiene. Laboratory findings revealed anemia and renal insufficiency; the hemoglobin and creatinine levels were 9.3 g/dL and 1.27 mg/dL, respectively.

The CD4 T cell count was 356/ μ L and the HIV RNA PCR level was <20 copies/mL.

The patient had earlier undergone an upper endoscopic examination in our hospital because of poorly controlled residual gastric volume associated with nasogastric feeding intolerance. At that time, the esophageal mucosa was unremarkable except for multiple gastric erosions (Figure 1a). Subsequently, after medical treatment with prokinetics and a proton pump inhibitor, his feeding intolerance improved. Six months later, esophagogastroduodenoscopy was performed as a gastrostomy procedure. Thirty centimeters from the incisor teeth, the esophageal lumen had doubled (Figure 1b). Diverticula were found just below this mucosal bridge (Figure 1c). We performed endoscopic resection using argon plasma coagulation (APC) to avoid the risk of bleeding and perforation that would have been in play during further percutaneous endoscopic gastrostomy using the pull-through technique. APC at 60 W and a gas flow rate of 2 L/min readily transected the mucosal bridge (Figure 2a). A follow-up endoscopy revealed kissing artificial ulcers without any complication such as bleeding or perforation (Figure 2b). Subsequently, the patient underwent successful percutaneous endoscopic gastrostomy 2 days later. The patient provided written informed consent for the publication of his data.

An esophageal mucosal bridge is a rare entity and its formation in our patient may have been associated with the long-standing placement of a nasogastric tube or the esophageal ulcers. Two earlier case reports indicated that esophageal mucosal bridge formation was associated with esophageal trauma caused by a nasogastric tube (7,8). The esophagus is one of the most common sites of gastrointestinal involvement in patients with AIDS (9). Esophageal

Corresponding Author: Tae Hee Lee; iman0825@schmc.ac.kr

Received: July 7, 2018 Accepted: September 24, 2018 Available online date: November 20, 2018

© Copyright 2019 by The Turkish Society of Gastroenterology · Available online at www.turkjgastroenterol.org

DOI: 10.5152/tjg.2018.18463

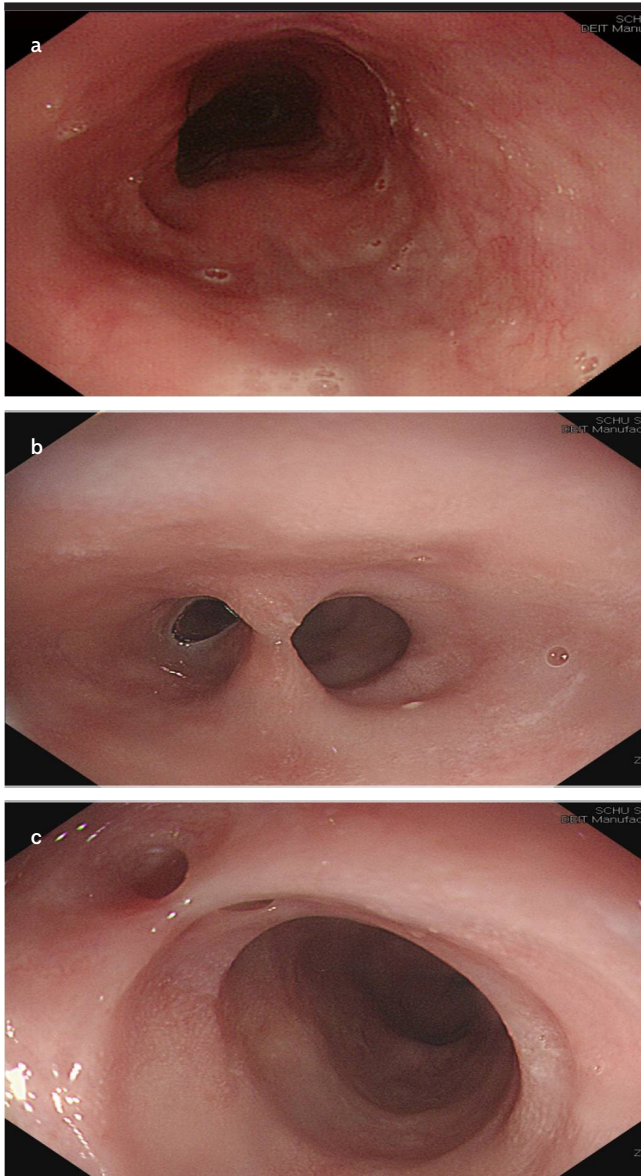


Figure 1. a-c. Endoscopic views: Prior endoscopy showed that the esophageal mucosa was unremarkable (a); a mucosal bridge was evident in the esophagus 30 cm from the incisors (b); two small outpunched sacs were apparent just below the mucosal bridge (c)

ulcers are commonly caused by infections, such as cytomegalovirus, or may be idiopathic in patients with AIDS.

Very few bridge treatments have been reported till date. Endoscopic treatment modalities include bougienage (1), endoscopic coagulation with Eder-Puestow dilatations (3), and APC (10). In a case series on esophageal bridges successfully treated via APC, the power used was 90 W and the gas flow used was 1.6 L/min. Sagawa et al. (11)

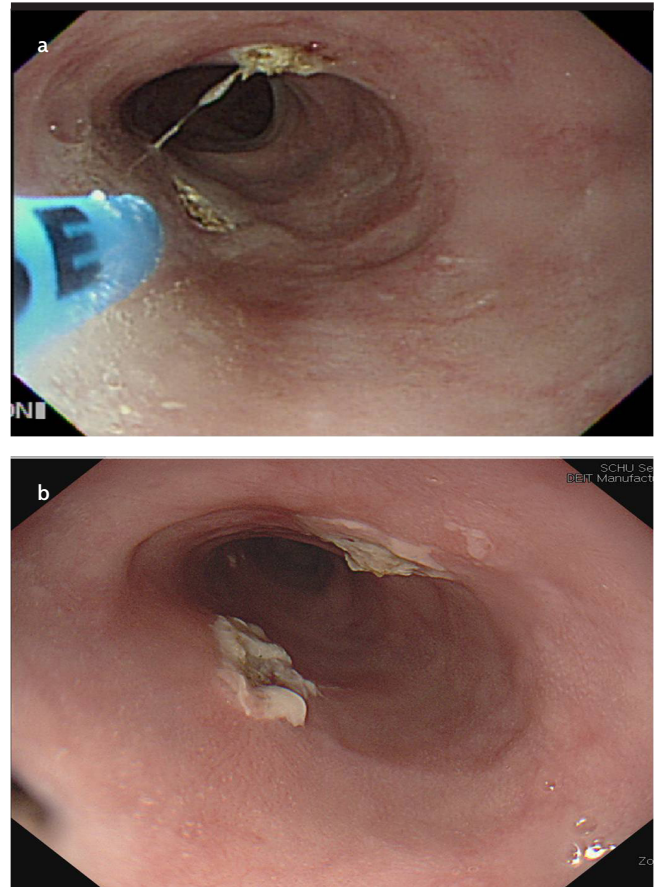


Figure 2. a-b. Endoscopic views: The mucosal bridge was readily transected via argon plasma coagulation at 60 W and a gas flow of 2 L/min (a); follow-up endoscopy performed the next day revealed kissing artificial ulcers without any complication such as perforation or bleeding (b)

reported the coagulation depths (in swine gastric wall) of APC at various irradiation strengths; the depth depended on the power and duration of irradiation. The optimum APC treatment featured a power of 60 W and a maximum irradiation time of 15 s, which would not be expected to cause perforation. Thus, we chose an APC power of 60 W. In conclusion, an esophageal mucosal bridge may be caused by trauma associated with nasogastric tube use in patients with AIDS and can be safely treated using APC.

Informed Consent: Informed consent was obtained from the patient who participated in this study.

Peer-review: Externally peer-reviewed.

Author Contributions: Concept - T.H.L.; Design - T.H.L.; Supervision - T.H.K.; Data Collection and/or Processing - T.H.L.; Writing - T.H.L.; Critical Reviews - T.H.K.

Conflict of Interest: The authors have no conflict of interest to declare.

Financial Disclosure: This study was financially supported by the Soonchunhyang University Research Fund.

REFERENCES

1. Mihas AA, Slaughter RL, Goldman LN, Hirschowitz BI. Double lumen esophagus due to reflux esophagitis with fibrous septom formation. *Gastroenterology* 1976; 71: 136-7.
2. Rattan J, Hallak A, Rozen P, Werbin N, Gilat T. Esophageal moniloma and mucosal bridge. *Gastrointest Endosc* 1982; 28: 114-5. [\[CrossRef\]](#)
3. Papazian A, Capron JP, Ducroix JP, Dupas JL, Quenum C, Besson P. Mucosal bridges of the upper esophagus after radiotherapy for Hodgkin's disease. *Gastroenterology* 1983; 84: 1028-31.
4. Honda S, Sugimoto K, Iwasaki H, et al. Multiple mucosal bridge formation in the esophagus in a patient with Crohn's disease. *Endoscopy* 1998; 30: S37-8. [\[CrossRef\]](#)
5. Sood A, Midha V, Sood N, Kaushal V. Multiple mucosal bridges in the oesophagus after sclerotherapy for varices. *Trop Gastroenterol* 2001; 22: 94-5.
6. Hussain SZ, Abbas AE, Brown MF, et al. Surgical reconstruction of the double lumen esophagus. *J Pediatr Surg* 2013; 48: 661-4. [\[CrossRef\]](#)
7. Buchman AL, Waring JP. Mucosal bridge formation in the esophagus caused by injury from a nasogastric feeding tube. *JPEN J Parenter Enteral Nutr* 1994; 18: 278-9. [\[CrossRef\]](#)
8. Tashiro M, Matsuda K, Ueda R. Double lumen esophagus: a rare complication of nasogastric tube? *Dig Endosc* 2014; 26: 680. [\[CrossRef\]](#)
9. Monkemuller KE, Wilcox CM. Diagnosis of esophageal ulcers in acquired immunodeficiency syndrome. *Semin Gastrointest Dis* 1999; 10: 85-92.
10. Mukherjee M, Oh J, Khair A, Grosman I. Esophageal mucosal bridges associated with idiopathic esophageal ulcer treated with argon plasma coagulation. *Gastrointest Endosc* 2008; 68: 387-9. [\[CrossRef\]](#)
11. Sagawa T, Takayama T, Oku T, et al. Argon plasma coagulation for successful treatment of early gastric cancer with intramucosal invasion. *Gut* 2003; 52: 334-9. [\[CrossRef\]](#)