

Double pigtail stents healed acute pancreatitis resulting from afferent loop obstruction

Ping Yue^{1,2} , Wenbo Meng^{1,2} , Zhiwen Luo³ , Bing Bai^{1,2} , Xun Li^{2,4} 

¹Department of Special Minimally Invasive Surgery, The Frist Hospital of Lanzhou University, Lanzhou, China

²Hepatopancreatobiliary Surgery Institute of Gansu Province, Clinical Medical College Cancer Center of Lanzhou University, Lanzhou, China

³The First Clinical Medical College of Lanzhou University, Lanzhou, China

⁴The Fifth General Surgery Department, The First Hospital of Lanzhou University, Lanzhou, China

Cite this article as: Yue P, Meng W, Luo Z, Bai B, Li X. Double pigtail stents healed acute pancreatitis resulting from afferent loop obstruction. *Turk J Gastroenterol* 2018; 29: 705-7.

Dear Editor,

It is a generally accepted notion that afferent loop obstruction (ALO) is a short-term, infrequently occurring mechanical complication after Billroth II gastrojejunostomy and Roux-en-Y reconstruction. However, till date, no report has shown that the ALO could also be a long-term complication resulting from recurrent tumors in the anastomotic stoma. Besides, reports demonstrating ALO serving as an independent pathogenic factor for acute pancreatitis are even rarer. In the present study, we described a case of acute pancreatitis caused by ALO, which is recurrent-tumor-induced, and the successful management of the case using non-surgical approaches.

A 63-year-old man who underwent a radical gastric antral carcinoma resection and Billroth II gastrojejunostomy four years prior presented to our hospital with three-day epigastric pain and vomiting comprising transparent gastric juice without bile. The routine complete blood count was normal, but serum biochemistry tests showed abnormalities including alanine aminotransferase (ALT) 55U/L (1-49U/L), aspartate aminotransferase (AST) 63U/L (1-49U/L), alkaline phosphatase (ALP) 101U/L (20-125U/L), γ -glutamyltransferase (GGT) 216U/L (3-69U/L), serum amylase 1195U/L (27-154U/L), and urine amylase 15135U/L (50-700U/L), indicating the malfunction of liver and pancreas. An abdominal computed tomography (CT) scanning revealed the following: 1) afferent loop (intestinal canal) was dilated and emerged as effusion (Figure 1a, b), 2) a thickened anastomosis wall was formed suggesting a cancer recurrence and abdominal lymph node metastases, 3) a mild edema of the pancreas

and the gallbladder was enlarged (Figure 1c). Considering these characteristic manifestations revealed by imaging and vomiting, the patient was diagnosed with acute pancreatitis. Combined with the test results of the increased biliary system pressure, bile and pancreatic juice discharging, ALO-induced pancreatitis was considered as the pathogenesis in this case.

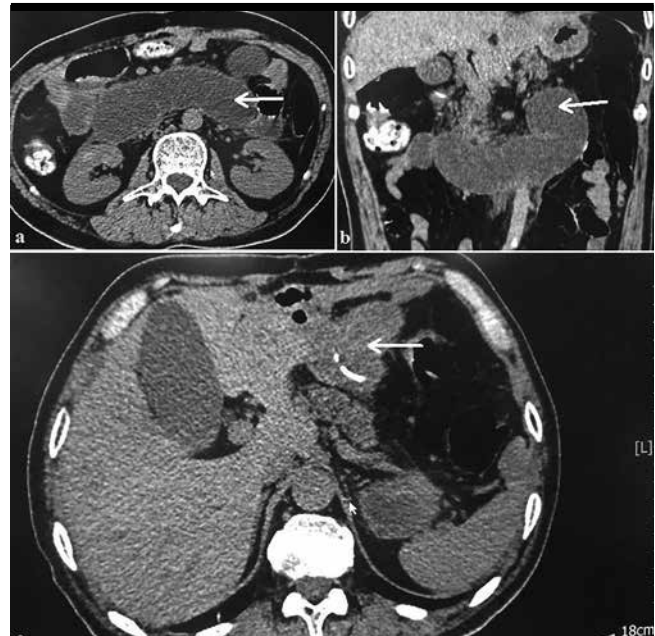


Figure 1. a-c. Images of computed tomography (CT) findings before the procedure: Afferent loop (intestinal canal) was dilated and emerged as effusion (axial view) (a); C-shaped intestinal loop (white arrow) (b); Thickened anastomosis wall (white arrow), mild edema of pancreas and gallbladder enlargement (c)

ORCID IDs of the authors: P.Y. 0000-0001-8736-949X; W.M. 0000-0002-9355-0225; Z.L. 0000-0003-1400-1437; B.B. 0000-0001-8257-4515; X.L. 0000-0003-3787-1558.

Corresponding Author: Xun Li; drlixun@163.com

Received: February 25, 2018 Accepted: April 16, 2018 Available online date: August 9, 2018

© Copyright 2018 by The Turkish Society of Gastroenterology · Available online at www.turkjgastroenterol.org

DOI: 10.5152/tjg.2018.17685

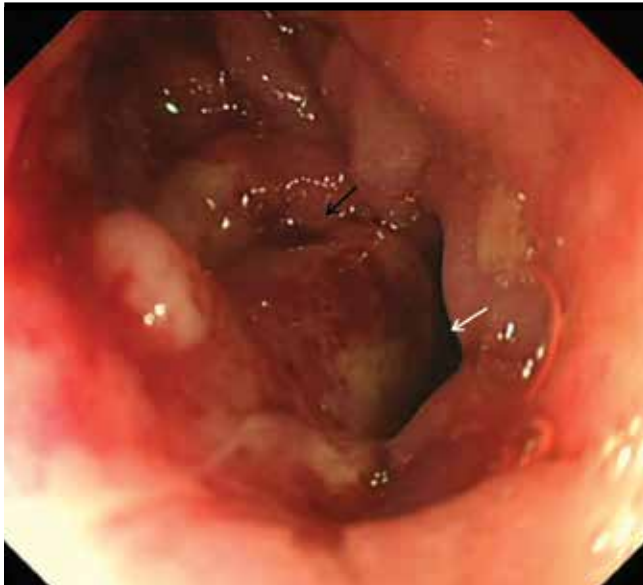

Figure 2. Images under gastroscopy. A cambium was located at the opening of gastrointestinal anastomosis for an afferent loop (black arrow), and efferent loop remained unobstructed (white arrow)

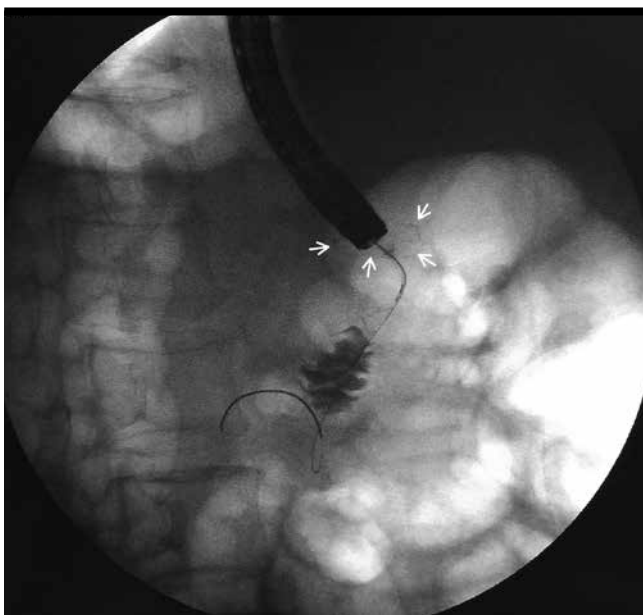


Figure 3. Dilatation of afferent loop revealed under X-ray after contrast agent injection. White arrow: ring-shaped anastomotic nail can be observed

Gastroscopy was attempted for further diagnosis and afferent decompression. After the insertion of the scope, a cambium was observed to have formed an obstruction at the opening of gastrointestinal anastomosis. However, the efferent loop was still unobstructed (Figure 2). Hence, af-

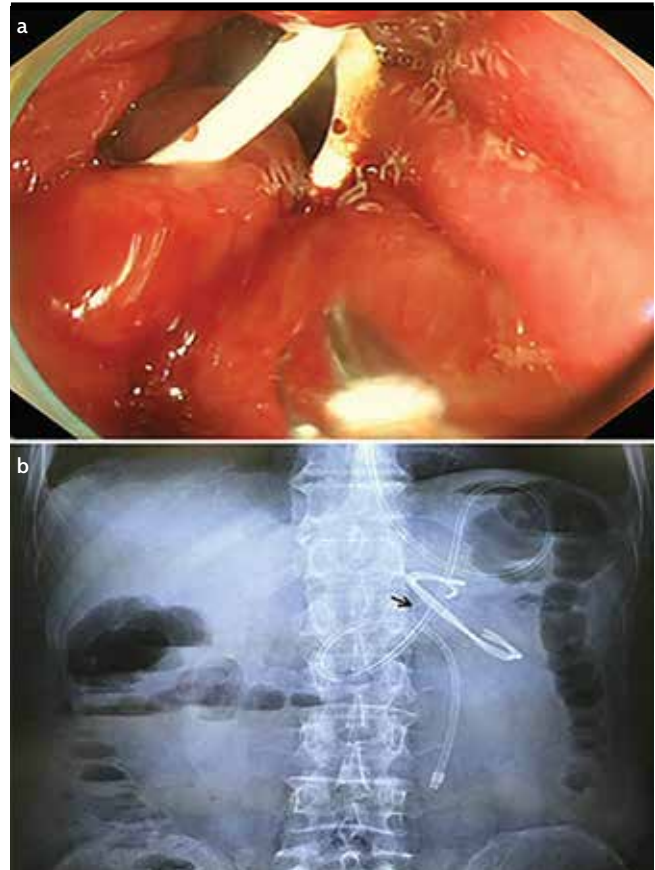


Figure 4. a, b. Implanted two pigtail stents: Two 7Fr-4cm double pigtail plastic stents (a); Annular anastomotic nail (black arrow, the two double pigtail stents across the gastrointestinal anastomosis and nasal feeding tube can be observed in the efferent loop under abdominal X-ray (b)

ferent decompression by tumor recurrence was considered. The cannulation was successfully performed using sphincterotome (Clever Cut 3V, Olympus, Tokyo, Japan). Next, it was followed by placing the guidewire (0.035in, Jagwire, Boston Scientific, Galway, Ireland) into the stoma site; the guidewire passed through the narrow entry into the afferent loop. The intestinal canal of the afferent loop was noticeably dilated under X-ray after the contrast agent was injected (Figure 3). Next, the first guidewire was retained at its place, and a second guidewire of similar type and size was placed though the same route. Next, we maintained double guidewires in the afferent loop, and attempted to placed two 7Fr-4cm double pigtail plastic stents (Single Use Biliary Stent V, Olympus, Tokyo, Japan) to the gastrointestinal anastomosis of afferent loop (Figure 4a). A large amount of fluid flooded into gastric stump after stents were placed. An indwelling nasal feeding tube was placed into efferent loop afterward (Figure 4b). Subsequently, the

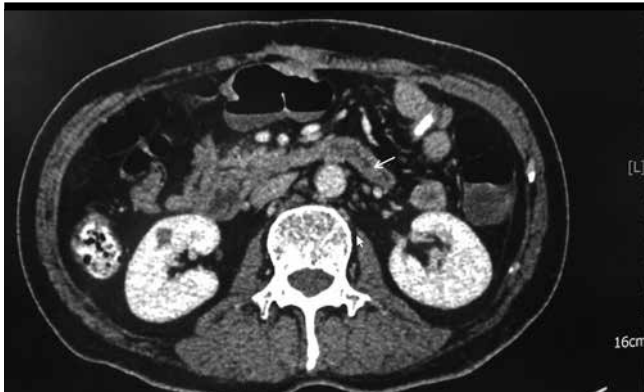

Figure 5. Picture of fluid discharged after the decompression of afferent loop (white arrow)

patient had a rapid and positive response to the operation and the symptoms were quickly released after operation. The pain primarily caused by high pressure of the afferent loop also dramatically decreased afterward. The blood and urine amylase dropped to normal range, the second CT scanning performed 24 hours after the operation demonstrated that the afferent loop effusion disappeared (Figure 5). The oral feeding was restored and the nasojejunal feeding tube was removed. The patient was discharged at day 7 postoperatively with greatly alleviated symptoms. However, the fourth-month follow-up showed that this patient had died of multiple organ failure associated with the previous gastric cancer. Written informed consent for the operation and for the publication of this article was obtained from the patient before the procedures were performed.

The ALO after distal gastric cancer resection with Billroth II gastrojejunostomy or Roux-en-Y procedure has been rarely reported, with its incidence ranging from 0.3% to 1.0% (1). Its reported risk factors include ankyloenteron, internal hernia, intestinal twist, intussusception, cancer recurrence, and radiation enteritis (2). The typical imaging feature of CT for ALO is that the enteric tube of the afferent loop is noticeably dilated and filled with liquid, presenting a U- or C-shaped intestinal loop and may sometimes simultaneously show gallbladder enlargement and common bile duct dilatation (3). Meantime, since bile cannot be discharged into the stomach because of the complete obstruction of the afferent loop, the most definitive clinical manifestation of ALO is vomit without bile. More recent evidence demonstrated that surgery plan is still being considered as the prioritized treatment plan. Both transhepatic and transgastric approaches to relieve the obstruction have been used so far (primary anastomotic resection and reconstruction, anastomosis of input loop and output

loop, percutaneous puncture stoma, and direct percutaneous or endoscopic enteral metal stent insertion) (4). To our knowledge, it has rarely been reported that ALO caused by the recurrence of cancer could elevate the risk of acute pancreatitis (5). In this case, we considered the palliative treatment as the preferred therapeutic plan because the patient was in the late stage of malignant tumor, suffering from cachexia, and had a BMI of only 15.20 kg/m². To our knowledge, this is the first attempt to place two double pigtail stents in anastomosis to achieve a management of ALO and which finally led to healing of the pancreatitis. This therapeutic plan is oriented for patients who desire a palliative choice for extending the survival time. For those patients with gastric cancer who have tumors that are noted or highly suspected with lymph node metastasis, an inoperative supplemental Braun anastomose between the afferent and efferent loops have a potential to decrease complications including perioperative-period or long-term ALO in the course of radical resection of gastric cancer (6).

Peer-review: Externally peer-reviewed.

Author Contributions: Concept - P.Y., W.M., Z.L., B.B.; Design - P.Y., W.M., B.B., X.L.; Supervision - P.Y., W.M., X.L.; Resources - P.Y., W.M., X.L.; Materials - P.Y., Z.L., B.B.; Data Collection and/or Interpretation - Z.L., B.B.; Analysis and/or Interpretation - P.Y., W.M., X.L.; Literature Search - P.Y., Z.L., B.B.; Writing Manuscript - P.Y., W.M., Z.L., X.L.; Critical Review - P.Y., Z.L., B.B.

Acknowledgements: The authors would like to thank Dr Long Miao and Yanyan Lin from our medical center for giving us assistance during the therapeutic process.

Conflict of Interest: The authors have no conflict of interest to declare.

Financial Disclosure: This study was financially supported by the Gansu Province Science Foundation for Youths (Grant No. 17JR5RA259).

REFERENCES

1. Grisé K, McFadden D. Anastomotic technique influences outcomes after partial gastrectomy for adenocarcinoma. *Am Surg* 2001; 67: 948-50.
2. Blouhos K, Boulas KA, Tsalis K, et al. Management of afferent loop obstruction: Reoperation or endoscopic and percutaneous interventions? *World J Gastrointest Surg* 2015; 7: 190-5. [[CrossRef](#)]
3. Zissin R. CT findings of afferent loop syndrome after a subtotal gastrectomy with Roux-en-Y reconstruction. *Emerg Radiol* 2004; 10: 201-3. [[CrossRef](#)]
4. Shimatani M, Takaoka M, Tokuhara M, et al. Through-the-scope self-expanding metal stent placement using newly developed short double balloon endoscope for the effective management of malignant afferent-loop obstruction. *Endoscopy* 2016; 48: E6-7. [[CrossRef](#)]
5. Vettoretto N, Pettinato G, Romessis M, et al. Laparoscopy in afferent loop obstruction presenting as acute pancreatitis. *JLS* 2006; 10: 270-4.
6. Cui LH, Son SY, Shin HJ, et al. Billroth II with Braun Enteroenterostomy Is a Good Alternative Reconstruction to Roux-en-Y Gastrojejunostomy in Laparoscopic Distal Gastrectomy. *Gastroenterol Res Pract* 2017; 2017: 1803851. [[CrossRef](#)]