

Incidentally detected PET-avid liver adenomatosis: MRI and 18F-FDG PET-CT findings

Ayşegül Öz¹ , Bedriye Koyuncu Sökmen¹ , Nagihan İnan¹ , Numan Cem Balcı¹ , Yaman Tokat² 

¹Department of Radiology, İstanbul Bilim University School of Medicine, İstanbul, Turkey

²Department of General Surgery, İstanbul Bilim University School of Medicine, İstanbul, Turkey

Cite this article as: Öz A, Koyuncu Sökmen B, İnan N, Balcı NC, Tokat Y. Incidentally detected PET-avid liver adenomatosis: MRI and 18F-FDG PET-CT findings. *Turk J Gastroenterol* 2018; 29: 623-4.

Dear Editor,

Liver adenomatosis is a benign and rare tumor. It is defined as multiple hepatic adenomas (>4-10 lesions) in the normal liver parenchyma (1,2). Magnetic resonance imaging (MRI) is the primary method for the diagnosis of adenomas and is used in characterizing the subtypes. When incidental multiple liver lesions are detected and evaluated using positron emission tomography-computed tomography (PET-CT), the differential diagnosis of adenomas with malignancies and hypervascular metastasis is very difficult because adenomas can show 18-F-fluoro-2-deoxy-D-glucose (¹⁸F-FDG) uptake. Here we report the clinical and imaging findings of a PET-avid liver adenomatosis case.

A 35-year-old lactating woman was admitted to the general surgery department with abdominal pain. Blood tests showed no alterations. On abdominal ultrasound, multiple hyperechoic lesions were detected. Contrast-enhanced liver MRI was performed to characterize the lesions. Precontrast in-phase and out-of-phase sequences, T2-weighted images (WI), and pre- and post-contrast fat-suppressed (FS) T1-WI were evaluated. All lesions were isointense on in-phase images, hyperintense on T2-WI, and showed marked signal dropout on FS and out-of-phase sequences (Figure 1. a-e.). MRI confirmed multiple (10 lesions) fat-containing, slowly enhancing lesions, which were suggestive of liver adenomatosis. All lesions showed intense ¹⁸F-FDG uptake (Figure 2). The biggest lesion was 8 cm, with the standardized uptake value (SUV_{max}) of 7.6. Ultrasonography guided tru-cut biopsy revealed liver adenomas. Informed consent was obtained from all patients for MRI, PET-CT scans, and biopsy.

Liver adenomatosis is a very rare entity, and PET-avid liver adenomatosis is a very uncommon manifestation. Previous studies have found no correlation between liver adenomatosis and glycogen storage disease, steroid intake, or oral contraceptive use because it occurs in normal liver parenchyma (1,2). It affects both women and men, but some studies have reported female dominance and oral contraceptive use (3,4). Our patient had no history of oral contraceptive use.

To our knowledge, this is the third case of PET-avid adenomatosis. All reported cases are HNF1- α mutated subtype and/or steatotic. There is no defined PET-positive inflammatory or telangiectatic subtype of liver adenomas

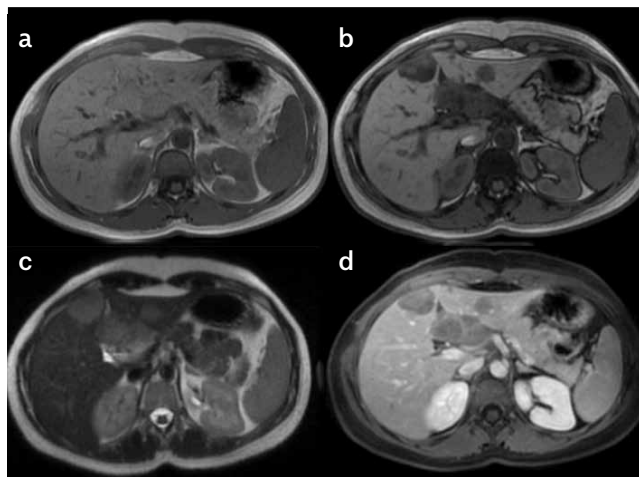


Figure 1. a-d. Axial contrast-enhanced liver MRI images Multiple isointense lesions on in-phase image (a); showing marked signal loss on out-of-phase image (b); Lesions are hyperintense on T2-WI (c); hypointense on postcontrast venous phase FS T1-W (d) images, and slowly enhancing after intravenous contrast administration

ORCID IDs of the authors: A.Ö. 0000-0002-5797-5066; B.K.S. 0000-0002-1470-803X; N.İ. 0000-0003-1048-6449; N.C.B. 0000-0002-4537-3850; Y.T. 0000-0002-9899-1521.

Corresponding Author: Ayşegül Öz; aoz.ayseguloz@gmail.com

Received: December 25, 2017 Accepted: March 8, 2018 Available online date: August 2, 2018

© Copyright 2018 by The Turkish Society of Gastroenterology · Available online at www.turkjgastroenterol.org

DOI: 10.5152/tjg.2018.17783

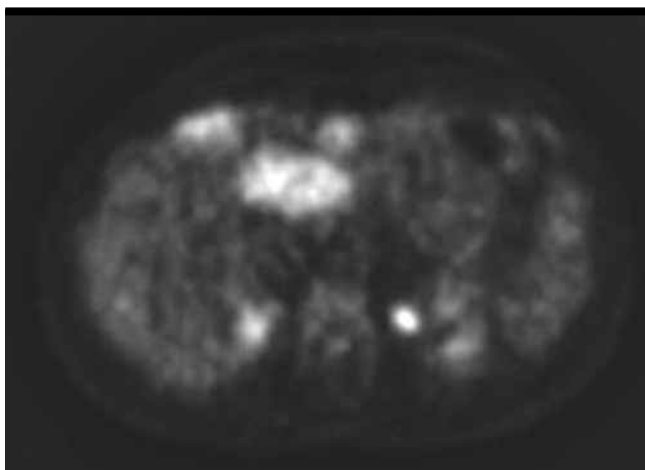


Figure 2. Axial PET-CT image. All lesions show intense ^{18}F -FDG uptake

(5). In our patient, all adenomas showed signal loss on the out-of-phase sequence and all were steatotic.

It is well known that focal fatty infiltrations and fat necrosis can be PET positive. The fatty infiltration of activated Kupffer cells leads to subacute inflammation, causing a higher SUV_{max} than the normal parenchyma (6,7). Thus, PET-CT can predict the HNF1- α subtype, which is the type of liver adenomas with the lowest risk for malignancy and hemorrhage (6).

Hepatic adenomas demonstrate various imaging findings based on their histologic subtypes and hemorrhagic components (6). MRI is the primary technique to evaluate the fat content and hemorrhage, which are very rare in metastasis, and is the best technique before biopsy to demonstrate steatotic changes, morphological characterization, and differential diagnosis of liver lesions (5,8). PET-MR scanning could also be taken into consideration for the identification of these lesions because it can determine both ^{18}F -FDG uptake and lesion characterization.

Informed Consent: Informed consent was obtained from the patients who participated in this study.

Peer-review: Externally peer-reviewed.

Author Contributions: Concept – A.Ö., B.K.S., N.İ., N.C.B., Y.T.; Design – A.Ö., B.K.S., N.İ., N.C.B., Y.T.; Supervision – A.Ö., B.K.S., N.İ., N.C.B., Y.T.; Resources – A.Ö., B.K.S., N.İ., N.C.B., Y.T.; Materials – A.Ö., B.K.S., N.İ., N.C.B., Y.T.; Data Collection and/or Processing – A.Ö., B.K.S., N.İ., N.C.B., Y.T.; Analysis and/or Interpretation – A.Ö., B.K.S., N.İ., N.C.B., Y.T.; Literature Search – A.Ö., B.K.S., N.İ., N.C.B., Y.T.; Writing Manuscript – A.Ö., B.K.S., N.İ., N.C.B., Y.T.; Critical Review – A.Ö., B.K.S., N.İ., N.C.B., Y.T.

Conflict of Interest: The authors have no conflict of interest to declare.

Financial Disclosure: The authors declared that this study has received no financial support.

REFERENCES

1. Flejou JF, Barge J, Menu Y, et al. Liver adenomatosis: an entity distinct from liver adenoma? *Gastroenterology* 1985; 89: 1132-8. [\[CrossRef\]](#)
2. Sanli Y, Bakir B, Kuyumcu S, et al. Hepatic adenomatosis may mimic metastatic lesions of liver with ^{18}F -FDG PET/CT. *Clin Nucl Med* 2012; 37: 697-8. [\[CrossRef\]](#)
3. Grazioli L, Federle MP, Ichikawa T, et al. Liver adenomatosis: clinical, histopathologic, and imaging findings in 15 patients. *Radiology* 2000; 216: 395-402. [\[CrossRef\]](#)
4. Lewin M, Handra-Luca A, Arrivé L, et al. Liver adenomatosis: classification of MR imaging features and comparison with pathologic findings. *Radiology* 2006; 241: 433-40. [\[CrossRef\]](#)
5. Grazioli L, Federle MP, Brancatelli G, Ichikawa T, Olivetti L, Blachar A. Hepatic adenomas: imaging and pathologic findings. *Radiographics* 2001; 21: 877-92. [\[CrossRef\]](#)
6. Lee SY, Kingham TP, LaGratta MD, et al. PET-avid hepatocellular adenomas: incidental findings associated with HNF1- α mutated lesions. *HPB (Oxford)*. 2016; 18: 41-8. [\[CrossRef\]](#)
7. Kim YH, Kim JY, Jang SJ, et al. F-18 FDG uptake in focal fatty infiltration of liver mimicking hepatic malignancy on PET/CT images. *Clin Nucl Med* 2011; 36: 1146-8. [\[CrossRef\]](#)
8. García García-Esquinas M, Ortega Candil A, Méndez R, Díaz Del Arco C, Arrazola García J, Carreras Delgado JL. Multiple liver adenomatosis with ^{18}F -FDG uptake: A rare manifestation of an infrequent entity. *Rev Esp Med Nucl Imagen Mol* 2016; 35: 279-80. [\[CrossRef\]](#)