

Small bowel obstruction after endoscopic fragmentation of a gastric bezoar: An unexpected complication

Gonçalo Nunes¹, Marta Patita¹, Rita Barosa¹, Manuela Canhoto¹, Lídia Roque Ramos¹, Patrícia Lages², Jorge Fonseca^{1,3} 

¹Department of Gastroenterology, Hospital Garcia de Orta, Almada, Portugal

²Department of Surgery, Hospital Garcia de Orta, Almada, Portugal

³Center for Interdisciplinary Research Egas Moniz (CiiEM), Monte da Caparica, Portugal

Cite this article as: Nunes G, Patita M, Barosa R, et al. Small bowel obstruction after endoscopic fragmentation of a gastric bezoar: An unexpected complication. *Turk J Gastroenterol* 2018; 29: 616-8.

Dear Editor,

Gastric bezoars are foreign bodies resulting from the accumulation of undigested material, mostly associated with impairment in the grinding mechanism and migration of the motor complex of the stomach. Phytobezoars are the most common type of bezoars, comprising vegetable fibers. Trichobezoars formed by hair and pharmacobezoars from undigested medications are less common (1).

We present the case of a 57-year-old man who was admitted for weight loss (>15% in 4 months) and recurrent vomiting. His medical history included type II diabetes mellitus and a gastroduodenal surgery 15 years before due to complicated peptic ulcer disease. On admission, he was malnourished and severely dehydrated. An abdominal computed tomography showed marked gastric distension due to partially occlusive heterogeneous lumi-

nal content in the antrum and proximal duodenum. On upper gastrointestinal endoscopy, a Billroth I partial gastrectomy was observed. A bulky bezoar extending from the distal body to the gastroduodenal anastomosis was identified and successfully broken up in fragments of <2 cm, using foreign body forceps and a polypectomy snare, after through-the-scope irrigation and needle injection with Coca-Cola® (Figure 1a, b). After the procedure, a solid diet was restarted. The patient became asymptomatic and was discharged the following day. He was advised to ingest large amounts of Coca-Cola® for a few weeks. After 3 days, he was readmitted because of recurrent vomiting, dehydration, and oral feeding intolerance. On endoscopy, his stomach was empty, but a striking distension of the duodenum and jejunum, filled by liquid and undigested material, prevented mucosal examination. Total parenteral nutrition was started to control malnutrition, and a magnetic resonance enterography performed 1 week later showed a 5.6×3.8-cm bezoar in the distal

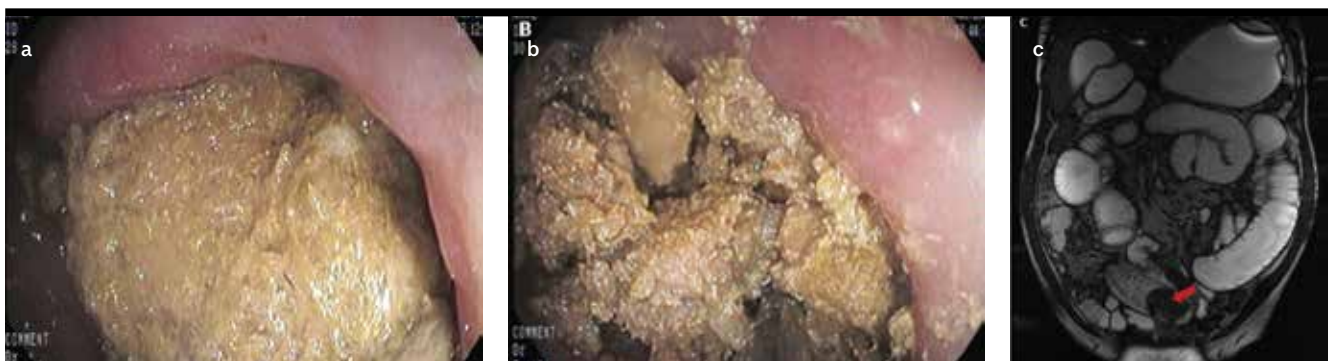

Figure 1. a-c. A bulky bezoar comprising undigested fibers is observed in the gastric body and antrum (a, b); a fragment impacted in the distal jejunum causing small bowel obstruction was detected in MRE after incomplete chemical dissolution and endoscopic removal (c)

ORCID ID of the author: J.F. 0000-0001-6477-7028.

Corresponding Author: Gonçalo Nunes; goncalo.n@hotmail.com

Received: January 8, 2018 Accepted: March 18, 2018 Available online date: August 2, 2018

© Copyright 2018 by The Turkish Society of Gastroenterology · Available online at www.turkjgastroenterol.org

DOI: 10.5152/tjg.2018.18029

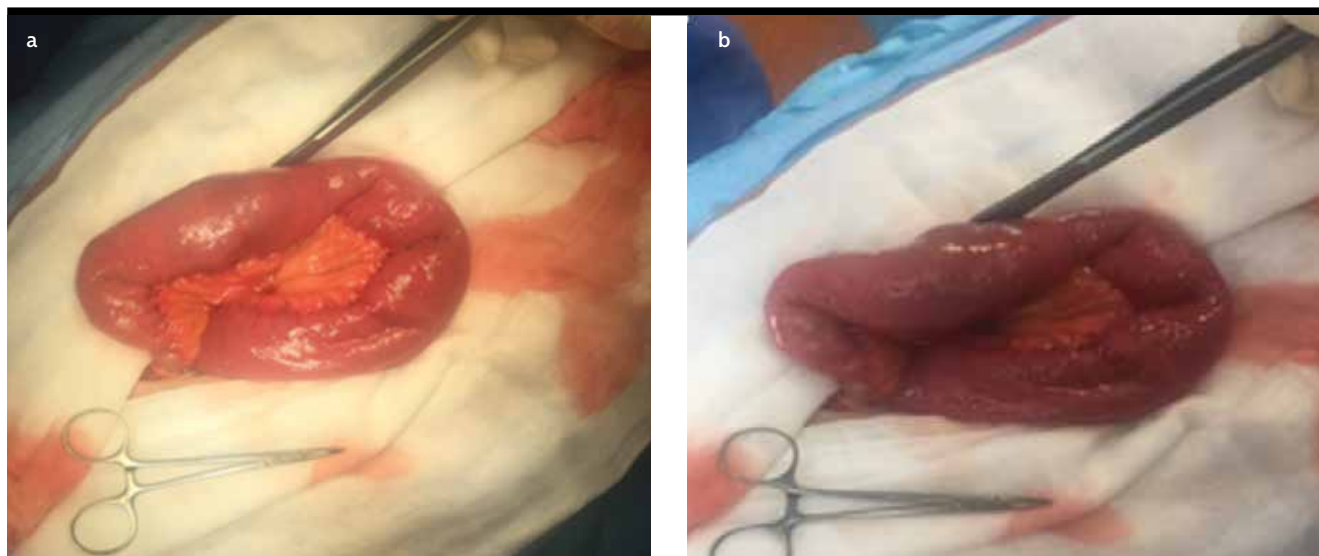


Figure 2. a, b. Intraoperative images showing a mild distended jejunal loop without significant vascular compromise (a); longitudinal enterotomy with bezoar removal and transversal enterorrhaphy were performed (b)

jejunum, surrounding parietal thickening, submucosal edema, and marked distension of upstream loops (Figure 1c). After surgical consultation, longitudinal enterotomy with bezoar removal and transversal enterorrhaphy were performed (Figure 2). A phytobezoar was confirmed by pathological analysis. The postoperative period was uneventful, and the patient resumed oral diet. No additional bezoar recurrence developed.

Gastric bezoars are rarely associated with severe gastrointestinal complications; nevertheless, visceral perforation, bleeding, intussusception, and appendicitis are described (2). Treatment includes chemical dissolution, prokinetics, endoscopic removal, and surgery. Chemical dissolution is a non-invasive and inexpensive approach, involving the administration of agents that degrade bezoars, such as Coca-Cola® and acetylcysteine (3,4). The effectiveness of Coca-Cola® was addressed in a systematic review of 24 observational studies with 46 patients, where complete dissolution was observed in 23 patients and partial dissolution in 19, which could be further endoscopically managed, and only 4 patients required surgery (3). The mechanism of action of Coca-Cola® may be related to its low pH, mucolytic effect of its high sodium bicarbonate concentration, and carbon dioxide bubbles that enhance dissolution (3). Endoscopic therapy involves fragmenting the bezoar using different mechanisms, namely forceps, snares, baskets, and argon plasma coagulation. The fragments can be cleared using an endoscope, removed using retrieval

devices, or allowed to pass through the gastrointestinal tract (5). Surgery is rarely needed unless severe complications develop, such as bowel obstruction that occurred in our patient (6). The previous gastroduodenal surgery and some degree of gastrointestinal dysmotility promoted by diabetes mellitus might have been an important cofactor in our patient.

The present report highlights an uncommon and potentially life-threatening complication of a gastric bezoar associated with incomplete chemical dissolution and endoscopic removal. We report the need for optimizing endoscopic removal aided by Coca-Cola® dissolution and avoiding leaving large fragments in the lumen, which can impact and occlude downstream. Close monitoring after bezoar dissolution may also be crucial to detect early complications.

Informed Consent: Informed consent was obtained from the patient who participated in this study.

Peer-review: Externally peer-reviewed.

Author Contributions: Concept - G.N.; Design - G.N.; Supervision - J.F.; Data Collection and/or Processing - G.N.; Analysis and/or Interpretation - G.N., M.T., R.B., M.C., L.R.R., P.L., J.F.; Literature Search - L.Z.; Writing Manuscript - G.N., M.T., R.B., M.C., L.R.R., P.L., J.F.; Critical Reviews - G.N., M.T., R.B., M.C., L.R.R., P.L., J.F.

Conflict of Interest: The authors have no conflict of interest to declare.

Financial Disclosure: The authors declared that this study has received no financial support.

REFERENCES

1. Lee J. Bezoars and foreign bodies of the stomach. *Gastrointest Endosc Clin N Am* 1996; 6: 605. [\[CrossRef\]](#)
2. Chintapalli KN. Gastric bezoar causing intramural pneumatosis. *J Clin Gastroenterol* 1994; 18: 264. [\[CrossRef\]](#)
3. Ladas SD, Kamberoglou D, Karamanolis G, et al. Systematic Review: Coca-Cola can effectively dissolve gastric phytobezoars as a first line treatment. *Aliment Pharmacol Ther* 2013; 37: 169. [\[CrossRef\]](#)
4. Schlang HA. Acetylcysteine in removal of bezoar. *JAMA* 1970; 214: 1329. [\[CrossRef\]](#)
5. Zarling EJ, Thompson LE. Nonpersimmon gastric phytobezoar. A benign recurrent condition. *Arch Pathol Lab Med* 1980; 104: 959.
6. Fallon SC, Slater BJ, Larimer EL, et al. The surgical management of Rapunzel syndrome: a case series and literatura review. *J Pediatr Surg* 2013; 48: 830. [\[CrossRef\]](#)