








An unusual cause of gastrointestinal bleeding and intestinal obstruction

Rosario Arena¹ , Stefano Gasperoni¹ , Andrea Lisotti² , Chiara A. A. Petrini¹ , Mario L. Brancaccio¹ , Omero Triossi¹ , Alessandro Mussetto¹ 

¹Division of Gastroenterology, S. Maria delle Croci Hospital, Ravenna, Italy

²Gastrointestinal Unit, Bologna University Hospital of Imola, Bologna, Italy

Cite this article as: Arena R, Gasperoni S, Lisotti A, et al. An unusual cause of gastrointestinal bleeding and intestinal obstruction. *Turk J Gastroenterol* 2018; 29: 365-6.

QUESTION

A 58-year-old male patient with melena and severe anemia presented to our attention. His medical history included hypercholesterolemia and arterial hypertension; nine months before admission, the patient underwent coronary stent implantation because of acute myocardial infarction and was started on dual anti-platelet therapy with aspirin and clopidogrel. He underwent urgent splenectomy because of trauma 30 years earlier. Melena was reported in the last two weeks; therefore, a gastroscopy and colonoscopy were performed on the patient, the results of which were negative. Small-bowel inves-

tigation with capsule endoscopy revealed an ulcerated lesion of the ileum protruding into the lumen causing a delayed passage of the capsule (Figure 1). A subsequent small-bowel CT-enteroclysis demonstrated the presence of four nodules through the ileal wall, the larger measuring 30x20 mm, with a strong contrast enhancement in the arterial phase (Figure 2). An oral double-balloon enteroscopy (DBE) was performed and the endoscope was advanced 3 m beyond the ligament of Treitz but the described lesion was not found. DBE through anal route was planned; however, the patient presented an acute bowel obstruction and underwent urgent surgery. Laparotomy revealed a small-bowel obstruction and an ileal resection was performed; on macroscopic evaluation, 27 cm of ileum presented multiple parietal nodules.

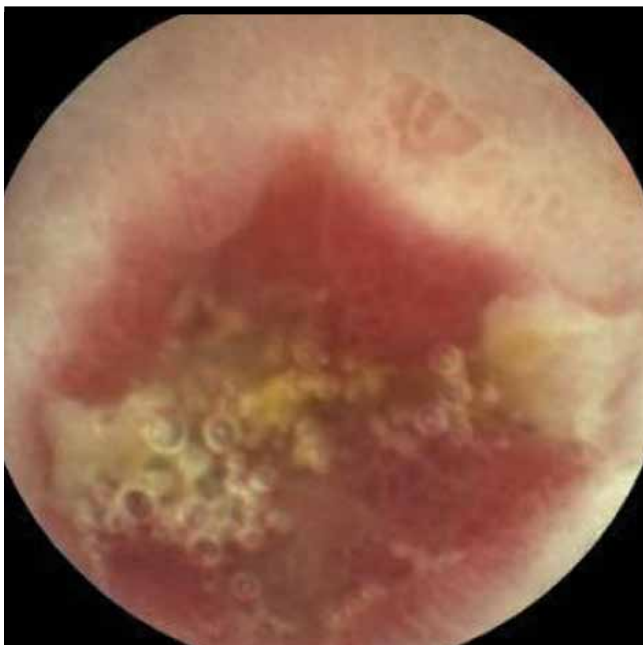

Figure 1. Capsule endoscopy revealed an ulcerated lesion of the ileum

What is the patient's most likely diagnosis?

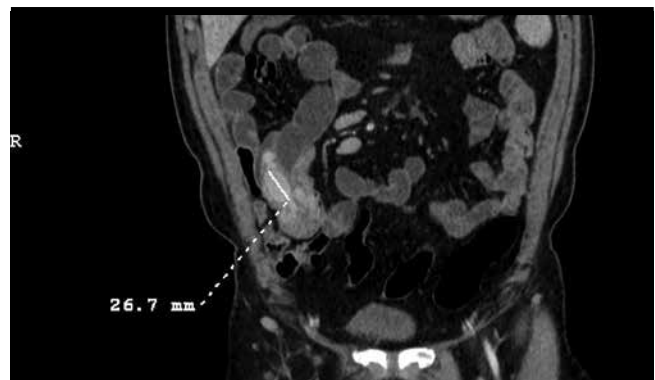


Figure 2. Small-bowel CT-enteroclysis demonstrated the presence of four nodules through the ileal wall, the larger measuring 30x20 mm, with a strong contrast enhancement in the arterial phase

ORCID IDs of the authors: R.A. 0000-0003-1140-2374; S.G. 0000-0002-8734-0694; A.L. 0000-0002-7724-7402; C.A.A.P. 0000-0003-2272-1872; M.L.B. 0000-0002-1192-9961; O.T. 0000-0001-6667-7872; A.M. 0000-0001-8140-4223.

Corresponding Author: **Rosario Arena**; rosario.arena84@gmail.com

Received: **October 12, 2017** Accepted: **December 3, 2017** Available Online Date: **April 6, 2018**

© Copyright 2018 by The Turkish Society of Gastroenterology · Available online at www.turkjgastroenterol.org

DOI: [10.5152/tjg.2018.17647](https://doi.org/10.5152/tjg.2018.17647)

ANSWER

Pathology examination revealed the presence of typical splenic parenchyma consisting of cords of red pulp alternating with white pulp (Figure 3-4). The patient was discharged after 5 days and subsequent follow-up was unremarkable. Splenosis is a frequent consequence/complication of traumatic splenic rupture because of the "transplantation" of splenic tissue through local mechanical seeding or hematogenous dissemination. The exact

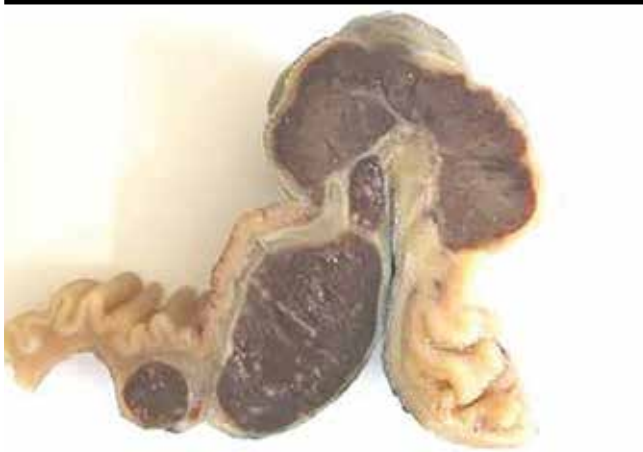

Figure 3. Macroscopic evaluation of ileum presented multiple parietal nodules

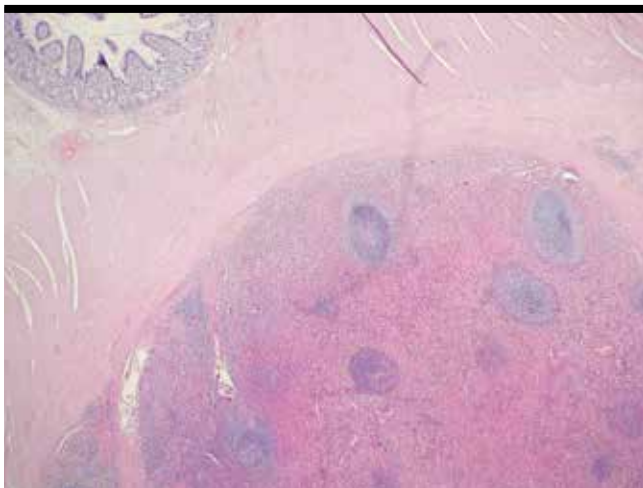


Figure 4. Pathology examination revealed the presence of typical splenic parenchyma consisting of cords of red pulp alternating with white

mechanism through which splenosis occurs is not clearly understood; the most plausible hypothesis is that splenic cells reach adjacent organs after capsule rupture; the preferential sites of splenosis are stomach, small bowel, peritoneum, and colon (1-2).

The diagnosis of splenosis could be done a few months after splenectomy or even after many decades. Those patients are usually asymptomatic and the diagnosis is accidental as a result of radiological examinations or surgery. However, in some cases, splenosis could present as an acute abdominal pain, bowel obstruction, or bleeding (3).

From a diagnostic point of view, splenosis can mimic several intra-abdominal neoplasia. Differential diagnoses of splenosis include endometriosis, peritoneal mesothelioma, renal neoplasms, abdominal lymphomas, GIST, small-bowel tumors, or peritoneal metastatic implants (4). In conclusion, splenosis must be considered in the differential diagnosis of patients with a history of splenectomy and suspected masses of unknown etiology.

Informed Consent: Informed consent was obtained from patient who participated in this study.

Peer-review: Externally peer-reviewed.

Author Contributions: Endoscopic Examinations - A.M., C.A.A.P., M.L.B.; Writing - R.A., S.G.; Critical Reviews - A.L., O.T.

Conflict of Interest: No conflict of interest was declared by the authors.

Financial Disclosure: The authors declared that this study has received no financial support.

REFERENCES

1. Akay S, Ilica AT, Battal B, Karaman B, Guvenc I. Pararectal mass: An atypical location of splenosis. *J Clin Ultrasound* 2012; 40: 443-7.
2. Brewster DC. Splenosis. *Am J Surg* 1973; 126: 14-9.
3. Younan G, Wills E, Hafner G. Splenosis: A Rare Etiology for Bowel Obstruction-A Case Report and Review of the Literature. *Case Rep Surg* 2015; 2015: 890602.
4. Imbriaco M, Camera L, Manciuira A, Salvatore M. A case of multiple intra-abdominal splenosis with computed tomography and magnetic resonance imaging correlative findings. *World J Gastroenterol* 2008; 14: 1453-5.