

Prevalence of advanced colorectal neoplasm is higher in liver transplant recipients

Eun Ae Kang¹ , Seong-Joon Koh² , Ji Won Kim² , Kook Lae Lee² , Jong Pil Im¹ , Joo Sung Kim¹ , Byeong Gwan Kim² 

¹Department of Internal Medicine and Liver Research Institute, Seoul National University School of Medicine, Seoul, Korea

²Department of Internal Medicine, Seoul National University Boramae Hospital, Seoul National University School of Medicine, Seoul, Korea

Cite this article as: Kang EA, Koh SJ, Kim JW, et al. Prevalence of advanced colorectal neoplasm is higher in liver transplant recipients. *Turk J Gastroenterol* 2018; 29: 316-24.

ABSTRACT

Background/Aims: Patients with liver transplantation are at increased risk of developing new malignancy because of the prolonged immunosuppression after transplantation. The aims of this study were to investigate whether advanced colorectal neoplasms occurs more in liver transplant recipients compared to healthy individuals and to evaluate the effect of immunosuppression on advanced colorectal neoplasia.

Materials and Methods: This was a retrospective, single-centered, case-control study. We reviewed 348 liver transplant patients who had undergone a colonoscopy after liver transplantation from 1991 to 2012. Healthy controls from asymptomatic individuals who had undergone colonoscopy for screening purposes were randomly selected and reviewed.

Results: Advanced colorectal neoplasms were identified in 17 of the 348 patients (4.9%). The risk of advanced colorectal neoplasia was 3.6 times greater in liver transplant patients (odds ratio [OR] 3.578; 95% confidence interval [CI] 1.578-8.115; $p=0.001$). The risk of developing colon cancer was 8.4 times higher in transplant patients (OR 8.416; 95% CI 1.808-39.172; $p=0.001$).

Conclusion: Liver transplant recipients were at a high risk of colorectal cancer. Therefore, colonoscopy surveillance after liver transplantation is recommended. Immunosuppressive therapy could facilitate carcinogenesis.

Keywords: Liver transplantation, colorectal neoplasms, adenoma, immunosuppression

INTRODUCTION

Colorectal cancer (CRC) is the third major cause of cancer mortality in the United States; its incidence has been increasing, and it has become the fourth leading cause of cancer mortality in 2012 in the country (1,2). CRC can be prevented or detected early by cancer screening. The recommendations for CRC screening are to choose fecal occult blood tests every year with or without sigmoidoscopy every 5 years, or colonoscopy every 10 years in asymptomatic adults older than 50 years (3). It is important to determine the appropriate intervals of endoscopic examinations for CRC in high-risk groups based on the likelihood of developing advanced colorectal neoplasms because of concerns regarding interval cancer (4).

Liver transplantation (LT) is considered a specific treatment for end-stage liver disease with various etiologies (5). However, post-transplant patients are highly likely to develop new malignancies. Increased risk of skin and

lymphoid malignancies has been reported in patients with LT (6,7). The increased risk of cancer is primarily a consequence of the immunosuppressive agents administered after LT. Furthermore, the improved survival of post-transplant patients and the advanced age at which patients receive transplantation have added further risks of new malignancies, because cancer, in general, is more common in the elderly (8). However, only few studies have investigated CRC in patients with LT, and these studies have shown conflicting results (9-13). Several studies have shown that CRC is more common in patients who have undergone LT, particularly because of primary sclerosing cholangitis (PSC) (12,14,15). Nevertheless, because PSC is not a common etiology of terminal liver disease in the country, it is necessary to check whether the advanced colorectal neoplasms, including CRC, increase in relation to patients with LT. In addition, it is important to demonstrate the necessity of frequent colonoscopy surveillance among patients with LT.

ORCID IDs of the authors: E.A.K. 0000-0003-0220-937X; S.J.K. 0000-0001-8001-8777; J.W.K. 0000-0002-1214-5544; K.L.L. 0000-0001-6676-9451; J.P.I. 0000-0003-1584-0160; J.S.K. 0000-0001-6835-4735; B.G.K. 0000-0003-0965-226X.

Corresponding Author: Byeong Gwan Kim; caskim@brm.org

Received: July 28, 2017 Accepted: January 2, 2018

© Copyright 2018 by The Turkish Society of Gastroenterology · Available online at turkjgastroenterol.org

DOI: 10.5152/tjg.2018.17458

The present study aimed to investigate whether the prevalence of advanced colorectal neoplasms increased in LT recipients and to determine the effect of immunosuppressants on the development of advanced colorectal neoplasia.

MATERIALS AND METHODS

This was a retrospective case-control study in a university-affiliated hospital and was approved by the Institutional Review Board of our institution (No. H 1304-012-477). We reviewed 1496 patients who had received LT between January 1991 and December 2012. A total of 348 patients who underwent colonoscopy at least once after LT were ultimately included in the patient group. Age-, gender-, and body mass index (BMI)-matched healthy controls were randomly selected from among asymptomatic healthy adults who had undergone screening colonoscopy at the health promotion center of our institution between the study period. Patients who underwent colonoscopy because of gastrointestinal symptoms were excluded from the study. Furthermore, subjects with inflammatory bowel disease (IBD), history of CRC, or major bowel surgery were also excluded. The primary goal of this study was to compare the prevalence of advanced colorectal neoplasms between patients and controls. We reviewed electrical medical records and obtained clinical data. Written informed consent was obtained from the eligible patients before investigation.

Definitions

Colonoscopy was conducted at the Gastrointestinal Endoscopy Center of our institution. All colonoscopies were performed by experienced gastroenterologists using the CF-H260 and CF-240L colonoscopies (Olympus, Tokyo, Japan). Complete endoscopy was performed according to the guidelines for colonoscopy quality management. The quality indicators of colonoscopy included are as follows: whether the cecum is inserted, a colonoscopy withdrawal time of at least 6 minutes, and appropriate intestinal cleansing for visualization. All abnormal lesions were removed by biopsy or endoscopic mucosal resection. The size of the lesions was measured in comparison with the length of the biopsy forceps. Advanced colorectal adenomas were characterized as having a size greater than 1 cm, a villous component, or showing a high grade of dysplasia. Serrated adenomas larger than 1 cm were also included in advanced colorectal adenomas (16,17). Advanced neoplasms included both advanced adenoma and invasive carcinoma. Non-advanced adenomas were defined as those sized less than 1 cm, with low-grade dysplasia, or having less than 25% villous components.

When lesions were multiple, the most advanced pathology was selected as the definitive lesion.

Statistical analysis

We calculated odds ratios (ORs) of colorectal neoplasms in LT recipients compared with that in healthy controls using the Pearson's chi-square test and Fisher's exact test with 95% confidence intervals (CIs). A $p < 0.050$ was considered statistically significant. To evaluate the effects of immunosuppressive agents or other factors on advanced colorectal neoplasia in patients with LT, the univariate test was performed using a logistic regression model, and the multivariate analysis was performed using a Cox proportional hazard model. To estimate the time taken to detect colorectal neoplasms according to the prior colonoscopy findings before LT, the Kaplan-Meier analysis and log-rank test were used. All statistical analyses were performed using the Statistical Package for Social Sciences (SPSS) software for Windows, version 22.0 (IBM Corp.; Armonk, NY, USA).

RESULTS

Patient characteristics

A total of 348 patients who received LT were assessed; their baseline demographics and clinical characteristics are presented in Table 1. The mean patient age was 58 years, and 79.9% patients were male. Hepatitis B virus was the commonest cause of liver failure in patients with LT. The mean interval from LT to colonoscopy was 11.4 months. A total of 264 patients (75.9%) received a liver from a cadaveric donor, and 183 (52.6%) patients had liver cirrhosis with Child-Pugh class A. A treatment based on tacrolimus was the most commonly used immunosuppressive therapy after LT. The duration of immunosuppression was the time of colonoscopy after LT. The mean duration of immunosuppressant use was 1.44 years. Of the 348 patients, 100 underwent colonoscopy before as well as after LT. Their characteristics including age, sex, time of colonoscopy before and after LT, and reasons for performing colonoscopy are also presented in Table 1.

Colonoscopy findings

Among the patients with LT, 100 (28.7%) underwent screening colonoscopy prior to LT. Of the patients who underwent colonoscopy before LT, two (2.0%) had adenoma with villous components, 13 (13.0%) had low-grade tubular adenoma, three (3.0%) had hyperplastic polyps, and one (1.0%) had inflammatory polyps. Among the patients who received diagnostic colonoscopy after LT, 17 (4.9%) had advanced colorectal neoplasms, including CRC (9 pa-

Table 1. Patient demographics and clinical characteristics (n=348)

Variables	Patients with LT (n=348)	Patients with colonoscopy before LT* (n=100)
Age (years)	58.44±8.8	58.82±7.5
Gender (Male/Female, %)	278 (79.9)/ 70 (20.1)	82 (82)/ 18 (18)
Age at colonoscopy (years)	53.59±9.2	52.59±7.2
Reasons for performing colonoscopy		
Screening (%)	331 (95.1)	98 (98)
Symptoms [†] (%)	17 (4.9)	2 (2)
Time of colonoscopy before LT (months)		2.74±6.74
Time of colonoscopy after LT (years)	2.52±2.62	2.88±2.66
BMI (kg/m ²)	22.65±3.06	22.27±3.33
Smoking		
Never smoked (%)	319 (91.7)	
Ex-smoker (%)	10 (2.9)	
Current smoker (%)	19 (5.5)	
Etiology of liver failure		
HBV (%)	296 (85.1)	
HCV (%)	17 (4.9)	
Alcoholic (%)	13 (3.7)	
Others [‡] (%)	22 (6.3)	
Donor		
Cadaveric (%)	264 (75.9)	
Living (%)	84 (24.1)	
Child-Pugh class		
A (%)	183 (52.6)	
B (%)	139 (39.9)	
C (%)	26 (7.5)	
Esophageal varix		
Yes (%)	97 (27.9)	
No (%)	251 (72.1)	

tients, 2.6%), adenoma sized >10 mm (1 patient, 0.3%), high-grade dysplasia (4 patients, 1.1%), and tubulovillous or villous adenoma (3 patients, 0.9%). In the healthy control group, advanced colorectal neoplasms were detected using colonoscopy in 9 patients (1.4%), including 2 with CRC (0.3%). Detailed data are presented in Table 2.

Ascites	
Yes (%)	97 (27.9)
No (%)	251 (72.1)
Hepatic encephalopathy	
Yes (%)	149 (42.8)
No (%)	199 (57.2)
HCC	
Yes (%)	98 (28.2)
No (%)	250 (71.8)
MELD score	13.24±6.33
Total bilirubin	2.98±4.83
Albumin	3.677±1.94
Creatinine	1.243±1.06
Type of immunosuppressant	
TAC (%)	310 (89.1)
CSA (%)	13 (3.7)
Sirolimus (%)	4 (1.1)
Other monotherapy (%)	6 (1.7)
Other combination (%)	15 (4.3)
Duration of immunosuppression (years)	1.44±8.93
<3 years (%)	238 (68.4)
3-5 years (%)	42 (12.1)
>5 years (%)	68 (19.5)

Data are presented as mean±SD or number (%)

LT: liver transplantation; BMI: body mass index; HBV: hepatitis B virus; HCV: hepatitis C virus; HCC: hepatocellular carcinoma; MELD: model for endstage liver disease; TAC: tacrolimus; CSA: cyclosporin A

*All patients who underwent colonoscopy before LT received colonoscopy after LT

[†]Symptoms include weight loss, bowel habit changes, abdominal pain, hematochezia, and melena

[‡]Others included primary sclerosing cholangitis, primary biliary cirrhosis, autoimmune hepatitis, biliary atresia, Wilson's disease, Langerhans cell histiocytosis, and lupus hepatitis

Prevalence of advanced colorectal neoplasms

Advanced colorectal neoplasms occurred 3.6 times more frequently in patients with transplants than in patients in the healthy control group (OR, 3.578; 95% CI, 1.578-8.115; p=0.001). The OR of advanced colorectal adenoma in LT patients compared with healthy controls was 2.114; however, this was not significant (95% CI, 0.760-5.880; p=0.142). The OR of CRC in patients with LT was

Table 2. Colonoscopy findings between liver transplant patients and healthy controls

Colonoscopy findings	Patients with Pre-LT screening (n=100)	Patients with post-LT screening (n=348)	Healthy control (n=636)
Colorectal cancer (%)	(Exclusion criteria)	9 (2.6)	2 (0.3)
≥10 mm adenoma (%)	0 (0.0)	1 (0.3)	0 (0)
High-grade dysplasia (%)	0 (0.0)	4 (1.1)	2 (0.3)
Tubulovillous or villous adenoma (%)	2 (2.0)	3 (0.9)	5 (0.8)
Normal (%)	81 (81.0)	253 (72.7)	465 (73.1)
Low-grade tubular adenoma (%)	13 (13.0)	42 (12.1)	122 (19.1)
≥3 adenomas (%)	0 (0.0)	6 (1.7)	1 (0.2)
Hyperplastic polyp (%)	3 (3.0)	27 (7.8)	38 (6.0)
Inflammatory polyp (%)	1 (1.0)	3 (0.9)	1 (0.2)
Serrated polyp (%)	0 (0.0)	0 (0.0)	0 (0.0)

Data are presented as number (%)

LT: liver transplantation

Table 3. Odds ratio for the risk of colorectal neoplasms between liver transplant patients and healthy controls (n=984)

	Patients with LT (n=348)	Healthy controls (n=636)	Odds ratio (95% CI)	p
Advanced neoplasm* (%)	17 (4.89)	9 (1.42)	3.578 (1.578-8.115)	0.001
Advanced adenoma [†] (%)	8 (2.30)	7 (1.10)	2.114 (0.760-5.880)	0.142
Colorectal cancer (%)	9 (2.59)	2 (0.31)	8.416 (1.808-39.172)	0.001
Non-advanced neoplasm [‡] (%)	78 (22.41)	162 (25.47)	0.845 (0.621-1.151)	0.286
Total adenomatous neoplasm (%)	95 (27.30)	171 (26.89)	1.021 (0.761-1.370)	0.889

LT: liver transplantation; CI: confidence interval

*Advanced neoplasm includes advanced adenoma or colorectal cancer

[†]Advanced adenoma was defined as size ≥10 mm in diameter and/or containing >25% villous or tubulovillous histologic characteristics and/or high-grade dysplasia

[‡]Non-advanced neoplasm was defined as adenoma sized <10-mm in size with low-grade dysplasia and/or containing ≤25% villous component

8.4 times greater than that in healthy controls (95% CI, 1.808-39.172; p=0.001; Table 3).

Regardless of LT, screening colonoscopy for detecting CRC is recommended for those aged 50 years or older. Therefore, the prevalence of advanced colorectal neoplasms was analyzed according to age. When analyzed in patients over 50 years of age, it was observed that patients with LT had highly advanced colorectal neoplasms than healthy controls (OR, 2.883; 95% CI, 1.257-6.609; p=0.009; Table 4).

Patients with normal colonoscopy findings prior to LT were compared with healthy controls to determine whether the post-transplantation conditions, including immunosuppression, could affect the development of colonic neoplasms (Table 5). Patients with normal colonoscopy findings before LT (n=81) had a higher risk of developing advanced colonic neoplasms including CRC (OR, 4.583; 95% CI, 1.497-14.031; p=0.004).

Risk factors for advanced colorectal neoplasms after LT

The risk factors of advanced colorectal neoplasms after

Table 4. Odds ratio for the risk of colorectal neoplasms between patients with liver transplants and healthy controls older than 50 years (n=780)

	Patients with LT, Age ≥50 (n=304)	Healthy controls, Age ≥50 (n=476)	Odds ratio (95% CI)	p
Advanced neoplasm* (%)	16 (5.26)	9 (1.89)	2.883 (1.257-6.609)	0.009
Advanced adenoma [†] (%)	7 (2.30)	7 (1.47)	1.579 (0.548-4.547)	0.393
Colorectal cancer (%)	9 (2.96)	2 (0.42)	7.231 (1.552-33.695)	0.003
Non-advanced neoplasm [‡] (%)	74 (24.34)	141 (29.62)	0.764 (0.551-1.061)	0.108
Total adenomatous neoplasm (%)	90 (29.61)	150 (31.51)	0.914 (0.668-1.250)	0.574

LT: liver transplantation; CI: confidence interval

*Advanced neoplasm includes advanced adenoma or colorectal cancer

[†]Advanced adenoma was defined as size ≥10 mm in diameter and/or containing >25% villous or tubulovillous histologic characteristics and/or high-grade dysplasia[‡]Non-advanced neoplasm was defined as adenoma sized <10 mm in size with low-grade dysplasia and/or containing ≤25% villous component**Table 5.** Comparison of patients with liver transplants with normal colonoscopy findings before transplantation in healthy controls (n=717)

	Patients with LT (n=81)	Healthy controls, (n=636)	Odds ratio (95% CI)	p
Advanced neoplasm (%)	5 (6.2)	9 (1.4)	4.583 (1.497-14.031)	0.004
Advanced adenoma (%)	2 (2.5)	7 (1.1)	2.275 (0.464-11.142)	0.297
Colorectal cancer (%)	3 (3.7)	2 (0.3)	12.192 (2.006-74.098)	0.001
Non-advanced neoplasm (%)	12 (14.8)	162 (25.5)	0.509 (0.269-0.964)	0.035
Total adenomatous neoplasm (%)	17 (21.0)	171 (26.9)	0.722 (0.411-1.268)	0.256

LT: liver transplantation; CI: confidence interval

LT were assessed using univariate and multivariate analysis. In a univariate analysis with logistic regression, no risk factors had significant impacts on the development of advanced neoplasms after LT. The type of immunosuppressant and duration of immunosuppression had no significant impact on the occurrence of advanced colorectal neoplasm (Table 6). On the other hand, the univariate analysis of overall colorectal neoplasms in LT patients showed that age, male sex, and the presence of previous advanced colorectal neoplasms were significantly associated with advanced colorectal neoplasms (Table 6). Among these factors, male gender and the presence of previous advanced neoplasms were statistically significant in multivariate analysis.

Development of colorectal neoplasms after LT

The time taken to detect colorectal neoplasms was analyzed in patients who had normal findings (n=81) or

non-advanced neoplasms (n=17) on colonoscopy findings before LT (in total, n=98). CRC was detected in 3 of 77 patients (3.90%) <5 years after LT and in 1 of 21 patients (4.76%) >5 years after LT. Advanced adenoma was detected in one patient (1.30%) <5 years after LT and in 1 patient (4.76%) >5 y after LT (Table 7). The cumulative incidence between the patients who had normal findings (normal group) and non-advanced neoplasms (low-risk group) on colonoscopy before LT were not significantly different (p=0.953) (Figure 1). The cumulative incidence of the entire colorectal neoplasms was not statistically different between the normal and low-risk groups (p=0.066; Figure 2).

DISCUSSION

This study aimed to analyze the occurrence of advanced colorectal neoplasms in LT recipients compared with healthy controls and to establish the effect of immuno-

Table 6. Risk factors of advanced colorectal neoplasm in liver transplant patients

	Univariate analysis HR (95% CI)	p	Multivariate analysis HR (95% CI)	p
Advanced colorectal neoplasm				
Age (≥50 years)	1.052 (0.986-1.122)	0.128	1.029 (0.921-1.150)	0.616
BMI (kg/m ²)	0.904 (0.764-1.070)	0.240	1.012 (0.829-1.235)	0.909
Immunosuppressant	2.337 (0.767-7.122)	0.136	2.204 (0.601-8.082)	0.233
Duration of immunosuppression*				
<3 years				
3-5 years	1.288 (0.382-4.339)	0.683	1.086 (0.313-3.776)	0.896
>5 years	0.752 (0.226-2.506)	0.643	0.708 (0.199-2.516)	0.594
Gender	0.844 (0.236-3.023)	0.795		
Presence of HCC	0.932 (0.346-2.508)	0.889		
Previous advanced neoplasm	1.661 (0.203-13.580)	0.636		
Overall colorectal neoplasm				
Age (≥50 years)	1.034 (1.004-1.064)	0.027	0.920 (0.817-1.037)	0.173
BMI (kg/m ²)	1.059 (0.980-1.145)	0.146	1.077 (0.790-1.469)	0.638
Immunosuppressant	1.360 (0.734-2.521)	0.328	1.286 (0.177-9.337)	0.803
Duration of immunosuppression*				
<3 years				
3-5 years	1.376 (0.727-2.604)	0.327	1.199 (0.615-2.340)	0.595
>5 years	1.460 (0.855-2.495)	0.166	1.381 (0.777-2.457)	0.271
Gender	0.486 (0.248-0.952)	0.036	0.451 (0.216-0.942)	0.034
Presence of HCC	0.905 (0.561-1.461)	0.684		
Previous advanced neoplasm	4.543 (1.447-14.257)	0.009	3.971 (1.220-12.926)	0.022

HR: hazard ratio; CI: confidence interval; BMI: body mass index; HCC: hepatocellular carcinoma

*The duration of immunosuppression is the time of colonoscopy after LT; the number of patients and the mean duration of maintenance of the immunosuppressant are specified in Table 1

suppressive therapy on advanced colorectal neoplasia. In this study, patients with LT were found to have a higher risk of developing advanced colorectal neoplasms, particularly CRC. With these results, we recommend surveillance colonoscopy for patients with LT because of the higher risk of developing CRC. As mentioned above, patients with normal colonoscopy findings before LT (n=81) also had a higher risk of developing CRC than the controls (Table 5). This suggests that CRC in patients with LT was affected by post-transplant circumstances. However, it is unclear what facilitates carcinogenesis in patients with LT.

Several studies have investigated whether the secondary cancer risk is higher in patients with LT; however, the results of these studies remain controversial. As mentioned in the introduction, PSC with or without IBD is known to relate with increasing relative risk of CRC after LT. In this study, however, we had only two cases of PSC, and these patients did not have advanced colorectal neoplasms. Therefore, PSC had no significant impact on the results. Several previous studies are consistent with our results (6,8,10,11,13,18). Indeed, increased relative risk of CRC after LT was related to post-transplant conditions, including

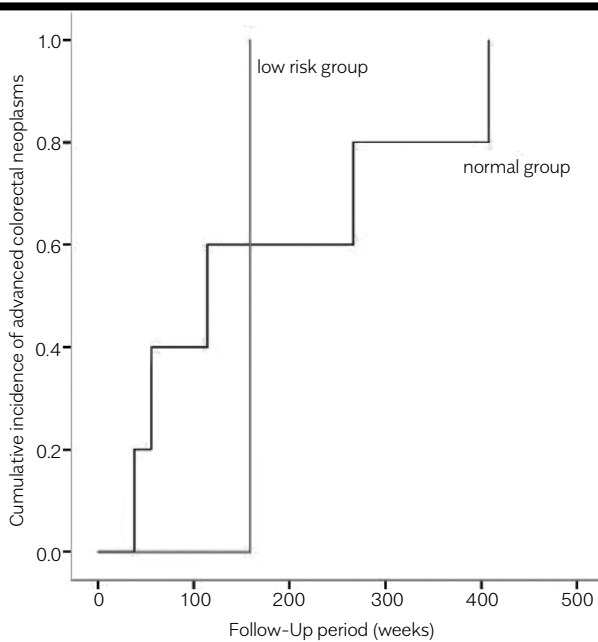


Figure 1. Cumulative incidence of advanced colorectal neoplasms according to colonoscopy findings before liver transplantation ($p=0.953$ by log-rank test)

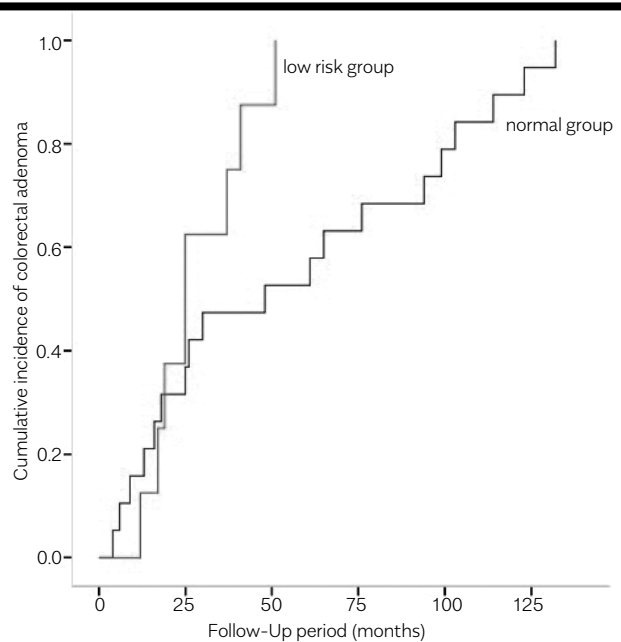


Figure 2. Cumulative incidence of overall colorectal neoplasms according to colonoscopy findings before liver transplantation ($p=0.066$ by log-rank test)

immunosuppression. One hypothesis is that long-standing immunosuppressive therapies after LT cause immunotolerance of malignant cells and weaken the antitumor response. A report of cancer risk following organ transplantation in a Swedish cohort suggested that immunomodulation was the most important factor in cancer development, particularly in oncogenic virus-associated malignancies (19). Another report showed cases of Epstein-Barr virus-associated cecal post-transplant lymphoproliferative tumors and human papillomavirus-associated anal tumors after LT (20). Selgrad et al. (21) reported that the John Cunningham virus infection may undergo reactivation by immunosuppressive agents and may be implicated in colorectal carcinogenesis after LT.

It is thought that de novo CRC in patients with CRC is characterized by rapid growth and aggressive features. Unlike advanced colorectal neoplasms in patients with LT, the prevalence of non-advanced colorectal neoplasms was not statistically different between LT patients and controls. It implied that the post-transplant situation could increase the risk of CRC by promoting cancer progression from non-advanced neoplasms to cancer, rather than initiating carcinogenesis. As shown in Table 7, three patients (3.90%) with either normal colonoscopies or non-advanced colorectal neoplasms before LT developed CRC <5

years after LT. Although the number of cases was small, there remains a possibility of different biological characteristics of tumor growth among patients with transplants. Furthermore, rapid growth or an aggressive nature could be synergistically facilitated by immunosuppressive therapy, regardless of oncogenic viruses. An in vivo study reported the impact of cyclosporine on cancer progression by a direct cellular effect; it suggested that cyclosporine played a direct role in tumor growth by the production of cyclosporine-induced transforming growth factor- β (22).

Patients older than 50 years were analyzed because screening colonoscopy is first recommended at that age. Compared with controls, the relative risk of CRC was still high in patients with LT older than 50 years. Therefore, physicians should know the potential risks and make an effort of having careful colonoscopy verification, such as adequate bowel preparation and average withdrawal time more than 6 min, particularly for patients with LT older than 50 years. However, the number of advanced colorectal neoplasm cases reported in the healthy controls was lesser than the known average prevalence (1.42% vs. 5.6%) (23). The reason for the low prevalence of advanced neoplasms can be explained by the younger median age (55.89 ± 11.10 years) and smaller proportion of men (62.3%) in the control group.

We analyzed the possible confounding factors, including age, sex, BMI, type of immunosuppressive agent, duration of immunosuppression after LT, presence of hepatocellular carcinoma, and presence of advanced colorectal neoplasm before LT, using univariate and multivariate analyses. There were no significant risk factors of advanced colorectal neoplasm. On the other hand, older age could be a risk factor for the development of overall colorectal neoplasms in univariate analysis, and male sex or presence of a previous advanced neoplasm could be risk factors of colorectal neoplasms in univariate and multivariate analyses. A tacrolimus-based immunosuppressant regimen was the main treatment method at our center (89.1%) and had no significant impact on the CRC prevalence compared with other regimens. However, our study is limited by the cross-sectional study design. Further studies are warranted to elucidate the effects of immunosuppressant in the incidence of colorectal neoplasm.

Except for patients with advanced colorectal neoplasm before LT (n=2), a total of 98 patients were investigated using the Kaplan-Meier analysis and log-rank test to determine the appropriate interval of colonoscopy after LT. We divided patients into low-risk (patients who had a non-advanced colorectal neoplasm before transplantation) and normal (no colorectal neoplasm before transplantation) groups. We observed that advanced colorectal neoplasms occurred earlier in the low-risk group than in the normal group; however, the results were not significant, owing to a very small number of cases. The cumulative incidence of overall colorectal neoplasms was also higher in the low-risk group, although this was not significant. On the basis of the results, short-term interval of colonoscopy may be needed in patients who had an adenomatous polyp before LT. Prospective studies are warranted to determine the appropriate interval of colonoscopy in patients after LT.

Our study had several limitations. It was a retrospective study, and all the data was obtained using electronic medical records. A large portion of LT patients were excluded because of the lack of records or because they did not undergo colonoscopy. Furthermore, recall and selection bias could affect the results, as LT patients tend to have more concerns about disease and have more frequent chances for colonoscopy screening than the normal population.

In conclusion, the prevalence of advanced colorectal neoplasms, including CRC, is higher in patients with LT than in healthy controls. Physicians should recognize risk fac-

tors of developing colorectal neoplasms and recommend colonoscopy more strongly to patients after LT.

Ethics Committee Approval: Ethics committee approval was received for this study from Institutional Review Board of Seoul National University (Decision No: H 1304-012-477).

Informed Consent: Written informed consent was obtained from patients who participated in this study.

Peer-review: Externally peer-reviewed.

Author Contributions: Concept - E.A.K., S.J.K.; Design - B.G.K.; Supervision - J.W.K.; Materials - K.L.L., J.P.I., J.S.K.; Data Collection and/or Processing - J.S.K.; Analysis and/or Interpretation - E.A.K.; Literature Search - E.A.K., S.J.K.; Writing - B.G.K.; Critical Reviews - B.G.K.

Conflict of Interest: The authors have no conflict of interest to declare.

Financial Disclosure: The authors declared that this study has received no financial support.

REFERENCES

1. Siegel RL, Miller KD, Jemal A. Cancer statistics, 2016. *CA Cancer J Clin* 2016; 66: 7-30. [\[CrossRef\]](#)
2. Jung KW, Won YJ, Kong HJ, et al. Cancer statistics in Korea: incidence, mortality, survival, and prevalence in 2012. *Cancer Res Treat* 2015; 47: 127-41. [\[CrossRef\]](#)
3. Rex DK, Johnson DA, Anderson JC, et al. American College of Gastroenterology guidelines for colorectal cancer screening 2009 [corrected]. *Am J Gastroenterol* 2009; 104: 739-50. [\[CrossRef\]](#)
4. Lieberman DA, Rex DK, Winawer SJ, Giardiello FM, Johnson DA, Levin TR. Guidelines for colonoscopy surveillance after screening and polypectomy: a consensus update by the US Multi-Society Task Force on Colorectal Cancer. *Gastroenterology* 2012; 143: 844-57. [\[CrossRef\]](#)
5. National Institutes of Health Consensus Development Conference: liver transplantation. *R I Med J* 1984; 67: 73-6.
6. Haagsma EB, Hagens VE, Schaapveld M, et al. Increased cancer risk after liver transplantation: a population-based study. *J Hepatol* 2001; 34: 84-91. [\[CrossRef\]](#)
7. Frezza EE, Fung JJ, van Thiel DH. Non-lymphoid cancer after liver transplantation. *Hepatogastroenterology* 1997; 44: 1172-81.
8. Nishihori T, Strazzabosco M, Saif MW. Incidence and management of colorectal cancer in liver transplant recipients. *Clin Colorectal Cancer* 2008; 7: 260-6. [\[CrossRef\]](#)
9. Atassi T, Thuluvath PJ. Risk of colorectal adenoma in liver transplant recipients compared to immunocompetent control population undergoing routine screening colonoscopy. *J Clin Gastroenterol* 2003; 37: 72-3. [\[CrossRef\]](#)
10. Rudraraju M, Osowo AT, Singh V, Carey EJ. Do patients need more frequent colonoscopic surveillance after liver transplantation? *Transplant Proc* 2008; 40:1522-24. [\[CrossRef\]](#)
11. Sint Nicolaas J, de Jonge V, Steyerberg EW, Kuipers EJ, van Leerdam ME, Veldhuyzen-van Zanten SJ. Risk of colorectal carcinoma in post-liver transplant patients: a systematic review and meta-analysis. *Am J Transplant* 2010; 10: 868-76. [\[CrossRef\]](#)
12. Silva MA, Jambulingam PS, Mirza DF. Colorectal cancer after orthotopic liver transplantation. *Crit Rev Oncol Hematol* 2005; 56: 147-53. [\[CrossRef\]](#)

13. Lee HS, Yoo DJ, Park HW, et al. Is a stricter colonoscopy screening protocol necessary in liver transplant recipients? Comparison with an average-risk population. *Dis Colon Rectum* 2014; 57: 976-82. [\[CrossRef\]](#)
14. Safaeian M, Robbins HA, Berndt SI, Lynch CF, Fraumeni JF Jr., Engels EA. Risk of Colorectal Cancer After Solid Organ Transplantation in the United States. *Am J Transplant* 2016; 16: 960-7. [\[CrossRef\]](#)
15. Soetikno RM, Lin OS, Heidenreich PA, Young HS, Blackstone MO. Increased risk of colorectal neoplasia in patients with primary sclerosing cholangitis and ulcerative colitis: a meta-analysis. *Gastrointest Endosc* 2002; 56: 48-54. [\[CrossRef\]](#)
16. Gschwantler M, Kriwanek S, Langner E, et al. High-grade dysplasia and invasive carcinoma in colorectal adenomas: a multivariate analysis of the impact of adenoma and patient characteristics. *Eur J Gastroenterol Hepatol* 2002; 14: 183-8. [\[CrossRef\]](#)
17. Schlemper RJ, Riddell RH, Kato Y, et al. The Vienna classification of gastrointestinal epithelial neoplasia. *Gut* 2000; 47: 251-5. [\[CrossRef\]](#)
18. Jung DH, Hwang S, Song GW, et al. Survival Benefit of Early Cancer Detection Through Regular Endoscopic Screening for De Novo Gastric and Colorectal Cancers in Korean Liver Transplant Recipients. *Transplant Proc* 2016; 48: 145-51. [\[CrossRef\]](#)
19. Adami J, Gabel H, Lindelof B, et al. Cancer risk following organ transplantation: a nationwide cohort study in Sweden. *Br J Cancer* 2003; 89: 1221-27. [\[CrossRef\]](#)
20. Albright JB, Bonatti H, Stauffer J, et al. Colorectal and anal neoplasms following liver transplantation. *Colorectal Dis* 2010; 12: 657-66. [\[CrossRef\]](#)
21. Selgrad M, Koornstra JJ, Fini L, et al. JC virus infection in colorectal neoplasia that develops after liver transplantation. *Clin Cancer Res* 2008; 14: 6717-21. [\[CrossRef\]](#)
22. Hojo M, Morimoto T, Maluccio M, et al. Cyclosporine induces cancer progression by a cell-autonomous mechanism. *Nature* 1999; 397: 530-4. [\[CrossRef\]](#)
23. Regula J, Rupinski M, Kraszewska E, et al. Colonoscopy in colorectal-cancer screening for detection of advanced neoplasia. *N Engl J Med* 2006; 355: 1863-72. [\[CrossRef\]](#)