



Unexpected outcome following radiofrequency ablation of a malignant biliary stricture

Andrew J. Kruger¹ , Somashekar G. Krishna² 

¹Department of Internal Medicine, The Ohio State University Wexner Medical Center, Columbus, OH, USA

²Division of Gastroenterology, Hepatology and Nutrition, The Ohio State University Wexner Medical Center, Columbus, OH, USA

Cite this article as: Kruger AJ, Krishna SG. Unexpected outcome following radiofrequency ablation of a malignant biliary stricture. *Turk J Gastroenterol* 2018; 29: 230-2.

ABSTRACT

We present a case of a 60-year-old woman with extrahepatic cholangiocarcinoma and recurrent malignant biliary strictures status post placement of two overlapping distal bile duct uncovered self-expandable metal stents (SEMSs) who presented with biliary obstruction due to tumor/tissue ingrowth. She subsequently underwent radiofrequency ablation (RFA) through SEMS to improve biliary stent patency. Post-RFA, thermal injury was observed in the periampullary mucosa. She later developed acute pancreatitis. This is the first case of RFA-induced acute pancreatitis with endoscopic evidence of thermal injury. It should be noted that RFA-induced acute pancreatitis is a potential adverse effect as RFA through SEMS is being used more widely.

Keywords: Acute pancreatitis, radiofrequency ablation, thermal injury, self-expandable metal stent, endoscopy

INTRODUCTION

In cases of malignant biliary obstruction with stent placement, radiofrequency ablation (RFA) causes coagulative necrosis of tumor tissue to prevent tumor ingrowth and epithelial hyperplasia; this leads to improved biliary stent patency (1,2). A literature review of RFA through self-expandable metal stents (SEMSs) for biliary tissue/tumor ingrowth revealed no reported cases of endoscopic evidence of thermal burn injury causing acute pancreatitis (2,3).

CASE PRESENTATION

A 60-year-old woman with extrahepatic cholangiocarcinoma and recurrent malignant biliary strictures status post placement of two overlapping distal bile duct uncovered SEMSs presented with pruritis, emesis, abdominal pain, and subjective fever for 1 week. She was febrile; physical examination revealed jaundice and right upper quadrant abdominal pain. Laboratory findings revealed a total bilirubin level of 4.2 mg/dL and an alkaline phosphatase level of 920 U/L. Broad-spectrum antibiotics were promptly initiated. During endoscopic retrograde cholangiopancreatography (ERCP), there was evidence of biliary obstruction due to tumor/tissue ingrowth through prior SEMS and resultant stenosis in the

common bile duct (Figure 1,2). Tumor/tissue destruction was performed with RFA using the Habib™ EndoHPB Probe (EMcision, Montreal, Canada). Intrabiliary RFA was performed to the stenosis from the proximal to the distal margin (ERBE generator, bipolar soft coag 10 watts) for 90's. Two sequential applications were applied to the whole length of the stricture. The lumen of SEMS was swept by a balloon catheter to remove tissue debris. Immediately following RFA, the mucosa surrounding the periampullary region was noted to be pale (Figure 3). The following morning, her upper abdominal pain worsened and she experienced nausea. Laboratory results revealed an elevated lipase level of 923 U/L, with improved liver function tests. Her mild acute pancreatitis was conservatively managed, and she was discharged on post-ERCP day 4. Informed consent was received to discuss this case further.

DISCUSSION

In this patient, acute pancreatitis was most likely caused by the thermal burn injury from RFA. The most common cause in this setting is post-ERCP pancreatitis; however, with a history of prior biliary intervention and the presence of prior placed uncovered SEMSs, this seemed unlikely. The clinical and laboratory evidence and peri-

ORCID IDs of the authors: A.K.K. 0000-0001-6831-8021; S.G.K. 0000-0001-5748-7890.

Address for Correspondence: Somashekar G. Krishna E-mail: somashekar.krishna@osumc.edu

Received: October 10, 2017 Accepted: October 16, 2017

© Copyright 2018 by The Turkish Society of Gastroenterology · Available online at www.turkjgastroenterol.org

DOI: 10.5152/tjg.2018.17653

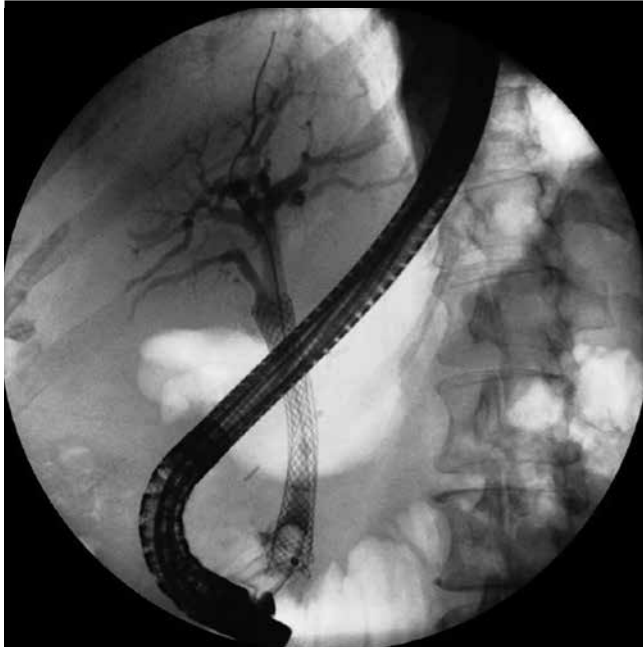

Figure 1. Cholangiogram showing stenosis

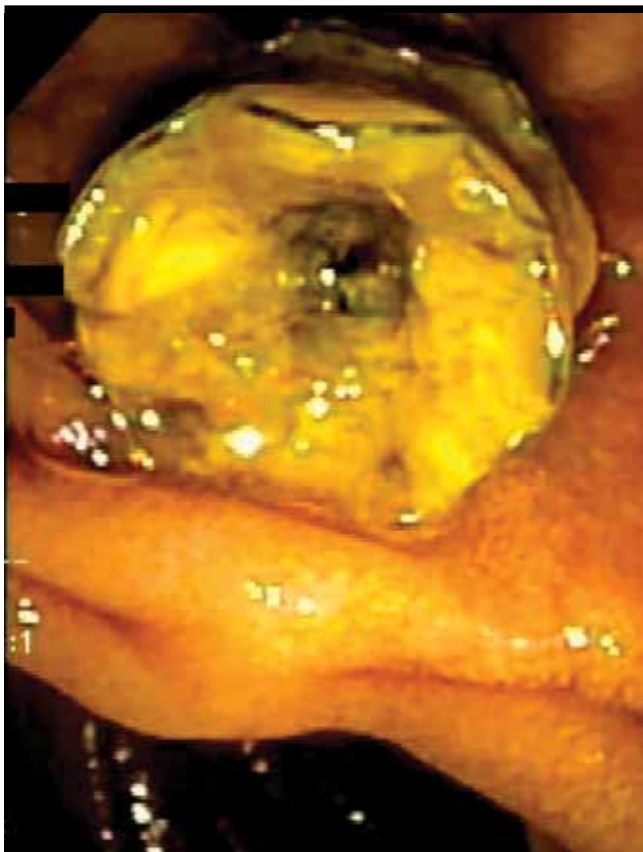

Figure 2. An endoscopic image of biliary obstruction

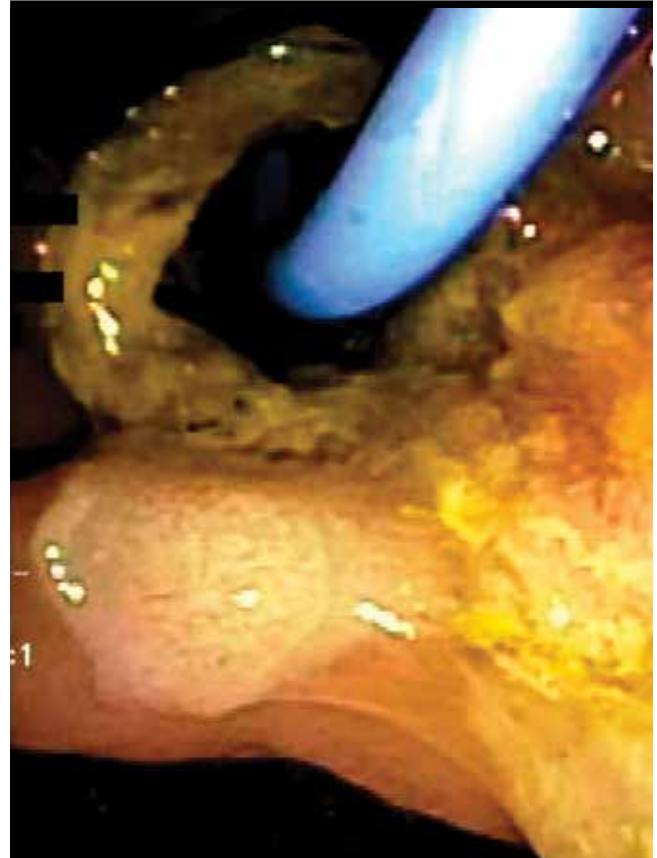

Figure 3. An endoscopic image noting mucosal changes after radiofrequency ablation

ampullary mucosal blanching provided the necessary substantiation for thermal injury-induced acute pancreatitis. Thermal injury from electrocautery is a known risk factor for acute pancreatitis; however, RFA-induced pancreatitis has not been well described and is another cause for acute pancreatitis (4). As per our knowledge and literature review, this is the first report of RFA-induced acute pancreatitis with endoscopic evidence of mucosal blanching. In a single center study assessing the safety of RFA in malignant biliary strictures, one patient developed mild pancreatitis, but without endoscopic findings of thermal burn injury (1). In another study, one patient had an elevated amylase level post-procedure, but was asymptomatic (3). However, these studies did not evidence the ampullary and periampullary mucosal changes observed in our patient. As RFA through SEMS is being used more widely, thermal burn injury-induced acute pancreatitis represents a potential adverse event, and gastroenterologists should be aware of this possible complication.

Informed Consent: Written informed consent was obtained from patient who participated in this study.

Peer-review: Externally peer-reviewed.

Author Contributions: Concept - A.J.K., S.G.K.; Design - A.J.K., S.G.K.; Supervision - A.J.K., S.G.K.; Analysis and/or Interpretation - A.J.K., S.G.K.; Literature Search - A.J.K., S.G.K.; Writing - A.J.K., S.G.K.; Critical Reviews - A.J.K., S.G.K.

Conflict of Interest: No conflict of interest was declared by the authors.

Financial Disclosure: The authors declared that this study has received no financial support.

REFERENCES

1. Figueroa-Barojas P, Bakhru MR, Habib NA, et al. Safety and efficacy of radiofrequency ablation in the management of unresectable bile duct and pancreatic cancer: a novel palliation technique. *J Oncol* 2013; 2013: 910897.
2. Kadayifci A, Atar M, Forcione DG, et al. Radiofrequency ablation for the management of occluded biliary metal stents. *Endoscopy* 2016; 48: 1096-101.
3. Steel AW, Postgate AJ, Khorsandi S, et al. Endoscopically applied radiofrequency ablation appears to be safe in the treatment of malignant biliary obstruction. *Gastrointest Endosc* 2011; 73: 149-53.
4. Parekh PJ, Majithia R, Sikka SK, et al. The "Scope" of Post-ERCP Pancreatitis. *Mayo Clin Proc* 2017; 92: 434-48.