

# Patulous upper esophageal sphincter - an unusual endoscopic finding

Allwin James , Premkumar Karunakaran , Ratnakar Kini , Pugazhendhi Thangavel 

Institute of Medical Gastroenterology, Madras Medical College and Rajiv Gandhi Government General Hospital, Chennai, India

**Cite this article as:** James A, Karunakaran P, Kini R, Thangavel P. Patulous upper esophageal sphincter - an unusual endoscopic finding. *Turk J Gastroenterol* 2018; 29: 114-6.

## ABSTRACT

The upper esophageal sphincter (UES) has various important functions, such as protection of the airway from aspiration and conduct of bolus into esophagus, which are controlled by complex neuronal mechanisms. The functions will be affected when there is malfunction of the UES due to various etiologies. Here we present an 80-year-old male with non-progressive dysphagia and patulous UES incidentally found on esophagoduodenoscopy. There are no documented cases of idiopathic patulous UES in literature. Endoscopists must be aware of this rare condition while evaluating a patient presenting with oropharyngeal dysphagia.

**Keywords:** Dysphagia, oropharyngeal dysphagia, patulous upper esophageal sphincter

## INTRODUCTION

The upper esophageal sphincter (UES) located at the pharyngoesophageal junction functions as a protective barrier between the trachea and esophagus. Varied pathologies, such as structural, rheumatologic, infectious, neurological, or iatrogenic, can affect the functions of the UES (1). Here, we report a case of idiopathic patulous UES, which was detected incidentally on endoscopy.

## CASE REPORT

An 80-year-old male presented with dysphagia and blocking sensation in the throat for one year. Dysphagia was equal to both solids and liquids from its onset and was non-progressive. On presentation, he was able to swallow solids and liquids but with difficulty. He had no history of nasal regurgitation; however, he had regurgitation at recumbent position, associated with heartburn and nocturnal symptoms. There was no history of hoarseness or change in voice. He had loss of appetite and subsequent weight loss, which was not quantifiable. There was no history of any neck or laryngeal surgeries or radiation exposure. He is a known case of coronary artery disease and dilated cardiomyopathy on angiotensin receptor blockers and anti-platelet agents. He was a smoker (1 pack of cigarettes per day for the past

30 years and has refrained from it since the last two years) and not an alcoholic. Systemic examination was unremarkable. There was no evidence of any neurological deficits. Otorhinolaryngological evaluation showed normal study of the vocal cords. His blood parameters revealed hypothyroid state. His thyroid stimulating hormone level was 19.4 IU/mL (normal range: 0.5-5.0 IU/mL). Other routine investigations were normal. Contrast-enhanced computed tomography of the neck and barium swallow were normal. Magnetic resonance imaging of the brain, performed to rule out neurological etiologies, was normal. Esophagogastroduodenoscopy showed that as hypopharynx was entered, the UES was patulous. Air inflation was not attempted to confirm the patulosity of UES. Esophagus was intubated without any difficulty. After entering into the UES, esophagus had normal peristalsis as seen on endoscopy. (Figures 1 and 2) The lower esophageal sphincter was lax as seen from the stomach. A video fluoroscopy or esophageal manometry could not be performed, as the patient did not consent for it. He was managed with conservative measures, such as feeding in a propped-up position, avoiding recumbent position immediately after a meal. Written informed consent was obtained from patient in his language for publication purposes.

ORCID ID of the authors: A.J. 0000-0002-3451-7505; P.K.K. 0000-0002-7711-9478; R.K. 0000-0002-0421-5960; P.T. 0000-0002-9491-6129

Address for Correspondence: Allwin James E-mail: [gastroallwin@gmail.com](mailto:gastroallwin@gmail.com)

Received: June 28, 2017 Accepted: September 11, 2017

© Copyright 2018 by The Turkish Society of Gastroenterology · Available online at [www.turkjgastroenterol.org](http://www.turkjgastroenterol.org)

DOI: 10.5152/tjg.2018.17189

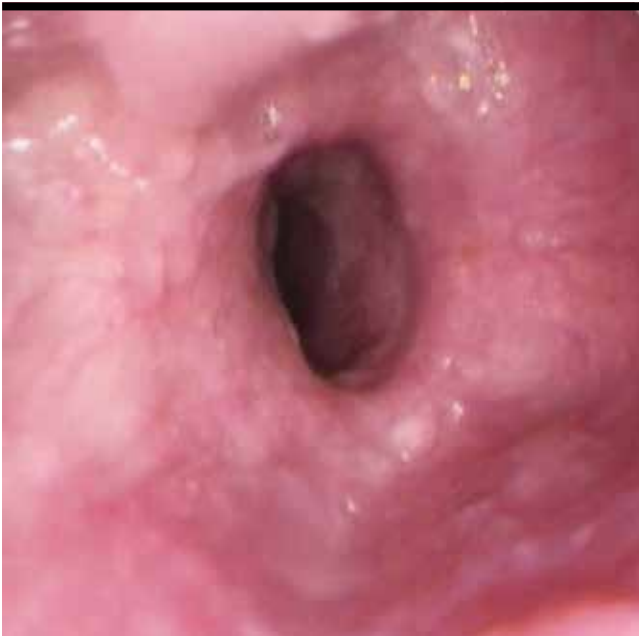

Figure 1. Endoscopic image showing patulous upper esophageal sphincter

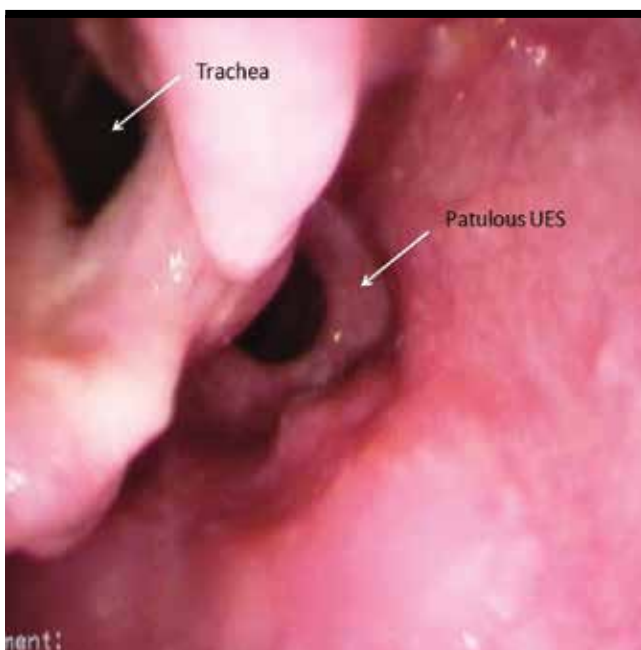


Figure 2. Endoscopic image showing patulous upper esophageal sphincter and trachea

## DISCUSSION

The UES measures 2-4 cm in its total length and is located at the pharyngoesophageal junction. It consists of two components - cartilage and striated muscle. The striated muscle component is formed by the fusion of

the proximal part of cervical esophagus and the inferior pharyngeal constrictor, which is formed by two parts cricopharyngeus and thyropharyngeus. Of these, the cricopharyngeus is attached to the posterior aspect of the cricoid cartilage and is more functionally significant during swallowing compared to other muscles (1,2). The UES is at a contracted state during rest, creating a high-pressure zone thus avoiding inhaled air from entering into esophagus, and it relaxes during swallowing and vomiting (3). It controls the antegrade or retrograde flow of food boli and secretions between esophagus and pharynx. Similarly, it also protects the airway from the entry of esophageal and gastric contents (4). UES is innervated by the pharyngeal plexus and the recurrent laryngeal nerve (5). The function of UES is mostly controlled by the vagus nerve through the recurrent laryngeal nerve. As the pharyngeal swallow response is initiated, the UES relaxes in a coordinated manner with the movement of the bolus. This relaxation is initiated by a transient inhibition of the cricopharyngeus, allowing the movement of the bolus from the hypopharynx into the esophagus. The following sequences of events are seen before the UES opens: upward movement of the larynx, forward movement of the hyoid, relaxation of cricopharyngeus, and anterior movement of larynx (6,7). Following these sequence of events, the UES relaxes and opens for the bolus to be transferred into the esophagus. The UES is maintained in the relaxed state by a balance between the 2 forces - one being the intrabolus pressure, i.e., the radial force within the bolus and the other being elastic recoil of the cricopharyngeus muscle, which is relaxed. The mechanism of UES is divided into two phases: the first is the relaxation occurring before the onset of the pharyngeal contraction, so as to receive and transfer the bolus. In the second phase, the UES contracts and returns to resting state, pushing the bolus into upper esophagus which is followed by initiation of peristalsis shifting the bolus downwards (8,9). This complex mechanism of pharyngeal phase of deglutition is controlled by the interneuronal circuit of the medullary swallow center. The transport of bolus into the esophagus depends to a greater extent on the coordination between cricopharyngeal muscles, UES, and upper esophagus (10,11).

There are multiple disorders affecting the anatomy and function of the UES. They may be classified as structural disorders, such as cricopharyngeal web and Zenker's diverticulum; head and neck malignancies; neurological disorders, such as ischemic stroke, neurodegenerative

disease, and bulbar neuropathy; infections, such as candidiasis and herpetic mucositis; rheumatologic disorders, such as polymyositis, sarcoidosis, and Sjogren's syndrome; or iatrogenically following locoregional radiation or surgery (1). Of the above-listed causes, neurodegenerative causes and locoregional radiation or surgery may lead to patulous UES. A review of literature revealed patulous UES in a patient with amyotrophic lateral sclerosis, who presented with cricopharyngeal achalasia and was treated by cricopharyngotomy using transnasal endoscopy (12). We have not been able to find any other documented case of patulous UES in literature.

Our patient presented with non-progressive dysphagia with nocturnal reflux symptoms and no history of any neck radiation or surgery. His systemic examination and otorhinolaryngological evaluation were essentially normal. Contrast computed tomography of the neck, magnetic resonance imaging of brain, and barium swallow were normal. Esophagogastroduodenoscopy performed for the evaluation of dysphagia showed patulous UES (Figures 1 and 2) with normal esophageal mucosa. As lax UES is a very unusual finding, we report the present case. A literature review, as mentioned earlier, showed only one case of patulous UES published as a part of study in a patient of amyotrophic lateral sclerosis following postcricopharyngotomy (12). Our patient had no neck surgery and had idiopathic patulous UES. Hence, endoscopists should be aware of such a rare condition while evaluating a patient with oropharyngeal dysphagia.

To conclude, we report a case of patulous UES with oropharyngeal dysphagia as the presenting symptom. Patulous UES is a very rare finding, and our case is the first to be reported. Hence, this cause must be considered while performing endoscopy in a patient with oropharyngeal dysphagia.

**Informed Consent:** Written informed consent was obtained from patients who participated in this study.

**Peer-review:** Externally peer-reviewed.

**Author contributions:** Concept - A.J., R.K.; Design - A.J., P.K.; Supervision - R.K., P.K.; Resource - A.J.; Materials - A.J.; Data Collection and/or Processing - A.J.; Analysis and/or Interpretation - P.K.; Literature Search - A.J., R.K.; Writing - A.J., R.K.; Critical Reviews - R.K., P.T.

**Conflict of Interest:** No conflict of interest was declared by the authors.

**Financial Disclosure:** The authors declared that this study has received no financial support.

## REFERENCES

- Ahuja NK, Chan WW. Assessing upper esophageal sphincter function in clinical practice: a primer. *Curr Gastroenterol Rep* 2016; 18: 1-7.
- Kahrilas PJ, Dodds WJ, Dent J, Logemann JA, Shaker R. Upper esophageal sphincter function during deglutition. *Gastroenterology* 1988; 95: 52-62.
- Skandalakis JE, Ellis H. Embryologic and Anatomic basis of Esophageal surgery. *Surg Clin North Am* 2000; 80: 85-155.
- Cook IJ. Cricopharyngeal function and dysfunction. *Dysphagia* 1993; 8: 244-51.
- Sprague JM: The innervation of the pharynx in the rhesus monkey and the formation of the pharyngeal plexus in primates. *Anat Rec* 1944; 90: 197-208.
- Lang IM, Dantas RO, Cook IJ, Dodds WJ. Videoradiographic, manometric, and electromyographic analysis of canine upper esophageal sphincter. *Am J Physiol* 1991; 260: G911-9.
- Cook IJ, Dodds WJ, Dantas RO, et al. Opening mechanisms of the human upper esophageal sphincter. *Am J Physiol* 1989; 257: G748-59.
- Migliore M. A dissection of a manometric trace of the upper esophageal sphincter and the crico-esophageal coordination. *Ann Ital Chir* 2013; 84: 133-6.
- Migliore M. Interpretation of a manometric trace of the upper esophageal sphincter. *J Neurogastroenterol Motil* 2013; 19: 415-6.
- Asoh R, Goyal RK. Manometry and electromyography of the upper esophageal sphincter in the opossum. *Gastroenterology* 1978; 74: 514-20.
- Jacob P, Kahrilas PJ, Logemann JA, Shah V, Ha T. Upper esophageal sphincter opening and modulation during swallowing. *Gastroenterology* 1989; 97: 1469-78.
- Aviv JE, Takouides TG, Ma G, Close LG. Office-based esophagoscopy: A preliminary report. *Otolaryngol Head Neck Surg* 2001; 125: 170-5.