

# Acute pancreatitis after coronary artery bypass surgery treated by plasmapheresis

Emine Şeyma Denli Yalvaç<sup>1</sup>, Mustafa Aldağ<sup>1</sup> , Cemal Kocaaslan<sup>1</sup> , Ebubekir Şenates<sup>2</sup> , Ebuzer Aydın<sup>1</sup> 

<sup>1</sup>Department of Cardiovascular Surgery, İstanbul Medeniyet University Göztepe Training and Research Hospital, İstanbul, Turkey

<sup>2</sup>Department of Gastroenterology, İstanbul Medeniyet University Göztepe Training and Research Hospital, İstanbul, Turkey

**Cite this article as:** Denli Yalvaç EŞ, Aldağ M, Kocaaslan C, Şenates E, Aydın E. Acute pancreatitis after coronary artery bypass surgery treated by plasmapheresis. *Turk J Gastroenterol* 2018; 29: 103-5.

## ABSTRACT

Acute pancreatitis (AP) is a common disorder and an important cause of morbidity and mortality. There are different causes of AP, including gallstones and excessive alcohol consumption. AP after coronary artery bypass grafting (CABG) surgery is seen less frequently but it is associated with a high mortality rate due to its atypical and misleading symptoms. Supportive treatment, pain management, and treatment of complications are used in the treatment of AP. The treatment of hypertriglyceridemia-induced pancreatitis is plasmapheresis, which is an extracorporeal separation of blood components to assist in the removal of inflammatory mediators. Here we present the case of a 60-year-old male patient who developed severe AP (Ranson Score: 6) without hypertriglyceridemia after CABG. The patient received supportive treatment, but the response to conventional therapy was not predictable. Thus, plasmapheresis was started, and the patient was treated with plasmapheresis successfully. The use of plasmapheresis in patients with this condition is a new treatment modality as far as we know. This case illustrates the efficient and safe use of the plasmapheresis treatment modality in a patient with AP without hypertriglyceridemia.

**Keywords:** Acute pancreatitis, cardiopulmonary bypass, plasmapheresis, coronary artery bypass grafting

## INTRODUCTION

Acute pancreatitis (AP) is closely related to gallstones and alcohol consumption, although the definite cause is not always known (1). The clinical spectrum of AP varies from edematous pancreatitis to severe necrotizing pancreatitis. For this reason, the prognosis of the disease is highly variable from complete recovery to mortality. Diagnosis is made mainly on clinical examination, elevated serum levels of pancreatic enzymes, and radiological imaging (2). The diagnosis of AP after coronary artery bypass grafting (CABG) surgery might be difficult due to its atypical and misleading symptoms. For example, hyperamylasemia does not seem to be a reliable indicator. The overall incidence of hyperamylasemia was reported to be 32% to 70% among patients undergoing open heart surgery (3). However, the incidence of clinically significant AP is 0.1% to 5.2 % in this cohort (4). After CABG surgery, AP with high mortality develops more easily in patients who have advanced age, low cardiac output, peripheral arterial disease, chronic obstructive pulmonary disease, diabetes mellitus, obesity, or chronic renal failure (5). Perioperative risk factors for AP include

emergency surgery, combined surgical interventions, vasopressor use, prolonged cross clamp and pump duration, prolonged ventilatory support, and sternal infections (5). The treatment of AP includes supportive treatment, pain management, and treatment of complications. Plasmapheresis is an extracorporeal separation of blood components that removes circulating inflammatory mediators (6). Plasmapheresis, as a treatment modality in AP, is most frequently used in the treatment of AP secondary hypertriglyceridemia, which is the third most common cause of AP. However, the use of plasmapheresis in cases with AP without hypertriglyceridemia has not been reported. This paper reports the case of a patient who suffered from severe AP (Ranson's criteria score: 6) without hypertriglyceridemia who underwent CABG and was successfully treated by plasmapheresis.

## CASE PRESENTATION

A 60-year-old man was admitted to our hospital with complaints of increased chest pain and shortness of breath. The patient had no known chronic disease oth-

ORCID IDs of the authors: M.A. 0000-0003-1363-4267; C.K. 0000-0002-1348-2411; E.Ş. 0000-0002-5804-7552; E.A. 0000-0002-9710-4716

Address for Correspondence: Mustafa Aldağ E-mail: [mustafa.aldag@yahoo.com](mailto:mustafa.aldag@yahoo.com)

Received: July 21, 2017 Accepted: August 17, 2017 Available Online Date: October 30, 2017

© Copyright 2018 by The Turkish Society of Gastroenterology · Available online at [www.turkjgastroenterol.org](http://www.turkjgastroenterol.org)

DOI: 10.5152/tjg.2017.17427

er than hypertension and benign prostatic hyperplasia. Due to a diagnosis of non-ST segment elevated myocardial infarction, coronary angiography was performed. During coronary angiography, ventricular fibrillation developed in the patient who was diagnosed with critical three coronary artery disease. After sinus rhythm was achieved by cardioversion, he was taken into the operating room. He underwent CABG surgery via cardiopulmonary bypass (CPB). Myocardial protection was achieved using antegrade cold blood cardioplegia. CPB time was 62 minutes and aortic cross clamp time was 38 minutes, and the patient required no inotropic support. The patient was extubated 12 hours later without postoperative neurological deficit. Total drainage was 800 mL, and no blood transfusion was needed.

The vital signs of the patient were stable until postoperative day 4, at which time respiratory distress occurred in the patient. Control echocardiography showed minimally pleural effusion and no pericardial effusion, and the ejection fraction was reported as 60%. Epigastric abdominal pain, nausea, bloating, and distension developed on postoperative day 8 during the course of treatment. His laboratory results were white blood cells:  $26,000 \times 10^3/\text{mm}^3$ ; lactate dehydrogenase: 434 mmol/L; amylase: 494 IU/L; lipase: 486 IU/L; triglyceride: 226 mg/dL; and c-reactive protein: 9.8 mg/dl. A contrast-enhanced CT showed acute inflammation of the pancreas and peripancreatic fat, but no necrosis or free fluid (Figure 1). Due to these findings, the patient was diagnosed with AP. In this patient, the AP was severe and the calculated Ranson's Criteria Score was 6 (white blood cells  $>16,000$ , Age  $>55$ , Glucose  $>200$  mg/dL, LDH  $>350$ , Ca  $<8$  mg/dL, arterial  $\text{pO}_2$   $<60$  mmHg within 48 hours), and the predicted mortality was 40%. The patient received conservative management with hydration. Arterial blood gas analysis worsened over the next day due to hypoxemia (arterial  $\text{pO}_2$  was  $<60$  mmHg) and he was intubated. The telecardiogram imaging of the patient on postoperative day 9 showed bilateral opacities and minimal pleural effusion (Figure 2). Following 3 days' intubation, plasmapheresis (Prismaflex, Baxter International Inc, USA) was performed in order to reduce the levels of circulating inflammatory mediators. Serum biochemistry enzyme levels were decreased to the following levels: amylase: 149 IU/L, lipase: 169 IU/L, triglyceride: 166 mg/dL, lactate dehydrogenase: 206 IU/L, c-reactive protein: 3 mg/dL. Clinical improvement was obtained with sup-

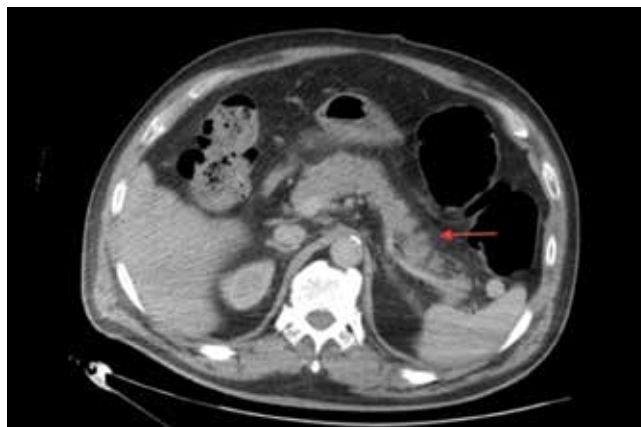


Figure 1. Acute inflammation of the pancreas and peripancreatic fat without necrosis or free fluid

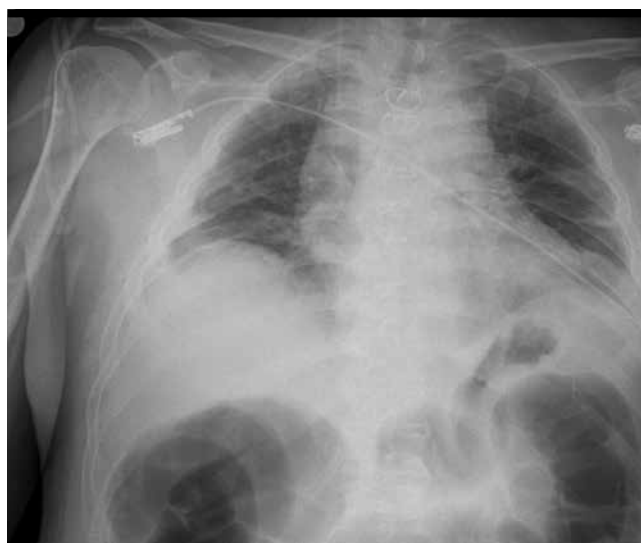

Figure 2. The telecardiogram imaging of the patient at postoperative day 9 showed bilateral opacities and minimal pleural effusion

port and plasmapheresis, and he was discharged after healing from surgery on postoperative day 23. Written informed consent was obtained from the patient for publishing this case.

#### DISCUSSION

Patients undergoing CABG surgery should be questioned in terms of risk factors because the incidence of AP is increasing and it has high morbidity and mortality. Gastrointestinal complications, including AP, have been suggested to be due to different causes during CABG surgery. Splanchnic ischemia due to visceral hypoperfusion might be caused by prolonged surgery, low cardiac output, increased acidosis, and vasoconstriction following high-dose inotropic use (5). We

think that ventricular fibrillation developed during coronary angiography and that urgent surgery and postoperative respiratory distress were the potential predisposing factors for developing AP in this patient.

The accurate diagnosis of AP is crucial due to its high morbidity and mortality. In a retrospective analysis of studies reported by Perez et al. (7), AP secondary to CABG surgery leads to longer postoperative length of stay and greater in-hospital mortality than patients who do not develop pancreatitis. Also, AP has been shown to have high mortality after cardiac valve replacement surgery (8). Hyperamylasemia is not always specific for AP, so the discrimination between postoperative acute pancreatitis and hyperamylasemia is important in CABG surgery patients. The mechanism of hyperamylasemia is not easily determined, but renal clearance is considered to be reduced by the use of a cardiopulmonary pump (9).

The treatment of AP is mainly supportive, including intravenous fluid resuscitation, especially in the early period (10). If the patient's case is mild, supportive therapy is often sufficient. However, which patients have edematous or necrotizing pancreatitis is not known at the beginning of the process.

Plasmapheresis is usually used in the treatment of AP secondary to hypertriglyceridemia along with insulin and low molecular weight heparin (11). To our knowledge, this is the first case of AP developing in a patient who underwent CABG surgery and which was successfully treated with plasmapheresis.

The main effect of plasmapheresis is hypothesized to be the rapid decrease in levels of hypertriglyceridemia; however, an additional benefit might be the removal of excessive proteases from the plasma, which are key enzymes in inflammation, and the replacement of consumed protease inhibitors (6).

In conclusion, AP after CABG is an unusual clinical complication of surgery, and thus diagnosis might be difficult. When a patient with AP after CABG surgery cannot be successfully treated with supportive measures, treatment of AP with plasmapheresis might be an effective

and safe treatment modality.

**Informed Consent:** Written informed consent was obtained from the patient who participated in this study.

**Peer-review:** Externally peer-reviewed.

**Author contributions:** Concept - E.S.D.Y., M.A., C.K.; Design - C.K., E.S., E.A.; Supervision - E.A., E.S.D.Y., M.A.; Resource - M.A., C.K., E.S.; Materials - E.S.D.Y., E.S., E.A.; Data Collection and/or Processing - E.S.D.Y., M.A., C.K.; Analysis and/or Interpretation - E.A., E.S., C.K.; Literature Search - C.K., E.S., E.A.; Writing - E.S.D.Y., M.A., C.K.; Critical Reviews - C.K., E.S., E.A.

**Conflict of Interest:** No conflict of interest was declared by the authors.

**Financial Disclosure:** The authors declared that this study has received no financial support.

## REFERENCES

1. Yadav D, Lowenfels AB. The epidemiology of pancreatitis and pancreatic cancer. *Gastroenterology* 2013; 144: 1252-61.
2. Banks PA, Bollen TL, Dervenis C, et al. Classification of acute pancreatitis 2012: Revision of the Atlanta classification and definitions by international consensus. *Gut* 2013; 62: 102-11.
3. Wan S, Ahmed AA, Chan CS, et al. Is Hyperamylasemia After Cardiac Surgery Due to Cardiopulmonary Bypass. *Asian Cardiovasc Thorac Ann* 2002; 10: 115-8.
4. Fernandez-del Castillo C, Harringer W, Warshaw AL, et al. Risk factors for pancreatic cellular injury after cardiopulmonary bypass. *N Engl J Med* 1991; 325: 382-7.
5. Akpınar B, Sağbaşı E, Guden M, et al. Acute gastrointestinal complications after open heart surgery. *Asian Cardiovasc Thorac Ann* 2000; 8: 109-13.
6. Gubensek J, Buturovic-Ponikvar J, Romozi K, Ponikvar R. Factors affecting outcome in acute hypertriglyceridemic pancreatitis treated with plasma exchange: An observational cohort study. *PLoS One* 2014; 9: e102748.
7. Perez A, Ito H, Farvar RS, et al. Risk factors and outcomes of pancreatitis after open heart surgery. *Am J Surg* 2005; 190: 401-5.
8. Chung JW, Ryu SH, Jo JH, et al. Clinical implications and risk factors of acute pancreatitis after cardiac valve surgery. *Yonsei Med J* 2013; 54: 154-9.
9. Urzua J, Troncoso S, Bugedo G, et al. Renal function and cardiopulmonary bypass: Effect of perfusion pressure. *J Cardiothorac Vas Anesth* 1992; 6: 299-303.
10. Tenner S, Baillie J, DeWitt J, Vege SS. American College of Gastroenterology Guideline: Management of Acute Pancreatitis. *Am J Gastroenterol* 2013; 108: 1400-15.
11. Tsuang W, Navaneethan U, Ruiz L, Palascak JB, Gelrud A. Hypertriglyceridemic pancreatitis: Presentation and management. *Am J Gastroenterol* 2009; 104: 984-91.