



An unusual cause of dysphagia after gastric variceal bleeding

Ankur Jindal

Department of Hepatology, Institute of Liver Biliary Sciences, New Delhi, India

Cite this article as: Jindal A. An unusual cause of dysphagia after gastric variceal bleeding. Turk J Gastroenterol 2017; 28: 417-8.

Question:

A 54-year-old male diagnosed with alcoholic cirrhosis had multiple episodes of upper gastrointestinal bleeding. He had a previous episode of hepatic encephalopathy. Baseline hepatic venous pressure gradient was 10 mmHg, and model for end-stage liver disease (MELD) score was 18. Gastroscopy revealed small low-risk esophageal varices (Figure 1a) and an active spurt from gastroesophageal varices type 2 (GOV2), which were successfully managed with intravenous terlipressin and intravariceal N-butyl cyanoacrylate injection (Figure 1b). Contrast-enhanced computed tomography (CECT) of the abdomen revealed a large tortuous gastrorenal

shunt that formed multiple gastric varices at the cardia and fundus of the stomach (Figure 1c). Balloon-occluded retrograde transvenous obliteration (BRTO) of the gastrorenal shunt was performed, and follow-up abdomen CECT revealed lipiodol retention with thrombosis of the gastric varices (Figure 1d). After 2 months, he was again admitted owing to hematemesis, and gastroscopy revealed large esophageal varices and obturated GOV2 (Figure 1e). Hemostasis was achieved by esophageal band ligation (EBL) of the large esophageal varices. After 3 months, he was evaluated for progressive dysphagia and weight loss.

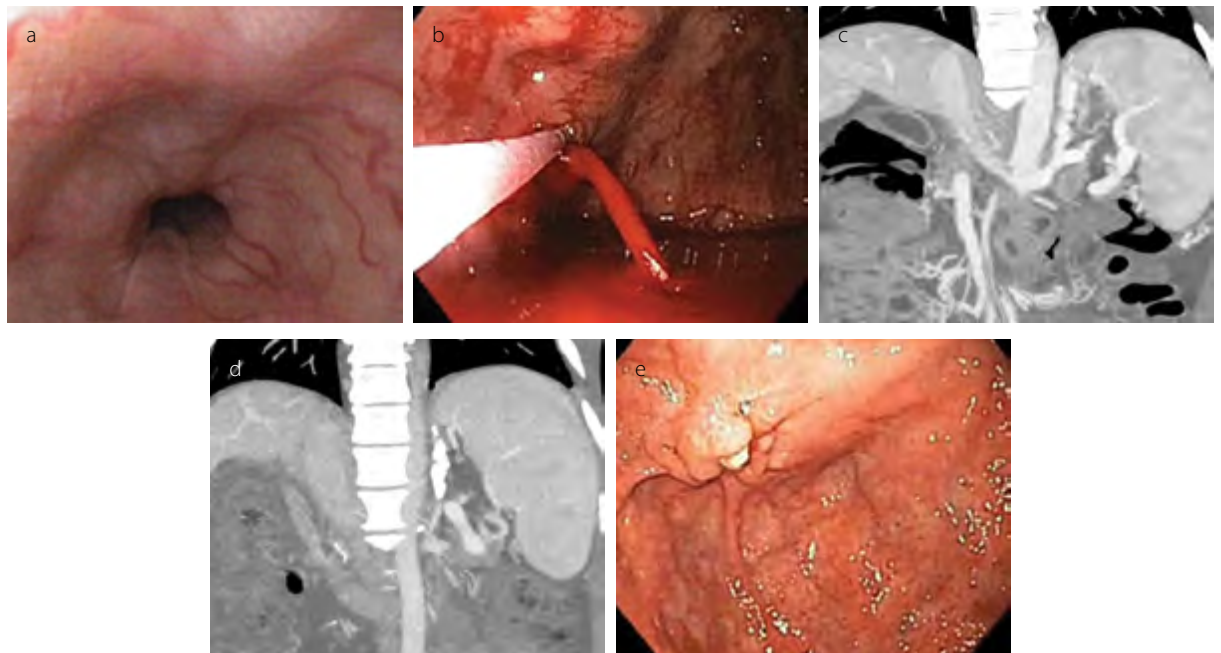


Figure 1. a-e. (a) Small low-risk esophageal varices, (b) acute gastroesophageal type 2 variceal bleeding, (c) large tortuous gastrorenal shunt that formed multiple gastric varices at the cardia and fundus of the stomach, (d) lipiodol retention with thrombosis of the gastric varices after balloon-occluded retrograde transvenous obliteration (BRTO) of the gastrorenal shunt, (e) small amount of retained glue cast at the 1-month follow-up

Address for Correspondence: Ankur Jindal E-mail: ankur.jindal3@gmail.com

Received: May 17, 2017

Accepted: May 28, 2017

Available Online Date: August 9, 2017

© Copyright 2017 by The Turkish Society of Gastroenterology • Available online at www.turkjgastroenterol.org • DOI: 10.5152/tjg.2017.17281

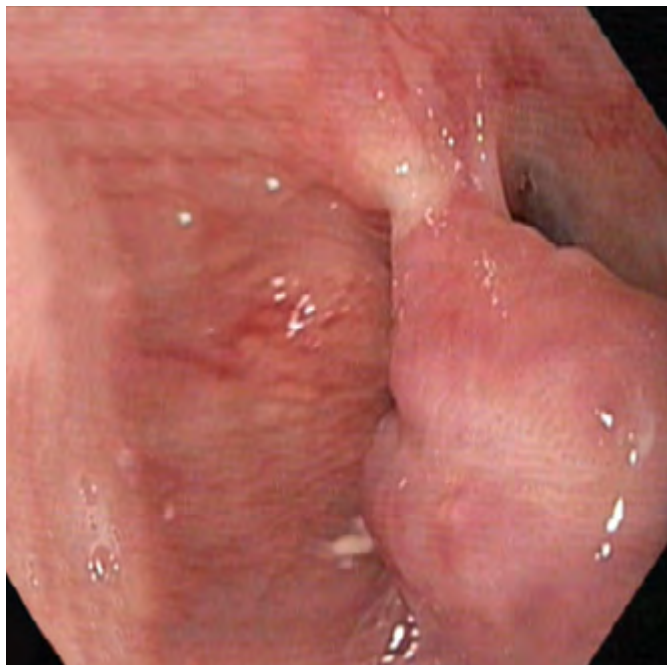

Figure 2. A large prolapsing lower esophageal varix with synechiae to the opposite esophageal wall

Answer:

Follow-up gastroscopy revealed a large prolapsing lower esophageal varix tethered to the opposite esophageal wall in synechiae. The esophageal lumen was compromised along both sides of the tethered varix (Figure 2).

Ulcer formation after EBL is nearly universal, although stricture formation is rare and typically present as late dysphagia, thereby allowing fibrosis progression and stricture formation. Complete obstruction of the esophagus is an exceedingly rare complication of EBL and is observed in individuals with cirrhosis with preexisting abnormalities in the esophageal mucosa, such as undetected strictures from previous therapies. The occurrence of transient dysphagia (persisting for 24-72 h) after EBL is more common because of engorged banded varices or altered lower esophageal sphincter relaxation after EBL (1).

In the present case, repeated episodes of GOV2-related bleed-

ing, despite intravariceal N-butyl cyanoacrylate injections, warrant further interventions such as transjugular intrahepatic portosystemic shunt (TIPS) or BRTO to prevent rebleeding. In the presence of a low portosystemic gradient, TIPS may not be completely effective in diverting the flow from a large gastorenal shunt. Moreover, patients with a poor hepatic reserve (MELD score, >15) and previous hepatic encephalopathy have poor outcomes after TIPS compared with after BRTO. Technical success, defined by complete obliteration of the varix, after BRTO is reportedly 73%-100%, with a low risk for rebleeding rates of <10% (2).

However, as in the present case, there is an increase in the size of the esophageal varices (between 7.3% and 27% after 1 year) and an increase in the risk for esophageal variceal bleeding after BRTO because of an increase in portal pressures (3). Careful and vigilant endoscopic follow-up and more aggressive endoscopic therapies are warranted to prevent the abovementioned complications.

Informed Consent: Written informed consent was obtained from the patient who participated in this study.

Peer-review: Externally peer-reviewed.

Conflict of Interest: No conflict of interest was declared by the author.

Financial Disclosure: The author declared that this study has received no financial support.

REFERENCES

- Schmitz RJ, Sharma P, Badr AS, Qamar MT, Weston AP. Incidence and management of esophageal stricture formation, ulcer bleeding, perforation, and massive hematoma formation from sclerotherapy versus band ligation. *Am J Gastroenterol.* 2001; 96: 437-41. [\[CrossRef\]](#)
- Saad WE, Simon PO, Rose SC. Balloon-occluded retrograde transvenous obliteration of gastric varices. *Cardiovasc Intervent Radiol* 2014; 37: 299-315. [\[CrossRef\]](#)
- Garcia-Pagan JC, Barrufet M, Cardenas A, Escorsell A. Management of gastric varices. *Clin Gastroenterol Hepatol* 2014; 12: 919-28. [\[CrossRef\]](#)