



Extraordinary biliary variant

Nuretdin Suna, Diğdem Özer Etik, Serkan Öcal, Haldun Selçuk, Fatih Hilmioğlu, Sedat Boyacıoğlu

Department of Gastroenterology, Başkent University School of Medicine, Ankara, Turkey

Question:

A 40-year-old healthy woman was evaluated as a donor candidate for living donor liver transplantation. Her medical history was unremarkable. She had completely normal physical examination and laboratory results. It was seen on endoscopic retrograde cholangiography

imaging (Figure 1a) and magnetic resonance cholangiopancreatography imaging (Figure 1b) that the right lobe posterior segment bile duct opened to the segment II bile duct and that the segment II bile duct merged with the common trunk of segment III and segment IV bile ducts, thus forming the left hepatic bile duct.

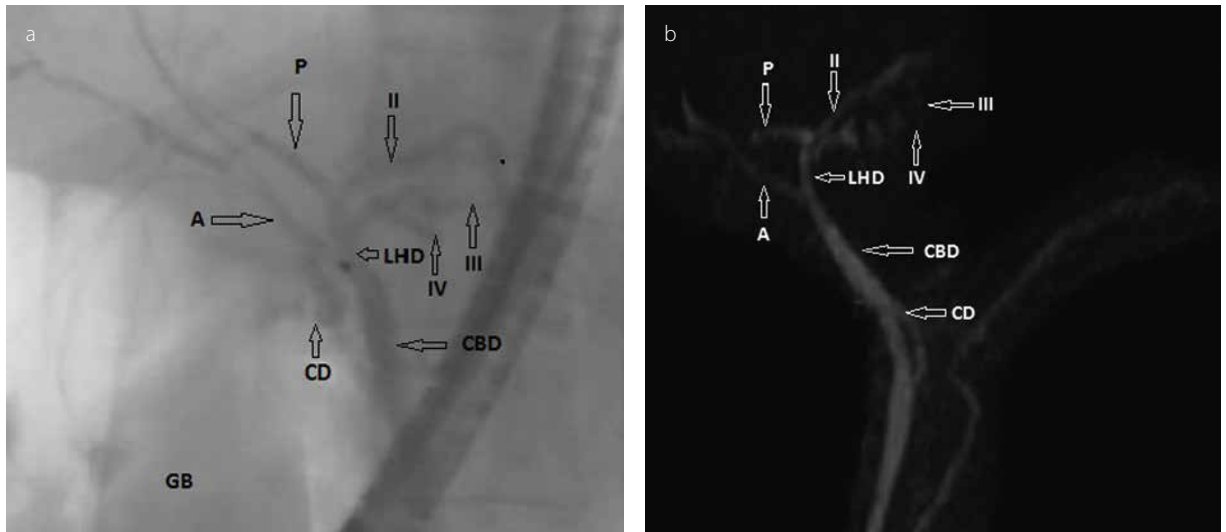


Figure 1. a. b. (a) Endoscopic retrograde cholangiography imaging; (b). magnetic resonance cholangiopancreatography imaging. The right lobe posterior segment bile duct opens to the segment II bile duct and then the segment II bile duct merges with the common trunk of the segment III and segment IV bile ducts, thus forming the left hepatic duct (2, segment 2 duct; 3, segment 3 duct; 4, segment 4 duct; LH: left hepatic duct; P: right posterior hepatic duct; A, right anterior hepatic duct; CBD: common bile duct)

Answer: Combined right and left bile duct variations

The variation of the right lobe posterior segment bile duct that drained to the left hepatic bile duct is described as type 3A according to the classification of Huang et al. (1). In this case, right lobe posterior segment bile duct drained to the segment II bile duct instead of the left hepatic bile duct. Moreover, the segment III and IV bile ducts form the common trunk and it constitutes the left hepatic bile duct by joining the segment II bile duct, which is defined as type 2 according to the classification of Cho et al. (2). However, in this case, the segment II bile duct was conveying right lobe posterior segment bile duct instead of being a single duct. The prevalence of type 3A variation of the right biliary duct according to the classification of Huang et al was reported as 14.5%–27.6% (3,4). In the meanwhile, the prevalence of the type 2 variation of the left biliary duct according to the classification of Cho et al. (2) was 23.2%–30%. However, no coexistence of these variations has been published (3).

The embryologic development of the human biliary tree is a complex process; this is the reason why numerous anatomical variations of intrahepatic and extrahepatic bile ducts have been recognized. These variations represent challenging points in the surgical approach as is the case with cholecystectomy, liver resection, or liver transplantation. Therefore, the anatomy of the biliary system should be accurately and precisely interpreted.

Consequently, this patient was considered improper as a liver donor because of the complex variation of the left and right bile ducts. We hereby emphasize that complex and non-classified anatomic variations of the biliary tract can accidentally emerge and be important for preventing serious complications before any hepatobiliary surgical plan.

Ethics Committee Approval: Ethics committee approval was received for this study from the ethics committee of Başkent University Faculty of Medicine Ethics Committee has been allowed / 162-4765.

Informed Consent: Written informed consent was obtained from patient who participated in this study.

Peer-review: Externally peer-reviewed.

Author Contributions: Concept – N.S.; Design – D.Ö.E., İ.S.; Supervision – S.B.; Resources – F.H.; Materials – H.S.; Data Collection and/or Processing – D.Ö.E.; Analysis and/or Interpretation – F.H.; Literature Search – S.Ö.; Writing Manuscript – N.S.; Critical Review – S.B., H.S.

Conflict of Interest: No conflict of interest was declared by the authors.

Financial Disclosure: The authors declared that this study has received no financial support.

REFERENCES

- Huang TL, Cheng YF, Chen CL, Lee TY. Variants of the bile ducts: clinical application in the potential donor of living related hepatic transplantation. *Transplant Proc* 1996; 28: 1669-70.
- Cho A, Okazumi S, Yoshinaga Y, Ishikawa Y, Ryu M, Ochiai T. Relationship between left biliary duct system and left portal vein: evaluation with three-dimensional portocholangiography. *Radiology* 2003; 228: 246-50. [\[CrossRef\]](#)
- Sarawagi R, Sundar S, Raghuvanshi S, Gupta SK, Jayaraman G. Common and Uncommon Anatomical Variants of Intrahepatic Bile Ducts in Magnetic Resonance Cholangiopancreatography and its Clinical Implication. *Pol J Radiol* 2016; 81: 250-5. [\[CrossRef\]](#)
- Chaib E, Kanas AF, Galvão FH, D'Albuquerque LA. Bile duct confluence: anatomic variations and its classification. *Surg Radiol Anat* 2014; 36: 105-9. [\[CrossRef\]](#)