

Dense eosinophilic infiltration of the mucosa preceding ulcerative colitis and mimicking eosinophilic colitis: Report of two cases

Ülseratif kolit öncesi eozinofilik koliti taklit eden yoğun mukozal eozinofil infiltrasyonu: İki olgu sunumu

Hülya UZUNİSMAİL¹, İbrahim HATEMİ¹, Gülen DOĞUSOY², Onat AKIN³

Departments of ¹Gastroenterology, ²Pathology Istanbul University Cerrahpaşa Medical Faculty, ³Patomed, İstanbul

There is increasing evidence about the involvement of eosinophils in the pathogenesis of inflammatory bowel disease. We report here two patients with ulcerative colitis who were initially diagnosed as eosinophilic colitis based on histopathological examination during their first attacks. They had symptomatic improvement with ketotifen and metronidazole during their first attacks. However, subsequent attacks which were histopathologically diagnosed as ulcerative colitis did not resolve with the above-mentioned treatment and necessitated a treatment with 5-ASA agents plus corticosteroids. Azathioprine also had to be added in the treatment of the second patient. Dense eosinophilic infiltration in these cases may suggest a role of eosinophils in the initiation of attacks in some ulcerative colitis patients.

Key words: Ulcerative colitis, eosinophils, eosinophilic colitis

Eozinofillerin inflamatuvar barsak hastalığı patogeneğinde yer aldıklarına dair kanıtlar artmaktadır. Bu yazıda ilk atakları sırasında histopatolojik olarak eozinofilik kolit tanısı alan iki ülseratif kolit vakası sunulmaktadır. Hastalar ilk atakları sırasında ketotifen ve metronidazol ile semptomatik düzelme göstermişlerdir. Bununla beraber sonraki ataklarda histopatolojik olarak ülseratif kolit tanısı konmuş ve yukarıda belirtilen tedaviden yarar görmemişlerdir. Sağaltımlarında 5-ASA ve kortikosteroid kullanımı gerekli olmuştur, ikinci vakada tedaviye azathioprin de eklenmesi zorunlu olmuştur. Bu vakalardaki yoğun eozinofil infiltrasyonu ülseratif kolit vakalarının bir kısmında atakların ortaya çıkmasında eozinofillerin rolü olabileceğini düşündürmektedir.

Anahtar kelimeler: Ülseratif kolit, eozinofil, eozinofilik kolit

INTRODUCTION

Eosinophils are present in healthy gut mucosa and their presence is considered to be protective against bacteria and more so against helminthic parasites. Eosinophils can cause tissue damage by releasing cytotoxic granule proteins. Activated eosinophils also produce cytokines, chemokines and lipid mediators which modulate immune response and amplify the immune cascade (1). Increased knowledge about the diverse function of eosinophils has provoked curiosity about their potential role in the physiopathology of different diseases, represented by an increased tissue eosinophil count.

The role of eosinophilic granules in the pathogenesis of gut inflammation is well known in eosinophilic gastroenteritis in which tissue injury was fo-

und to be correlated with degranulated eosinophil count, eosinophilic cationic protein (2) and major basic protein levels (3). Increased count and activation of eosinophils are also detected in celiac disease (3, 4) and collagenous colitis (5), as well as in the active phase of ulcerative colitis (UC) and Crohn's disease (CD) (6-9). Different methods such as electron microscopy (7), determination of eosinophil granule protein levels (8) and immunohistological examination of tissue samples (9) were utilized to show that tissue eosinophils in inflammatory bowel disease (IBD) are active rather than resting cells. Increased levels of eosinophil granule proteins were detected in perfusion fluids in UC (10) and in stool (11-13) and gut lavage fluids (14, 15) in both UC and CD. All these findings suggest that eosinophils contribute to tissue damage and

Address for correspondence: İbrahim HATEMİ
Orhan Ersek Sokak, No: 21/7 Ahenk Apt.
80200 Nişantaşı, İstanbul, Turkey
Phone: +90 212 414 30 00/21635/21608/22431
E-mail: ihatemi@yahoo.com

Manuscript received: 16.05.2005 **Accepted:** 27.10.2005

intestinal inflammation in IBD. Activated eosinophils play an important role in ongoing disease due to granule proteins, eosinophil derived cytokines and lipid mediators, but it is not known whether eosinophils initiate the attacks in these disorders.

We report here two cases presenting as eosinophilic colitis in their first attacks of colitis who were diagnosed as UC based on histological and clinical findings in later attacks.

CASE 1

An 18-year-old female patient was admitted with bloody diarrhea. Her medical history was unremarkable; her sister had UC. Stool culture was negative, no parasites or ova were detected by microscopic examination. Colonoscopy showed that rectum and sigmoid colon mucosa was hyperemic and edematous with increased exudation. In histopathological examination, dominant eosinophilic infiltration of lamina propria without crypt destruction suggested eosinophilic colitis. The mean eosinophil count was 34 per high-power field (Figure 1).

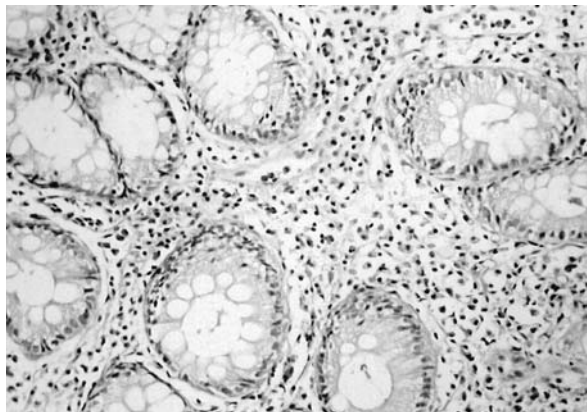


Figure 1. Eosinophilic infiltration of lamina propria suggesting eosinophilic colitis

Her complaints regressed with 2 mg of ketotifen and 500 mg metronidazole, b.i.d, and elimination diet. Two years later she was hospitalized again because of bloody diarrhea, weight loss and abdominal pain. Her erythrocyte sedimentation rate (ESR) was 40 mm/hour, C-reactive protein (CRP) 7 mg/L (normal range 0-5), hemoglobin 9 g/dl, hematocrit 26%, and WBC count 7300/ml with no eosinophils on peripheral smear. Her IgE level was

355.7 IU/ml (normal range 0-100) and serum albumin level 3.65 mg/dl. Stool culture was negative, no parasites were found, and toxin A and B assays for *Clostridium difficile* were negative. Endoscopy showed left-sided colitis with diffuse edema, hyperemia, fine granular appearance, fragility and increased exudation. In histopathological examination, fibropurulent exudation on surface epithelium, distortion and inflammation of crypts, and dense infiltration of lymphoplasmacytes and neutrophils on lamina propria were noted. Histological diagnosis was active phase of UC (Figure 2).

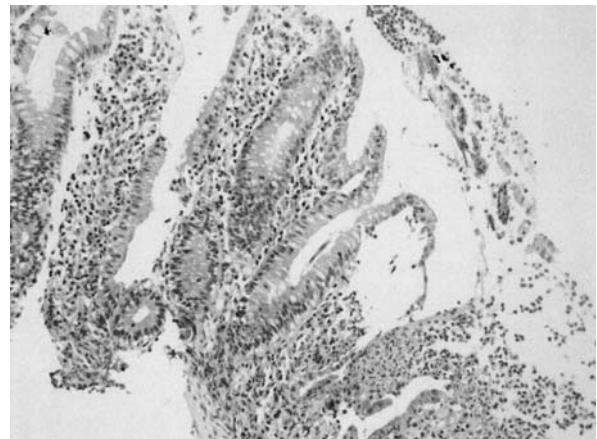


Figure 2. Histopathologic findings suggesting active phase UC: distortion and inflammation of crypts, and dense infiltration of lymphoplasmacytes and neutrophils on lamina propria

Clinical activity was moderate according to the Mitsuru Seo index (16). Because of the past diagnosis of eosinophilic colitis, the same therapy was started but her symptoms did not improve. Methylprednisolone 32 mg/day, sulfasalazine 3 g/day and mesalamine enemas were started. Symptomatic, clinical, and histological remission was achieved. For maintenance therapy, sulfasalazine 2 gr/day was recommended.

CASE 2

A 52-year-old female patient was admitted with bloody diarrhea and abdominal pain. The patient had been in good health until one week previously. Her daughter was being treated for severe UC (past five years). Her stool culture was negative, no parasites or ova were detected, and *Clostridium difficile* toxins A and B assays were negative. Eosinophil count was 420/mm³ with 7% of total le-

ucocytes. IgE level was 28.3 IU/L. ESR was 18 mm/hour. Colonoscopy showed left-sided colitis with hyperemia, edema and increased exudation. Histopathological examination showed focal distortion of crypts and dense eosinophilic infiltration of lamina propria, and the diagnosis was eosinophilic colitis. The mean eosinophil count was 30 per high-power field (Figure 3). Ketotifen (2 mg) and 500 mg of metronidazole, b.i.d., and elimination diet were started. Symptomatic relief was obtained but she refused colonoscopic control.

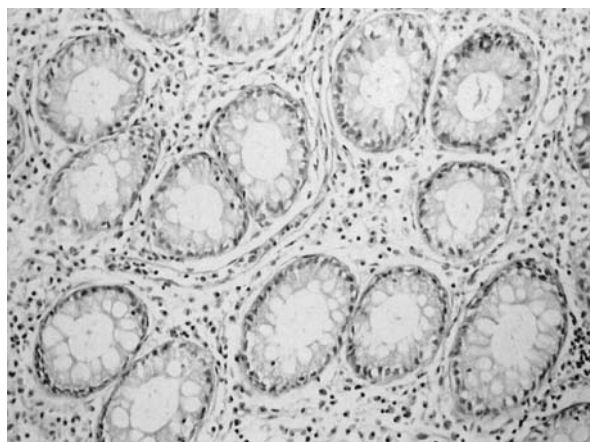


Figure 3. Eosinophilic colitis: focal distortion of crypts and dense eosinophilic infiltration of lamina propria

Six months later she had another attack of bloody diarrhea. Her stool examination showed no parasites or ova, there were no *Clostridium difficile* toxins, and stool culture was negative. Her eosinophil count was 630 with WBC 10500/ml. Her ESR was 27 mm/hour, hemoglobin level 12.4 g/dl, CRP 10 U/L, and albumin 4.1 g/dl. Colonoscopy showed hyperemia, edema, petechial hemorrhage areas and increased exudation beginning from rectum and continuing as far as the mid transverse colon. Ulcerations with a diameter of 1-2 mm were also detected in this region. Clinical activity was mild according to the Mitsuru Seo index. Histopathological diagnosis was active phase of UC. Ulceration on surface epithelium, decreased number of crypts and goblet cells, distortion of crypts, neutrophilic infiltration of lamina propria and crypts, and infiltration of lymphoplasmacytes on lamina propria were noted (Figure 4).

As symptomatic relief had been achieved with the first treatment when the diagnosis was eosinophi-

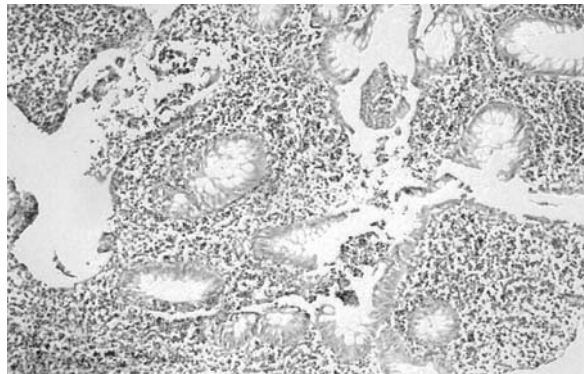


Figure 4. Ulcerative colitis: regeneration of surface epithelium, and decreased number of crypts and goblet cells

lic colitis, the same regimen was started, but no symptomatic improvement could be obtained. The patient's symptoms improved with methylprednisolone 36 mg/day, mesalamine tablets 3 g/day and mesalamine enemas, but the symptoms recurred after methylprednisolone was tapered 4 mg/per week to a dose of 28 mg/day. The patient was considered to be steroid-dependent after a second high-dose therapeutic attempt, in regular descending dose manner, demonstrated no positive result; hence, azathioprine was necessary to obtain remission.

DISCUSSION

The findings of our patients suggest that in some UC patients eosinophilic infiltration may precede UC. Eosinophil infiltration can be expected in UC. The classical knowledge of the cytokine pattern of UC is that it is a Th-2 disease with increased IL-5 release (17). Matsuzaki et al. (18) have shown that Th-2 responses mainly occur in colonic mucosa with mild inflammation, while Th1 responses significantly occur with severe inflammation in UC patients. IL-5 and eotaxin, which is an eosinophil-specific chemoattractant, play an important role in eosinophil recruitment (19). High levels of serum eotaxin are found during active disease in UC and CD (20), but Mir et al. (21) reported that high levels may be detected in both active and inactive disease.

We may have detected the inflammatory cell infiltration, which was mainly eosinophilic, in the early lesions of UC. This finding could suggest that eosinophilic infiltration is the initiating event for UC in some patients. We could not detect the exact duration between the onset of symptoms and

histopathological examination in our first patient, but it was eight days in the second patient. The histopathological findings of this patient may be an example of the very early stage of a first UC attack.

Generally, IBD is a disease of younger ages. The majority of patients with UC seek medical assistance from internists or local general practitioners for their first attacks with bloody diarrhea. Diagnostic tools such as stool examinations (e.g., parasites, culture) are requested and an empiric antibiotic treatment is usually prescribed even in case of negative results. In fact, endoscopic and histopathologic examinations in patients with bloody diarrhea are done afterwards. Thus, all initial steps have taken some time.

Seegert *et al.* (22) detected significantly increased IL-16 mRNA and IL-16 protein in the inflamed colonic mucosa of patients with IBD compared to controls. They also detected that most of IL-16 protein was predominantly expressed in eosinophils. IL-16 has strong chemoattractant activity on CD4+ T cells and stimulates the expression and production of pro-inflammatory cytokines by human monocytes (23). The study of Seegert (22) led us to consider whether eosinophils not only modulate, but also initiate, the inflammation in IBD.

There is no data about the early lesion of UC yet, but in early recurrence of CD, a higher expression of IL-5 mRNA was found in involved areas compared to endoscopically normal ones (24). In another study by Desreumaux *et al.* (25), eosinophil count per area was found to be increased in both chronic and early lesions and was significantly higher than in controls. However, according to the inflammation score, increase in the number of eosinophils was statistically significant in the early lesions. Although cytokine profile tends to be predo-

minantly Th-1 type with increased levels of IFN- α in CD (17, 26), Desreumaux *et al.* (25) showed that while chronic intestinal lesions of CD are compatible with a Th-1 type pattern, early lesions are associated with a Th-2 type pattern with significant increase of IL-4 mRNA and decrease of IFN- α mRNA. The authors suggested that there were divergent cytokine patterns during different clinical stages and noticed that the shift from type 2 to type 1 pattern was also detected in atopic dermatitis, as suggested by Thepen *et al.* (27). The relation of Th-2 cytokine pattern with colitis was also determined in animal models, such as the T cell receptor α chain-deficient mice model, in which the colitis develops spontaneously within three months of age (28), and the oxazolone colitis murine model, which is more characteristic of UC (29).

The Th-2 type cytokine pattern is seen in allergic disorders, and eosinophils are closely associated with Th-2 immune response (19, 30). Another finding of our patients was the positive family history of their first-degree relatives. Positive family history is an important finding not only in IBD but also in allergic disorders.

These two cases may be an example of a subgroup of UC patients with massive eosinophilic infiltration as Heatley *et al.* (31) has suggested. The authors have pointed out that the large numbers of eosinophils in rectal mucosa during active disease might predict a benign course in some patients who have responded to disodium chromoglycate. Recently, this theory was also supported by successful response to ketotifen therapy for UC in children who were observed to have high tissue eosinophilia (32).

These two cases may be an example of the event in which eosinophils can initiate the attacks of ulcerative colitis at least in a minority of patients.

REFERENCES

1. Wardlaw AJ, Barry Kay A. Eosinophils and their disorders. In: Beutler E, Lichtman MA, Coller BS, Kipps TJ, Seligson U, eds. *William's Haematology*. Sixth ed. New York: McGraw Hill, 2001; 785-99.
2. Keshavarzian A, Saverymuttu SH, Tai PC, *et al.* Activated eosinophils in familial eosinophilic gastroenteritis. *Gastroenterology* 1985; 88: 1041-9.
3. Talley NJ, Kephart GM, McGovern TW, *et al.* Deposition of eosinophil granule major basic protein in eosinophilic gastroenteritis and celiac disease. *Gastroenterology* 1992; 103: 137-45.
4. Colombel JF, Torprier G, Janin A, *et al.* Activated eosinophils in adult coeliac disease: evidence for a local release of major basic protein. *Gut* 1992; 33: 1190-4.
5. Levy AM, Yamazaki K, Van Keulen VP, *et al.* Increased eosinophil infiltration and degranulation in colonic tissue from patients with collagenous colitis. *Am J Gastroenterol* 2001; 96: 1522-8.
6. Bischoff SC, Wedemeyer J, Herrmann A, *et al.* Quantitative assessment of intestinal eosinophils and mast cells in inflammatory bowel disease. *Histopathology* 1996; 28: 1-13.

7. Dvorak AM. Ultrastructural evidence for release of major basic protein -containing crystalline cores of eosinophil granules in vivo: cytotoxic potential in Crohn's disease. *J Immunol* 1980; 125: 460-2.
8. Raab Y, Fredens K, Gerdin B, Hallgren R. Eosinophil activation in ulcerative colitis: studies on mucosal release and localization of eosinophil granule constituents. *Dig Dis Sci* 1998; 43: 1061-70.
9. Bischoff SC, Mayer J, Nguyen QT, Stolte M. Immunohistological assessment of intestinal eosinophil activation in patients with eosinophilic gastroenteritis and inflammatory bowel disease. *Am J Gastroenterol* 1999; 94: 3521-9.
10. Carlson M, Raab Y, Peterson C, et al. Increased intraluminal release of eosinophil granule proteins EPO, ECP, EPX, and cytokines in ulcerative colitis and proctitis in segmental perfusion. *Am J Gastroenterol* 1999; 94: 1876-83.
11. Berstad A, Borkje B, Riedel B, et al. Increased fecal eosinophil cationic protein in inflammatory bowel disease. *Hepato-gastroenterology* 1993; 40: 276-8.
12. Bischoff SC, Grabowsky J, Manns MP. Quantification of inflammatory mediators in stool samples of patients with inflammatory bowel disorders and controls. *Dig Dis Sci* 1997; 42: 394-403.
13. Saitoh O, Kojima K, Sugi K, et al. Fecal eosinophil granule derived proteins reflect disease activity in inflammatory bowel disease. *Am J Gastroenterol* 1999; 94: 3513-20.
14. Levy AM, Gleich GJ, Sandborn WJ, et al. Increased eosinophil granule proteins in gut lavage fluid from patients with inflammatory bowel disease. *Mayo Clin Proc* 1997; 72: 117-23.
15. Troncione R, Caputo N, Esposito V, et al. Increased concentrations of eosinophilic cationic protein in whole gut lavage fluid from children with inflammatory bowel disease. *J Pediatr Gastroenterol Nutr* 1999; 28: 164-8.
16. Seo M, Okada M, Tsuneyashi Y, et al. An index of disease activity in patients with ulcerative colitis. *Am J Gastroenterol* 1992; 87: 971-6.
17. Fuss IJ, Neurath M, Boirivant M, et al. Disparate CD4+ lamina propria (LP) lymphokine secretion profiles in inflammatory bowel disease. Crohn's disease LP cells manifest increased secretion of IFN-gamma, whereas ulcerative colitis LP cells manifest increased secretion of IL-5. *J Immunol* 1996; 157(3): 1261-70.
18. Matsuzaki K, Hokari R, Kato S, et al. Differential expression of CCR5 and CRTH2 on infiltrated cells in colonic mucosa of patients with ulcerative colitis. *J Gastroenterol Hepatol* 2003; 18: 1081-8.
19. Rankin SM, Conroy DM, Williams TJ. Eotaxin and eosinophil recruitment: implications for human disease. *Mol Med Today* 2000; 6: 20-7.
20. Chen W, Paulus B, Shu D, et al. Increased serum levels of eotaxin in patients with inflammatory bowel disease. *Scand J Gastroenterol* 2001; 36: 515-20.
21. Mir A, Minguez M, Tatay J, et al. Elevated serum eotaxin levels in patients with inflammatory bowel disease. *Am J Gastroenterol* 2002; 97: 1452-7.
22. Seeger D, Rosentiel P, Pfahler H, et al. Increased expression of IL-16 in inflammatory bowel disease. *Gut* 2001; 48: 326-32.
23. Mathy NL, Scheuer W, Lanzendorfer M, et al. Interleukin -16 stimulates the expression and production of proinflammatory cytokines by human monocytes. *Immunology* 2000; 100: 63-9.
24. Dubucquoi S, Janin A, Klein O, et al. Activated eosinophils and interleukin 5 expression in early recurrence of Crohn's disease. *Gut* 1995; 37: 242-6.
25. Desreumaux P, Brandt E, Gambiez L, et al. Distinct cytokine patterns in early and chronic ileal lesions of Crohn's disease. *Gastroenterology* 1997; 113: 118-26.
26. Niessner M, Volk BA. Altered Th1/Th2 cytokine profiles in the intestinal mucosa of patients with inflammatory bowel disease as assessed by quantitative reversed transcribed polymerase chain reaction (RT-PCR). *Clin Exp Immunol* 1995; 100: 428-35.
27. Thepen T, Langeveld-Wildschut EG, Bihari IC, et al. Biphasic response against aeroallergen in atopic dermatitis showing a switch from an initial Th2 response to a Th1 response. *J Allergy Clin Immunol* 1996; 97: 828-37.
28. Iijima H, Takahashi I, Kishi D, et al. Alteration of interleukin 4 production results in the inhibition of T helper type 2 cell-dominated inflammatory bowel disease in T cell receptor alpha chain-deficient mice. *J Exp Med* 1999; 190: 607-15.
29. Boirivant M, Fuss I, Chu A, Strober W. Oxazolone colitis: a murine model of T helper type 2 colitis treatable with antibodies to interleukin-4. *J Exp Med* 1998; 16: 1929-39.
30. Bischoff SC, Mayer JH, Manns M. Allergy and the gut. *Int Arch Allergy Immunol* 2000; 121: 270-83.
31. Heatley RV, James PD. Eosinophils in the rectal mucosa. A simple method of predicting the outcome of ulcerative proctocolitis. *Gut* 1978; 20: 787-91.
32. Jones NL, Roifman CM, Griffiths AM, Sherman P. Ketotifen therapy for acute ulcerative colitis in children: a pilot study. *Dig Dis Sci* 1998; 43: 609-15.